

and can be outlined with CEA and EMA immunohistochemical markers [4]. Further, most metastatic adenocarcinomas are positive for CEA and EMA stains. However, CEA is negative in most EPCs but can be positive in tumors containing well-formed ducts [2]. To achieve a definitive diagnosis, a well-handled specimen and expert pathology and oncology departments are required.

Histological findings that predict the worse prognosis are lymphovascular invasion, a mitotic index of more than 14 mitotic cells for every high power field, and a tumoral depth of more than 7 mm [2,4,5].

There is no standard therapeutic protocol for EPC. However, because of its high rate of local recurrence, wide excision with histologically clear margins is the treatment of choice. Appropriate surgical resection achieves curative outcomes in 70% to 80% of the cases, and there is 20% local recurrence and 20% distant metastasis [5]. Because of the high recurrence rate, close follow-up and a search for metastasis should be performed, and sometimes, adjuvant therapy could be performed. However, anecdotal reports show some benefits when utilizing radiation or chemotherapy [3].

EPC is curable if an accurate diagnosis is performed early and appropriate treatment is provided. EPC can be easily misdiagnosed because of a lack of particular characteristics; therefore, a careful approach is necessary. Because of its aggressive potential for metastasis and poor prognosis, a complete early definitive pathologic diagnosis of EPC should be performed along with regional lymph-node involvement assessment, such as a physical examination, and radiological tests. PET-CT can easily indicate whether metastasis is present. Thus, prior to any operation, a PET-CT scan should be performed, as it can assist in determining whether selective adjacent lymph node resection is required.

References

1. Bhat W, Akhtar S, Khotwal A, et al. Primary eccrine porocarcinoma of the finger with transit forearm and axillary metastasis. *Ann Plast Surg* 2011;66:344-6.
2. Choi CM, Cho HR, Lew BL, et al. Eccrine porocarcinoma presenting with unusual clinical manifestations: a case report and review of the literature. *Ann Dermatol* 2011;23 Suppl 1:S79-83.
3. Jain R, Prabhakaran VC, Huilgol SC, et al. Eccrine porocarcinoma of the upper eyelid. *Ophthal Plast Reconstr Surg* 2008;24:221-3.
4. Luz Mde A, Ogata DC, Montenegro MF, et al. Eccrine

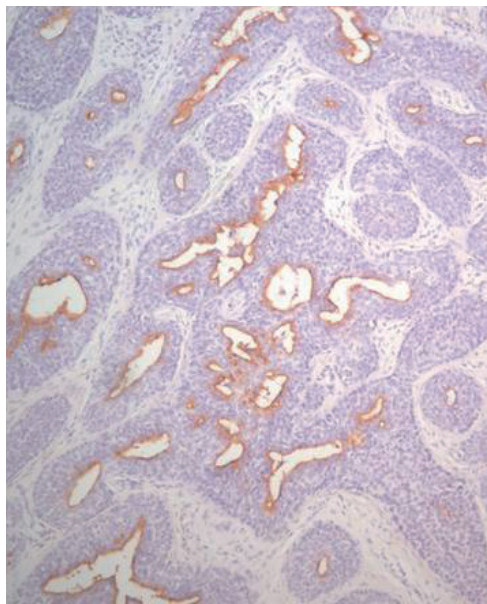


Fig. 5. An immunoperoxidase stain is positive for epithelial membrane antigen, suggesting eccrine differentiation.

porocarcinoma (malignant eccrine poroma): a series of eight challenging cases. *Clinics (Sao Paulo)* 2010;65:739-42.

5. Marone U, Caraco C, Anniciello AM, et al. Metastatic eccrine porocarcinoma: report of a case and review of the literature. *World J Surg Oncol* 2011;9:32.

Mandibular Fracture Masking Hyoid Bone Fracture

Moon Kyun Cho¹, Je Min An¹, Chul Han Kim², Sang Gue Kang²

Departments of ¹Dermatology and ²Plastic and Reconstructive Surgery, Soonchunhyang University College of Medicine, Seoul, Korea

Correspondence: Chul Han Kim
Department of Plastic and Reconstructive Surgery, Soonchunhyang University College of Medicine, 59 Daesagwan-ro, Yongsan-gu, Seoul 140-743, Korea
Tel: +82-2-709-9283, Fax: +82-2-796-3543, E-mail: kchann@hanmail.net

This work was supported by the Soonchunhyang University Research Fund.

No potential conflict of interest relevant to this article was reported.

Received: 29 Jun 2013 • Revised: 16 Aug 2013 • Accepted: 17 Aug 2013
pISSN: 2234-6163 • eISSN: 2234-6171
<http://dx.doi.org/10.5999/aps.2014.41.1.93> • Arch Plast Surg 2014;41:93-95

Copyright © 2014 The Korean Society of Plastic and Reconstructive Surgeons
This is an Open Access article distributed under the terms of the Creative Commons Attribution Non-Commercial License (<http://creativecommons.org/licenses/by-nc/3.0/>) which permits unrestricted non-commercial use, distribution, and reproduction in any medium, provided the original work is properly cited.

Fractures of the hyoid bone are commonly caused by strangulation or hanging [1]. However, fractures of

the hyoid bone resulting from trauma other than strangulation or hanging are rare [1]. A hyoid bone fracture is occasionally associated with clinically significant complications including airway obstruction [2,3]. Although many facial injuries are caused by trauma, a fracture of the hyoid bone complicating a facial fracture is rare [4]. Herein, we report a hyoid bone fracture.

A 32-year-old man presented to our emergency

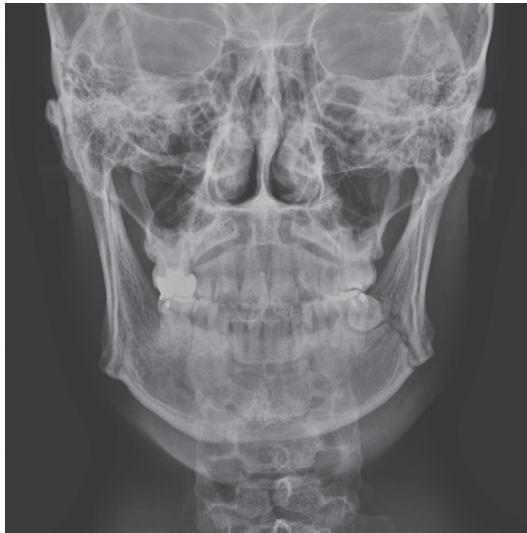

Fig. 1.
A postero-anterior view of mandible revealed a left angle fracture.

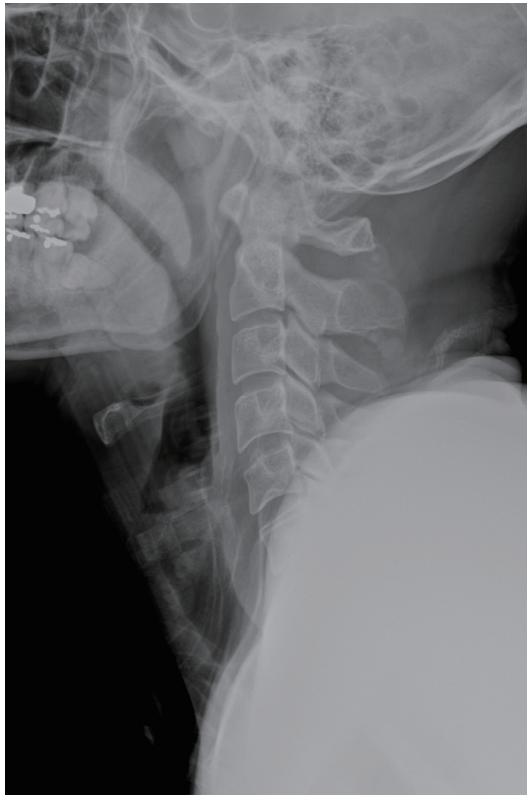

Fig. 2.
Routine lateral radiography showed no definite fracture line.

room complaining of painful swelling in the left mandible area after a car accident. He was in an alert mental state. Physical examination revealed severe tenderness over the left mandible angle region. Occlusal disturbance was noted. Plain radiography demonstrated a left angle fracture of the mandible (Fig. 1). An X-ray of the neck did not show a definite fracture (Fig. 2). The mandibular fracture was treated by open reduction and internal fixation with a plate (Fig. 3). Two days after the operation for the mandibular fracture, he complained of dyspnea that suddenly developed. Physical examination revealed crepitus and pain in the anterior neck upon turning the face. Pharyngolaryngeal edema was identified. The patient was transferred to the intensive care unit. After 5 days of close observation, his symptoms subsided. He underwent a computed tomography (CT) scan of the neck to rule out the presence of damage to airway structures. CT demonstrated a slightly displaced fracture of the hyoid bone between the left greater horn and the body (Fig. 4). There was no perforation in the larynx or pharynx, and the cervical spines and other airway structures were normal. Direct laryngoscopy was normal. He was diagnosed with a fracture of the hyoid bone. Management was conservatively. Fortunately, his symptoms disappeared after 2 weeks.

Facial trauma is commonly encountered in the department of plastic surgery. However, hyoid bone fractures secondary to trauma other than strangulation or hanging are rare, because the hyoid bone is well protected by the mandible and the cervical spine [1]. The hyoid bone is not directly articulated to other bones, and the stylohyoid ligament suspends the hyoid bone to the tips of the styloid process [1]. The hyoid bone also provides the attachment site of the pharynx to maintain the patency of the pharynx during swallowing and respiration. Therefore, a fracture of the hyoid bone can result in a compromised airway [3]. Papavasiliou and Speas [2] reported that upper airway obstruction was associated with a hyoid bone fracture. Krekorian [3] reported that fragments of a fractured hyoid bone resulted in the perforation of the pharynx. As the hyoid bone was related to the surrounding structures, hyoid bone fractures have been reported with associated injuries including cervical spine injuries, damage to the larynx or pharynx, and facial fractures [2-4]. These associated injuries tend to need more urgent management and, as a result, a fracture of the hyoid bone may not be recognized immediately. In our patient, the hyoid

bone fracture was masked by the mandibular fracture. The symptoms of a hyoid bone fracture can clinically vary, including worsening of neck pain by coughing or swallowing, crepitus, dyspnea, and hemoptysis [1]. Diagnosis of a hyoid bone fracture is difficult and is usually performed upon a clinically strong suspicion of a surgeon [5]. In general, a hyoid bone fracture is clearly visible in plain radiographs of the cervical spine [5]. However, in our case, an X-ray did not reveal a definite fracture line. Later, a CT scan showed an interruption of the cortex in the diagnosis of hyoid bone fracture. Similarly, the diagnosis of a hyoid bone fracture may be overlooked, particularly in the presence of a more striking and serious injury such as the mandibular fracture seen in our case. Although the dyspnea symptom of our patient was fortunately resolved, a hyoid bone fracture should be observed for 48 to 72 hour because hyoid bone fractures may lead to the development of significant problems including respiratory distress [1-5]. In the case of airway obstruction, tracheostomy or endotracheal intubation must be performed [4]. A mandibular fracture produces swelling on the soft tissue of the neck, which may mask an associated hyoid fracture. Although a traumatic fracture of the hyoid bone is rare, considerably more attention should be paid to a patient with facial trauma and a close follow-up is necessary because a hyoid bone fracture is difficult to diagnose and can be easily overlooked in the initial evaluation of trauma, leading to potentially life-threatening circumstances. Therefore, the surgeon must be aware of the possibility of an underlying hyoid bone fracture in patients of facial trauma.

References

1. Bagnoli ML, Leban SG, Williams FA. Isolated fracture of the hyoid bone: report of a case. *J Oral Maxillofac Surg* 1988;46:326-8.
2. Papavasiliou CG, Speas CJ. Fracture of the hyoid bone. *Radiology* 1959;72:872-4.
3. Krekorian EA. Perforation of the pharynx with fracture of the hyoid bone. *Ann Otol Rhinol Laryngol* 1964;73: 583-94.
4. Whyte AM. Fracture of the hyoid bone associated with a mandibular fracture. *J Oral Maxillofac Surg* 1985;43: 805-7.
5. Ramchand T, Choudhry OJ, Shukla PA, et al. Management of hyoid bone fractures: a systematic review. *Otolaryngol Head Neck Surg* 2012;147:204-8.

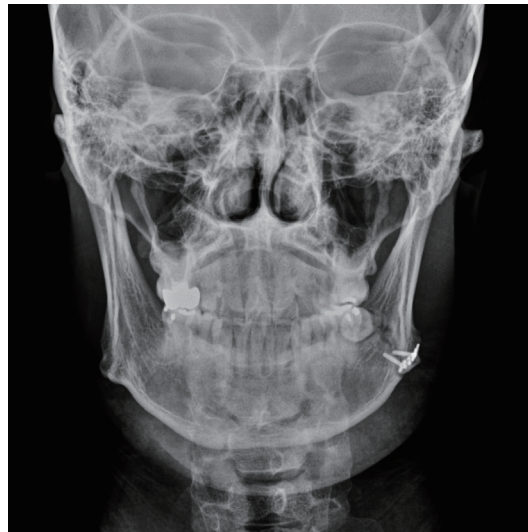

Fig. 3. A postoperative view of a mandibular fracture.

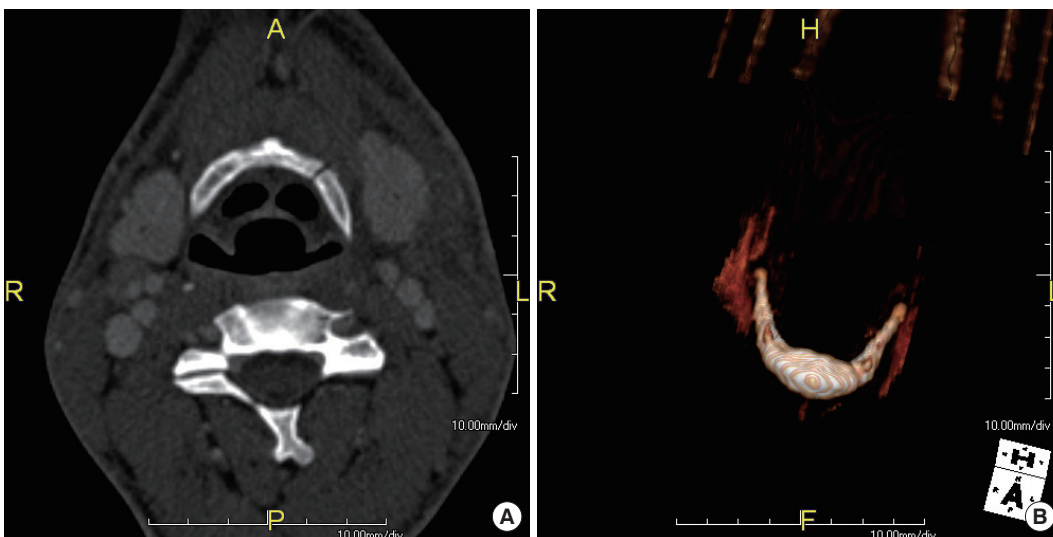


Fig. 4. (A) A cervical computed tomography (CT) scan showed a slightly displaced fracture of the hyoid bone between the left greater horn and the body. (B) A three dimensional CT scan of the hyoid bone.