

The degree of deformity depends on the promptness and efficacy of treatment. Deformities will vary from small contour irregularities in the helical rim to complete absence of the ear. Reconstruction should not be attempted for a minimum of 6 months after complete resolution of the infection [4,5]. Reconstruction is individualized for the deformity and may consist of simple scar revision, cartilage sculpting, or complete reconstruction of the ear with cartilage grafts and flaps. Most commonly, a local skin envelope can be salvaged and can be unfurled and wrapped over shaped cartilage grafts taken from the opposite ear. Reconstructive complexity may escalate if initial reconstructions are inadequate.

The consequences of ear cartilage piercing include infection and potential loss of the ear. As such, patients should be counseled about these risks when considering the procedure.

References

1. Chowdhury WA, Hossain MM, Chowdhury MR, et al. High ear piercing: a dangerous craze. *Mymensingh Med J* 2004;13:201-2.
2. Armstrong ML, Roberts AE, Owen DC, et al. Contemporary college students and body piercing. *J Adolesc Health* 2004;35:58-61.
3. Simplot TC, Hoffman HT. Comparison between cartilage and soft tissue ear piercing complications. *Am J Otolaryngol* 1998;19:305-10.
4. van Wijk MP, Kummer JA, Kon M. Ear piercing techniques and their effect on cartilage, a histologic study. *J Plast Reconstr Aesthet Surg* 2008;61 Suppl 1:S104-9.
5. Cicchetti S, Skillman J, Gault DT. Piercing the upper ear: a simple infection, a difficult reconstruction. *Br J Plast Surg* 2002;55:194-7.

Axillary Fistula and Scar Contracture due to Uncontrolled Chronic Infection after Trans-Axillary Augmentation Mammoplasty

Kyung Han Yu, Soo A Lim, Jin Kyung Song, Yong Il Yoon

Department of Plastic and Reconstructive Surgery, KEPCO Medical Center, Seoul, Korea

Correspondence: Soo A Lim
Department of Plastic and Reconstructive Surgery, KEPCO Medical Center, 308 Uicheon-ro, Dobong-gu, Seoul 132-703, Korea
Tel: +82-2-901-3109, Fax: +82-2-901-3104
E-mail: zzcrunch@naver.com

This article was presented as a poster at the 3rd Research and Reconstructive Forum on May 9-10, 2013, in Daegu, Korea.

No potential conflict of interest relevant to this article was reported.

Received: 23 Apr 2014 • Revised: 16 May 2014 • Accepted: 3 Jun 2014
pISSN: 2234-6163 • eISSN: 2234-6171
<http://dx.doi.org/10.5999/aps.2014.41.5.612> • Arch Plast Surg 2014;41:612-615
Copyright © 2014 The Korean Society of Plastic and Reconstructive Surgeons
This is an Open Access article distributed under the terms of the Creative Commons Attribution Non-Commercial License (<http://creativecommons.org/licenses/by-nc/3.0/>) which permits unrestricted non-commercial use, distribution, and reproduction in any medium, provided the original work is properly cited.

Infection after augmentation mammoplasty should not be underestimated. Because if not appropriately treated, it may lead to serious issues such as scarring, wound dehiscence, reinfection and after all, implant loss [1,2]. Generally, even if in severe infection, the course tends to improve with implant removal, antibiotic treatment and other additional surgical procedures like debridement, drainage [2]. But with above treatments it may lead serious secondary complications [2] and we experienced about axillary fistula and scar contracture with limitation of motion

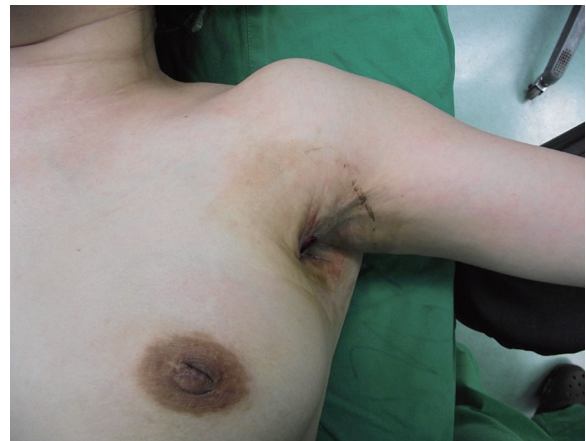

Fig. 1. Limitation of motion of left shoulder due to scar contractures is shown. Checked active range of motion is about 70 degrees.

due to uncontrolled chronic infection after implant removal.

A 40-year-old woman was hospitalized for soft tissue defect and limited of motion at left axilla. One year before hospitalization, she underwent trans-axillary augmentation mammoplasty at subpectoral plane. Six months after operation, she got bilateral implants removal through approach site, antibiotic treatment due to infection of left breast, not because of implant rupture. And at that time, there were no signs of axillary infection like folliculitis. After implant removal, she got povidone-iodine wet dressing at axilla. After then, there were improvements of other infection signs. However, exudates at approach site appeared and it did not regress and wound dehiscence occurred. Furthermore wound size was not decreased, and consequently, it remained skin and soft tissue defect.

On admission day, we performed physical exams and clinical evaluations. The defect measuring 4×3 cm² extended fistula of breast in the 7 o'clock region. Scar tissues and contracture band were found around the defect wound (Fig. 1). The active range of motion of abduction was with 70 degrees (Fig. 1) and passive range of motion was with 110 degrees limited due to contracture band.

In hematologic exam, it was notable that erythrocyte sedimentation rate (ESR) was significantly elevated while leukocyte and C-reactive protein (CRP) were within normal ranges. We carried out microbiologic exam of pre-operative wound as well as of intra-operative wound, and *Methicillin resistant Staphylococcus epidermidis* was identified.

Also, acid fast bacillus (AFB) stain and Tuberculosis - Polymerase chain reaction (Tb-PCR) examination were performed to rule out mycobacterium infection, and the results were negative. Initially we used second generation cephalosporin as empirical antibiotic and according to the result, we used Vancomycin.

In operation, we checked the state of fistula. The defect was continued to near end of breast parenchyma making a fistula with diagonal direction and the length was 18 cm (Fig. 2).

Gentine-violet was applied through the fistula (Fig. 3), and, we performed a debridement by endoscopic guidance. And then, meticulous hemostasis and massive irrigation were carried out. To improve limitation of motion, excision of contracture band and a release procedure were performed. The defect was reconstructed by rotation flap considering the tension of flap with use of lateral aspect of left breast. After then, a drainage tube was placed at the inframammary fold (Fig. 4).

Postoperative wound was clean, and the drain tube was removed 6 days after operation.

The stitches were removed 9 days after operation and there was no complication. The range of motion of abduction was improved from 70 to 170 degrees. Three weeks after operation, breast ultrasonography was performed to check fluid collection or fistula, and, there was no sign of them. Six months after operation, range of motion was improved to 180 degrees and scar was improved and the patient was satisfied with the result (Fig. 5).

Infection after augmentation mammoplasty has varying degrees of intensity from mild cellulitis or

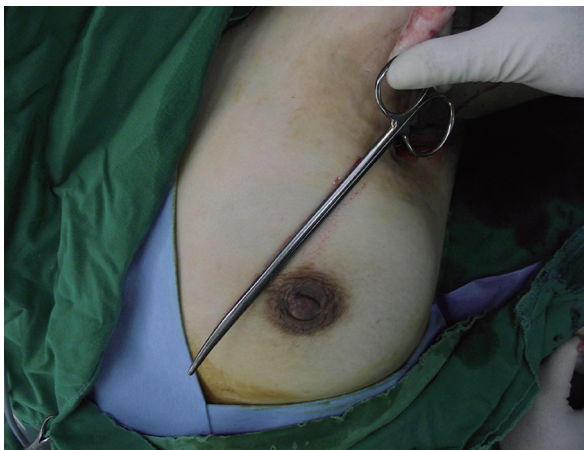


Fig. 2.

After passive abduction of shoulder, state of defect was checked and it continued the fistula, and the length of fistula was 18 cm.

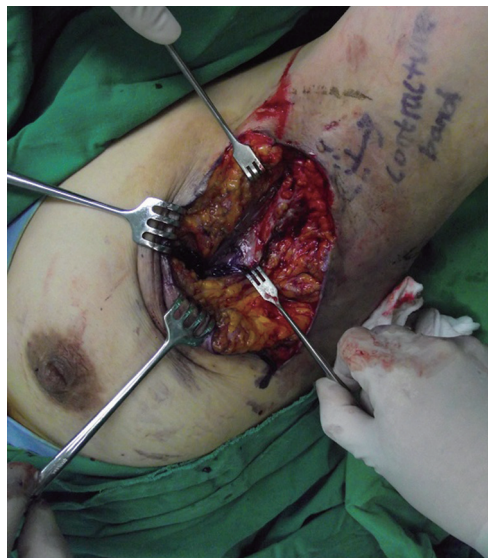

Fig. 3.

Inflammatory tissue stained with Gentian-violet is shown in fistula.

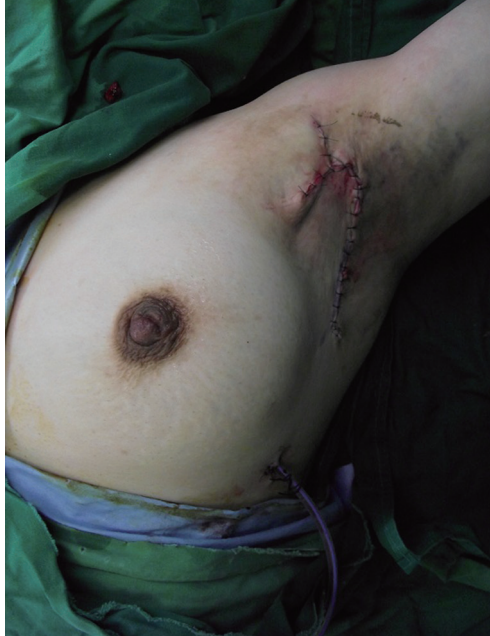

Fig. 4. Release procedure and rotation flap are performed and drainage tube is placed at inframammary fold.

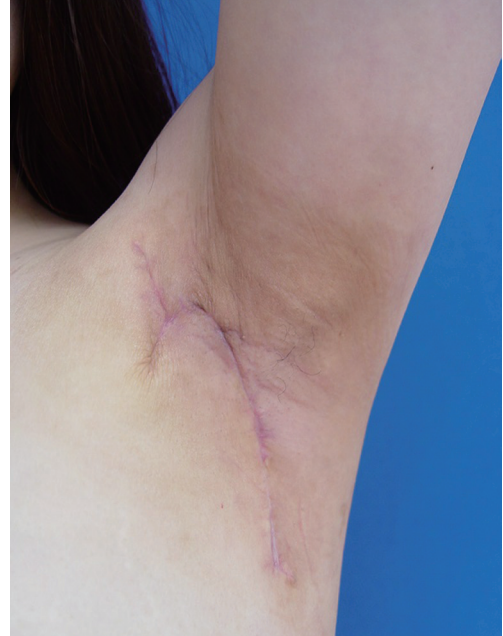

Fig. 5. After 6 months of operation, range of motion of axilla is improved and there is no complication.

periprosthetic infection to severe infection with pus and systemic symptoms like fever [1], and as presented case, it may lead secondary complications. Important determinants of infection are mainly related with underlying conditions of patient and surgical techniques.

They include patient's history about diabetes or smoking, states of skin or mammary duct, surgeon's aseptic procedures, meticulous hemostasis for prevention of hematoma or seroma, and so on [3]. And these factors influence occurrence of infection by endogenous flora. Most frequently identified pathogen in postoperative infection is *Staphylococcus epidermidis*, which is normal skin flora [2,3]. And if bacteria colonize around implant, they produce biofilm.

The biofilm causes an inflammation of the host which can lead periprosthetic infection, implant failure, early treatment failure, chronic infection and capsular contracture [2].

As presented case, in uncontrolled chronic periprosthetic infection which is related with biofilm, microbiologic exam of the extracted wound tissues is necessary through operation because bacteria may not be identified by a microbiologic culture of the drained secretion [2].

Also, infections by mycobacterium after augmentation mammoplasty has been increased in recent years and it is related uncontrolled chronic infection, therefore, AFB stain and Tb-PCR tests are necessary, too [3,4].

The typical treatment for infection after augmentation mammoplasty is based on early systemic antibiotic treatment and additional surgical treatment according to the degree of infection [1-3]. Especially in severe periprosthetic infection, the cause is infected implant and it may remain serious secondary complications. So, sacrifice such as implant removal is essential in treatment of severe periprosthetic infection [1,3]. And in procedure of implant removal, generally both implants are removed, because adequate symmetry of breast contour is significant for satisfaction of patients [5]. In uncontrolled chronic infection, implant removal is important and surgical debridement is necessary too [2].

In the presented case, since the infection did not improve during 6 months after implant removal and antibiotic treatment, there was a high likelihood that it was chronic infection rather than acute infection. Also significant elevation of ESR implied that it was chronic infection. The possible causes of chronic infection could be antibiotic resistant bacteria, biofilm and remained infected tissue. So, the implants were removed, nevertheless, the uncontrolled infection still existed, and it led to chronic infection. And we resolved the problems about chronic infection, limitation of motion, and defect with elimination of infectious debris around fistula, appropriate antibiotic, release of scar contracture and rotation flap to cover

defect area.

As a result of journal reviews about infection after augmentation mammoplasty, there are some reports about secondary complications of infection and they imply that it is hard to be resolved. In conclusion, it is important to control severe or chronic infection after augmentation mammoplasty with active surgical procedures based on appropriate antibiotic treatment, and we report this rare case.

References

1. Spear SL, Seruya M. Management of the infected or exposed breast prosthesis: a single surgeon's 15-year experience with 69 patients. *Plast Reconstr Surg* 2010; 125:1074-84.
2. Jung SI, You YC, Yang WY, et al. Experience of recurrent periprosthetic infection after augmentation mammoplasty. *J Korean Soc Plast Reconstr Surg* 2004; 31:723-8.
3. Washer LL, Gutowski K. Breast implant infections. *Infect Dis Clin North Am* 2012;26:111-25.
4. Jackowe DJ, Murariu D, Parsa NN, et al. Chronic fistulas after breast augmentation secondary to *Mycobacterium abscessus*. *Plast Reconstr Surg* 2010;126:38e-9e.
5. Khavanin N, Gust MJ, Grant DW, et al. Tabbed tissue expanders improve breast symmetry scores in breast reconstruction. *Arch Plast Surg* 2014;41:57-62.