

A Rabbit Model of Fat Graft Recipient Site Preconditioning Using External Negative Pressure

Jung Woo Lee¹, Yea Sik Han¹, Sin Rak Kim¹, Han Kyeol Kim¹, Hyun Kim², Jin Hyung Park¹

Departments of ¹Plastic and Reconstructive Surgery and ²Anatomy, Kosin University College of Medicine, Busan, Korea

Original Article

Background Fat is widely used in soft tissue augmentation. Nevertheless, it has an unpredictably high resorption rate. Clinically, external expansion with negative pressure is used to increase fat graft survival. In this study, fat graft recipient sites were preconditioned by external application of negative pressure in order to test for improvements in vascularity and fat graft survival.

Methods Negative pressure was applied randomly to either the left or right dorsal ear of 20 New Zealand male white rabbits at a pressure of -125 mm Hg. The negative pressure was removed one week after the skin perfusion was measured. The skin flap at each ear was elevated, and 1 g of fat was grafted above the dorsal perichondrium. After one week, the fat weight, microvessel density, mature vessel density of the skin and fat, and amount of glycerol released were measured. Three months after the grafting, the same measurements were performed, with the exception of glycerol release.

Results The fat survival rate of the experimental group (75.4% ± 3.9%) was higher than that of the control group (53.1% ± 4.3%) (P < 0.001). Skin perfusion was higher in the experimental group. The glycerol release in the experimental group was significantly higher than in the control. The microvessel density of the skin and fat was significantly higher in the experimental group. Three months after the grafting, the skin and fat mature vessel density was significantly higher in the experimental groups.

Conclusions Negative pressure prior to fat grafting increased the vascularity of the recipient site, and, accordingly, enhanced fat graft survival.

Keywords Transplant donor site / Topical negative-pressure therapy / Adipose tissue / Autografts

Correspondence: Jin Hyung Park
Department of Plastic and Reconstructive Surgery, Kosin University College of Medicine, 262 Gamcheon-ro, Seo-gu, Busan 602-702, Korea
Tel: +82-51-990-6131
Fax: +82-51-990-3005
E-mail: atreyue@naver.com

This article was presented at the 4th Research and Reconstructive Forum on April 3-4, 2014 in Busan, Korea.

No potential conflict of interest relevant to this article was reported.

Received: 6 Aug 2014 • Revised: 25 Sep 2014 • Accepted: 30 Sep 2014
pISSN: 2234-6163 • eISSN: 2234-6171 • <http://dx.doi.org/10.5999/aps.2015.42.2.150> • Arch Plast Surg 2015;42:150-158

INTRODUCTION

Fat grafting has been widely used in various fields, including soft tissue augmentation [1]. However, its resorption rate is unpredictable and varies from 20% to up to 90%. Fat graft survival depends on the fat harvesting method, processing, transplanting, and recipient site condition. Many researchers have reported the significant effect of early revascularization on fat graft sur-

vival due to the low tolerance of ischemia in adipose tissues [2]. Sufficient vascularization and blood flow at the recipient bed enable early revascularization of the transplanted tissues, thereby increasing the survival rate [3]. Negative pressure wound therapy (NPWT) is a non-invasive wound-closure device. It was invented to help with wound healing at a chronic or acute wound site by using locally controlled negative pressure [4,5]. NPWT is currently widely used for transient closure of complex

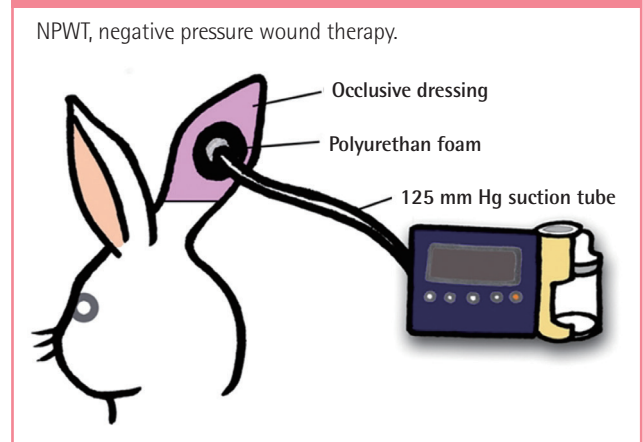
wounds and to prepare wound beds for a skin graft or flap surgery because of its efficacy in increasing tissue perfusion and vascularity *via* facilitation of angiogenesis [6]. Application of negative pressure over intact skin has been found to increase vascularity and fat graft survival. An example of the clinical implementation of negative pressure in relation to fat grafting is the Brava breast enhancement and shaping system, where the fat graft survival rate is improved by pre-expansion and increased vascularity *via* the application of negative pressure to the breast upon fat grafting [7]. Many subsequent studies have described the pre-expansion of the recipient site and resulting graft-to-recipient interface increase in megavolume fat grafting greater than 200-mL [8]. In a study by Khouri et al. [7], increased breast parenchymal vascularity was confirmed by magnetic resonance imaging. Heit et al. [9] had research of external volume expansion with murine model which confirmed increase of subcutaneous blood vessel density by external application of negative pressure. Gigliofiorito et al. [10] had reviewed the study by Heit et al. [9] and emphasized importance of neoangiogenesis and further *in vivo* study of permanency of microvascular change. While the study by Heit et al. has shown that the external application of negative pressure over intact skin results in increased connective tissue volume and vascularity, no further direct relationship has been evaluated between this increased vascularity and fat graft survival. Thus, we have designed a rabbit model of recipient site preconditioning and evaluate the relationship between vascularity and fat graft survival.

METHODS

Animal model

The study protocol was reviewed and pre-approved by the Institutional Animal Care and Use Committee of Kosin University Medical Center. Twenty male New Zealand white rabbits (2,500–3,000 g in weight) were obtained for the experiment. One randomly selected ear served as the experimental site for negative pressure preconditioning, while the contralateral ear of the same rabbit served as the control. After shaving entire ear, a 3-cm-diameter round black polyurethane foam was placed over the intact skin of dorsal surface, and the foam was sealed with impermeable tape used for NPWT (CuraVAC, CG Bio, Hwasung, Korea) (Fig. 1). The entire ear was wrapped with cohesive elastic bandage (Peha-haft, Hartmann, Tock Hill, SC, USA) to retain the dressing. For the experimental group of ears, 125 mm Hg of continuous suction was applied. The NPWT tube was allowed to communicate with the atmosphere for the control group. The external negative pressure appliances did not hinder ambulation. Standard laboratory feed and water were provided

Fig. 1. NPWT device on the dorsal ear of a rabbit



ad lib. The external negative pressure was applied for one week and then removed from the rabbits. Tissue perfusion was compared between the 20 control and experimental sites. Fat grafting was performed in all rabbits. At two weeks after grafting, ten rabbits were sacrificed and used to evaluate macroscopic evaluation, lipolysis assay and microvessel density and the mature vessel density of the grafted fat and dorsal ear skin. At three months after grafting, the remaining ten rabbits were sacrificed and used to evaluate same measurements except for lipolysis assay.

Perfusion measurement

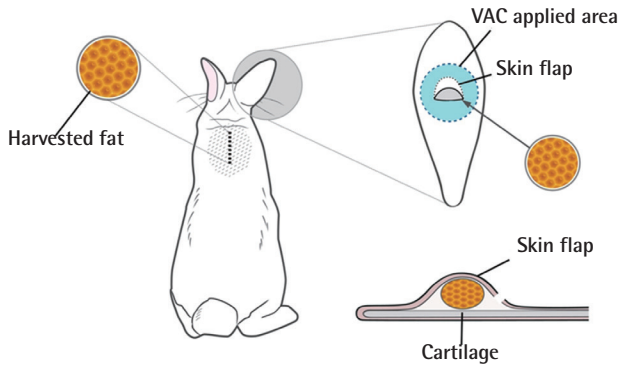
At one week, tissue perfusion was evaluated using a laser Doppler flowmetry (OMEGAFLOW, Omegawave Inc., Tokyo, Japan). For each site, nine random spots were evaluated, and the mean value was used to compare between experimental and control sites.

Fat graft

After the perfusion evaluation, all of the rabbits were anesthetized *via* intramuscular injection of 15 mg/kg of Zoletile (125 mg Tilemine and 125 mg Zolazepam; Vibracrabbit, NH, USA). Upon shaving and sterilization, a 3-cm vertical incision was made between the scapula, and dissections were carried laterally to adequately expose both the right and left scapular adipose sacs. Two fat grafts each weighing 1 g were harvested and wrapped with gauze soaked in a normal saline solution. After a transverse 1.5-cm incision was made on lower margin of preconditioned area of dorsal ears, a pocket was made superiorly, between the skin and the perichondrium *via* blunt dissection with scissors. The dissection did not extend beyond the preconditioned area. Incision and blunt dissection were performed at the same site in the control group. The harvested fat was placed on the perichondrium, and the skin was closed in a single layer with 6-0 nylon. Simple dressing was changed daily (Fig. 2).

Fig. 2. Fat grafting procedures

Fat was harvested from the subscapular adipose sac for grafting on the dorsal ear at the site of negative pressure was applied. The fat was grafted above the dorsal perichondrium. VAC, vacuum-assisted closure.



Survival rate of the fat graft

Weight of grafted fat was examined for animals at sacrificed both time intervals. A 2-cm incision was made under Loupe magnification ($2.5\times$), and the grafted fat was carefully dissected from the nearby tissues in order to measure its weight. The fat graft survival percentage was expressed as the weight/weight ratio of the initial weight to the final weight, as follows: fat graft survival (%) = [final weight (g)/initial weight (g)] \times 100. After measurement of the weight of grafted fat, 400 mg of fat was used for lipolysis assay and remnant fat was used for immunohistochemistry.

Lipolysis assay

The amount of free glycerol dissociated from the fat graft sample was measured using a free glycerol determination kit and a standard glycerol solution (both from Sigma/Aldrich, St. Louis, MO, USA), and the fat tissue viability was examined for the animals sacrificed at one week after fat grafting. Ten fat tissue specimens were harvested from the study and control groups, respectively. A 400-mg aliquot of the fat tissue specimen was minced and placed on a 24-well cell culture plate. An assay buffer (Dulbecco's modified Eagle medium/F-12 medium; CellGro, Herndon, VA, USA) and 4% bovine serum albumin (Sigma/Aldrich) were added to the cell culture plate, and 1 μ M of isoproterenol hydrochloride (Sigma) was added to the plate for agonistic induction, after which the plate was incubated at 37°C for 3.5 hours. After the supernatant obtained from the 24-well cell culture plate was transferred to a 96-well cell culture plate, a free glycerol reagent (Sigma/Aldrich) was added to the plate, which was then incubated at 37°C for 5 minutes. The lipolysis of the specimen was determined using spectrophotometry (540 nm). The viable fat and non-viable fat (heated to 95°C for 20 minutes) were mixed at various ratios, and a standard curve was

drawn for fat tissue viability to determine if the glycerol release was linearly related to the amount of the viable fat tissue.

Immunohistochemistry

The 1 \times 1-cm central skin of the negative pressure applied area was harvested and preserved with the harvested grafted fat tissue in 10% formalin.

For the measurement of mature and microvessel density, the specimens were carefully dissected and then fixed overnight in 4% paraformaldehyde with a 0.1 M phosphate buffer solution (pH 7.4). The specimens were then embedded in paraffin and sliced into 5- μ m-thick serial sections using a Microtome (Leica Microsystems Inc., Buffalo Grove, IL, USA). The specimen sections were deparaffinized and fixed after hydration. They were blocked in 10% normal goat serum (Vector Laboratories, Burlingame, CA, USA), 0.1% Triton X-100, and 3% bovine serum albumin in phosphate-buffered saline. To measure microvessel density, specimen sections were incubated with the primary antibody, Rabbit anti-CD31 polyclonal antibody (1:20; Abcam, Cambridge, UK) at 4°C overnight. Goat anti-rabbit Alexa Fluor594 (1:200; Invitrogen, Carlsbad, CA, USA) was used as the secondary antibody. To measure mature vessel density, specimen sections were incubated with the primary antibody, Mouse anti-human actin-smooth muscle monoclonal antibody (1:200; Spring Bioscience, Fremont, CA, USA) at 4°C overnight. Goat anti-mouse IgG-FITC (1:200; Santacruz Biotechnology, Santa Cruz, CA, USA) was used as the secondary antibody.

The microvessel density was measured using the following standardized two-step protocol. Areas with the highest vessel density were identified in the CD31-stained skin specimen and the fat specimen under low magnification ($100\times$). Three photographs of the identified adjacent areas were taken under high magnification ($200\times$). The microvessel density was measured as the average number of CD31-positive vessels observed in the photographs.

The mature vessel density was measured by counting the number of vascular structures stained with antibodies to smooth muscle actin. The number of positively-stained lumen-containing vessels was measured by randomly observing three fields on each slide at a high-power field ($200\times$).

Statistical analysis

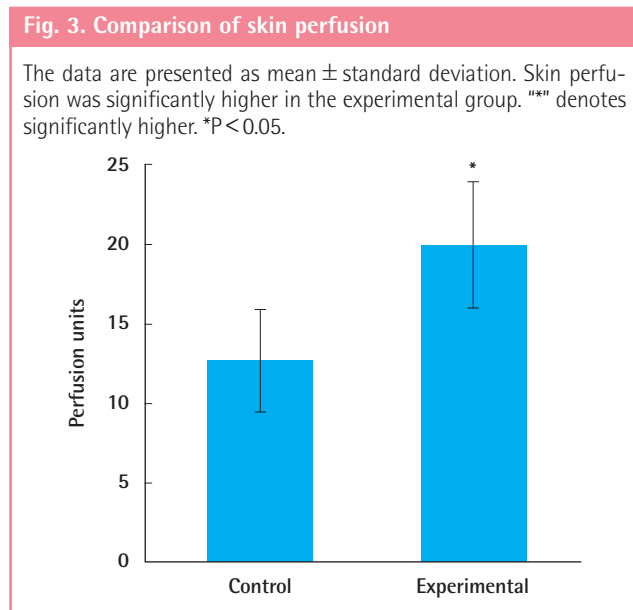
The data were analyzed using SPSS software (SPSS Inc., Chicago, IL, USA). Variables were compared using the Mann-Whitney U test. The results of the study are presented as mean \pm standard deviation. Differences were considered statistically significant at $P < 0.05$.

RESULTS

All of the animals survived to the time of sacrifice. Neither the application of negative pressure nor fat grafting resulted in vascular event such as necrosis of the distal tip of the ear.

Perfusion measurement

The skin blood flow rate was 19.98 ± 3.92 perfusion units in the experimental group, which was significantly increased compared to the 12.71 ± 3.23 perfusion units observed in the control group ($P = 0.002$) (Fig. 3).



Survival rate of the fat graft

One week after fat grafting, the fat graft survival rate was $90.5\% \pm 2.8\%$ in the experimental group and $89.0\% \pm 3.2\%$ in the control group. No significant difference was found between the two groups ($P > 0.05$). Three months after fat grafting, the survival rate was $75.4\% \pm 3.9\%$ and $53.1\% \pm 4.3\%$ in the experimental and control groups, respectively. The fat graft survival rate was significantly higher in the experimental group than in the control group at this time point ($P < 0.001$) (Fig. 4).

Adipose tissue viability

The amount of viable fat tissue was linearly correlated with the glycerol release caused by the adrenergic stimulation (Fig. 5). The glycerol release amounts were $183.56 \pm 55.1 \mu\text{g}/\text{mL}/400 \text{ mg}$ tissue in the experimental group and $100.32 \pm 32.18 \mu\text{g}/\text{mL}/400 \text{ mg}$ tissue in the control group. The glycerol release amount was significantly higher in the experimental group than in the control group ($P = 0.002$), which confirmed that adipose tissue viability was significantly higher in the experimental group than in the control group (Fig. 6).

Immunohistochemistry

The results were shown as Fig. 7. One week after fat grafting, the microvessel density of the skin specimens was significantly higher in the experimental group (17.3 ± 3.2 per high-power field) than in the control group (9.2 ± 2.2 per high-power field) ($P < 0.001$) (Fig. 8), but mature vessel densities of the skin specimens in the experimental group (7.6 ± 2.8 per high-power field) and control group (9.1 ± 2.3 per high-power field) had no

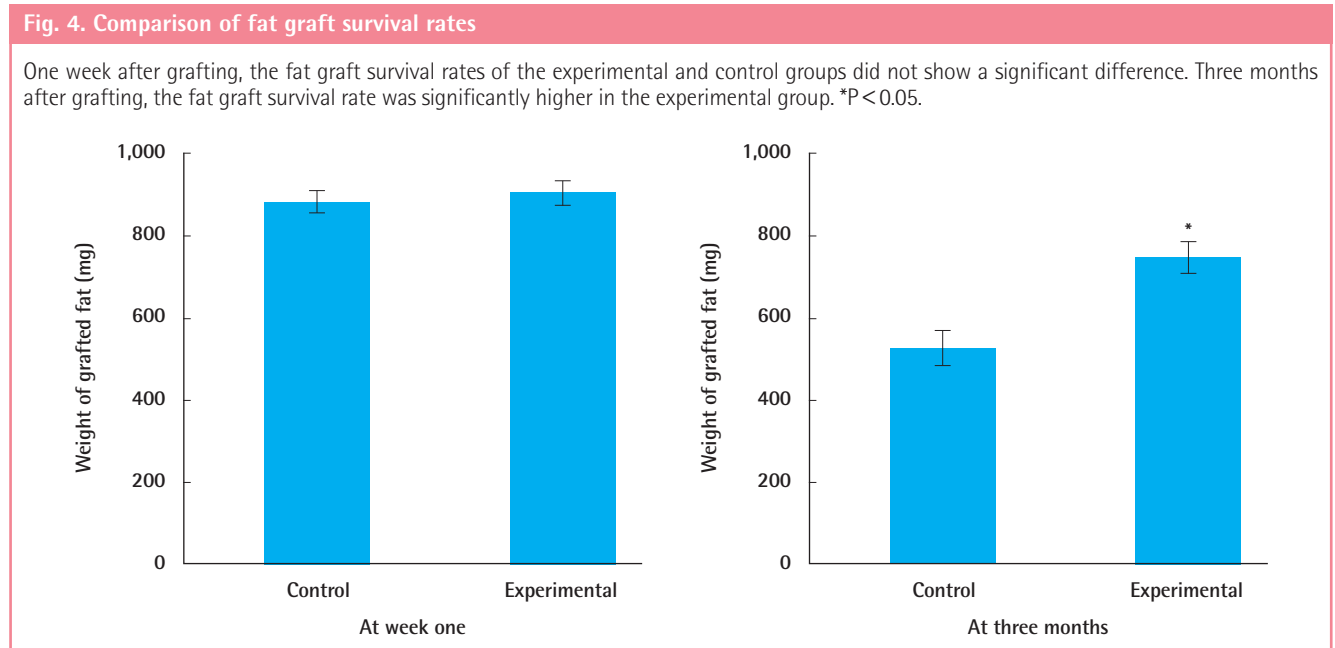


Fig. 5. Fat tissue viability and glycerol release

The fat glycerol release after agonist administration showed a proportional relationship to the amount of viable adipose tissue.

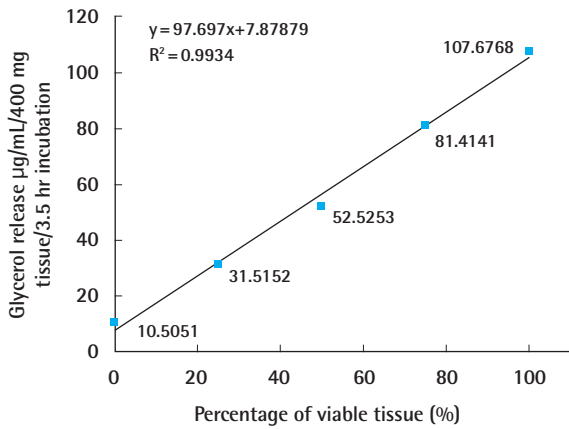


Fig. 6. Comparison of glycerol release

The data are presented as mean \pm standard deviation. The glycerol release was significantly higher in the experimental group. *** denotes significantly higher. * $P < 0.05$.

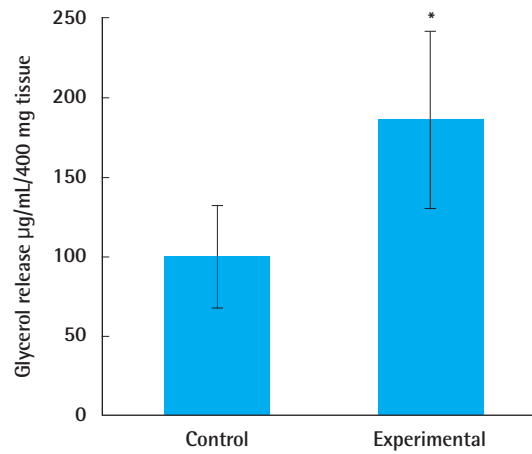


Fig. 7. Comparison of vessel densities

The microvessel density and the mature vessel density one week and three months after grafting were compared in the experimental group and the control group. One week after grafting, the microvessel density of the skin and fat was significantly higher in the experimental group. Three months after grafting, the microvessel density of the skin and the mature vessel density of the skin and fat were significantly higher in the experimental group. * $P < 0.05$.

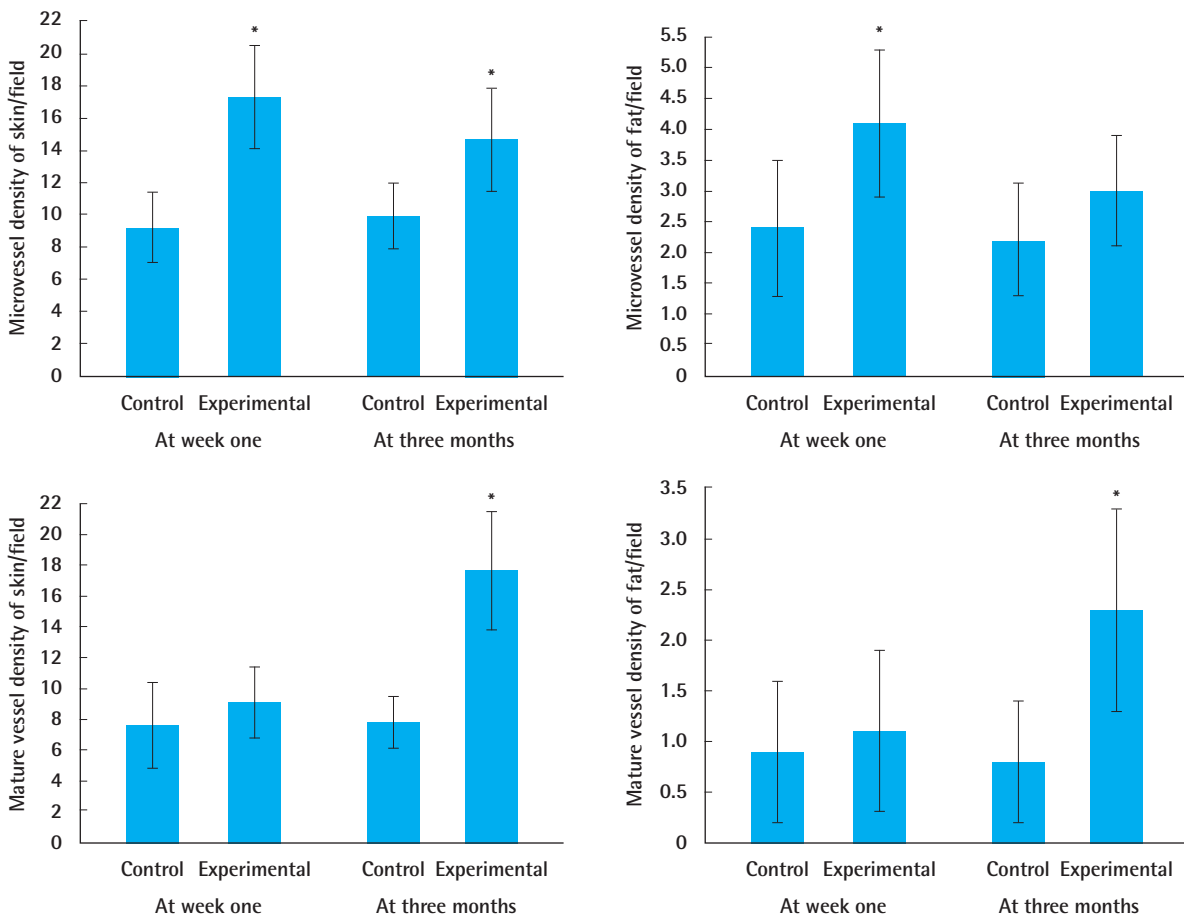
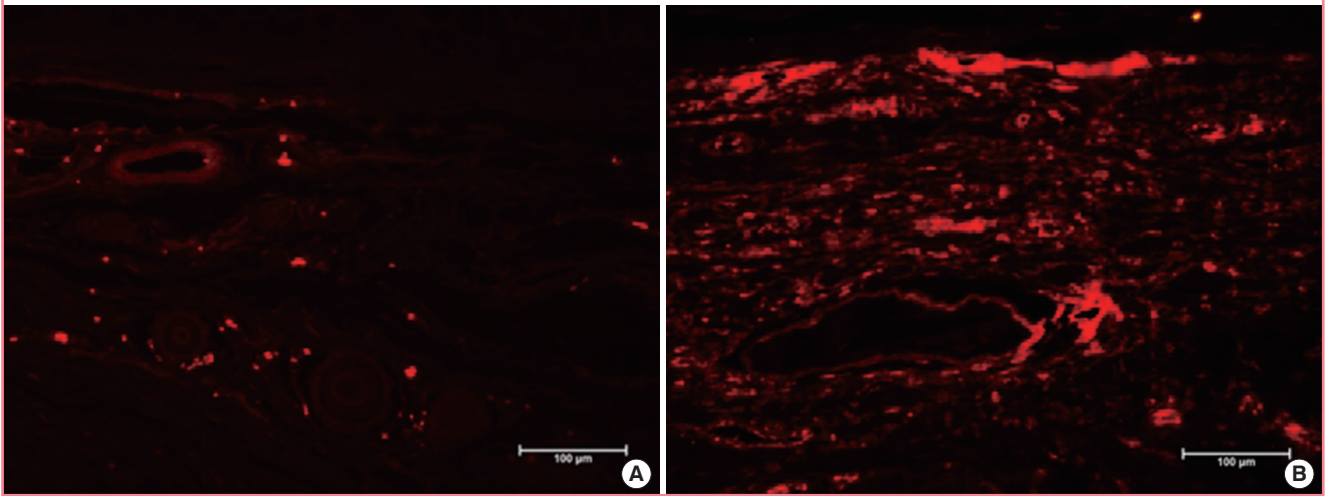
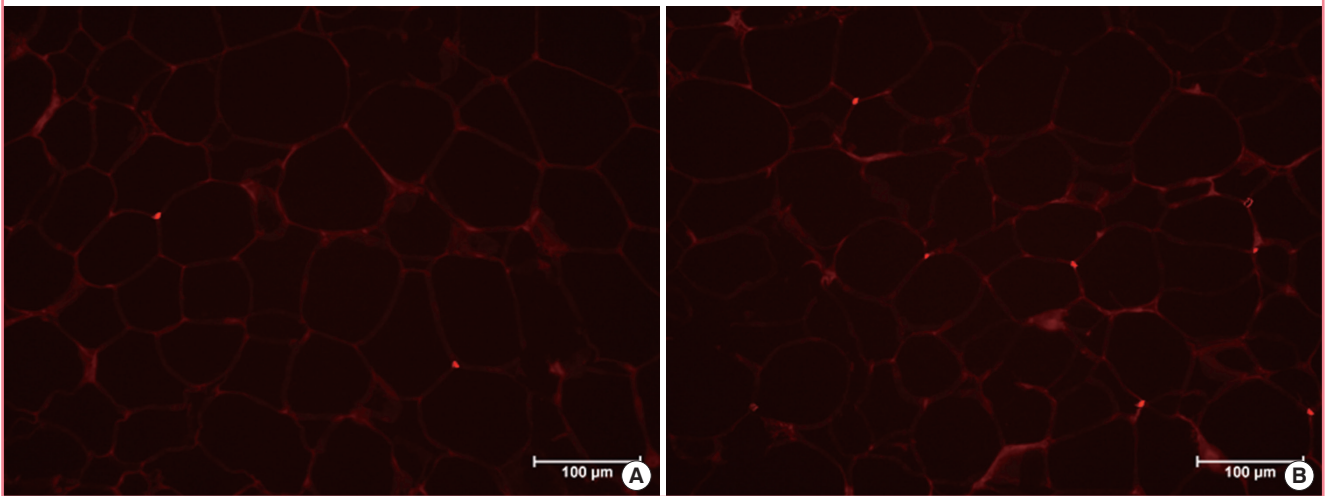


Fig. 8. Microvessels of skin at week one

Representative photographs of the skin tissue of the control group (A) and the experimental group (B) stained with anti-CD31 antibody one week after fat grafting.

**Fig. 9. Microvessels of fat at week one**

Representative photographs of the fat tissue of the control group (A) and the experimental group (B) stained with anti-CD31 antibody one week after fat grafting.



significant difference between the two groups ($P > 0.05$). The microvessel density of the fat tissue specimens was significantly higher in the experimental group (4.1 ± 1.2 per high-power field) than in the control group (2.4 ± 1.0 per high-power field) ($P = 0.006$) (Fig. 9), but no significant difference in mature vessel density of the fat tissue specimens was found between the experimental group (0.9 ± 0.7 per high-power field) and the control group (1.1 ± 0.9 per high-power field).

Three months after fat grafting, the microvessel density of the skin specimens was significantly higher in the experimental group (14.7 ± 3.2 per high-power field) than in the control group (9.9 ± 2.0 per high-power field) ($P = 0.002$) and the mature vessel density of the skin specimens was significantly higher

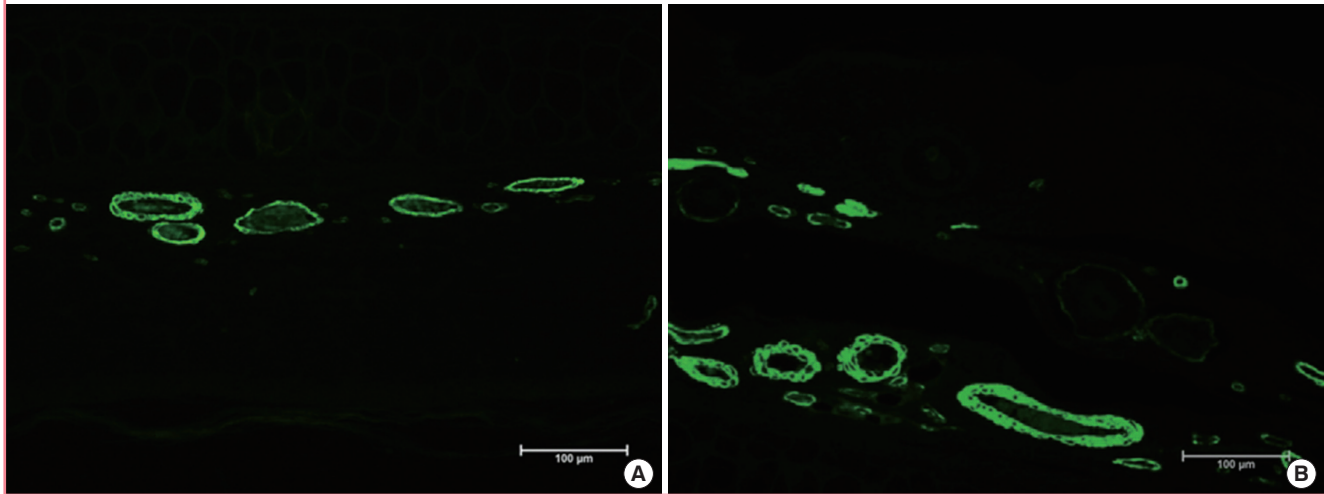
in the experimental group (17.7 ± 3.9 per high-power field) than in the control group (7.8 ± 1.7 per high-power field) ($P < 0.001$) (Fig. 10). No significant difference in microvessel density of the fat tissue specimens was found between the experimental group (2.2 ± 0.9 per high-power field) and the control group (3.0 ± 0.9 per high-power field), but the mature vessel density of the fat tissue specimens was significantly higher in the experimental group (2.3 ± 1.0 per high-power field) than in the control group (0.8 ± 1.0 per high-power field) ($P < 0.001$) (Fig. 11).

DISCUSSION

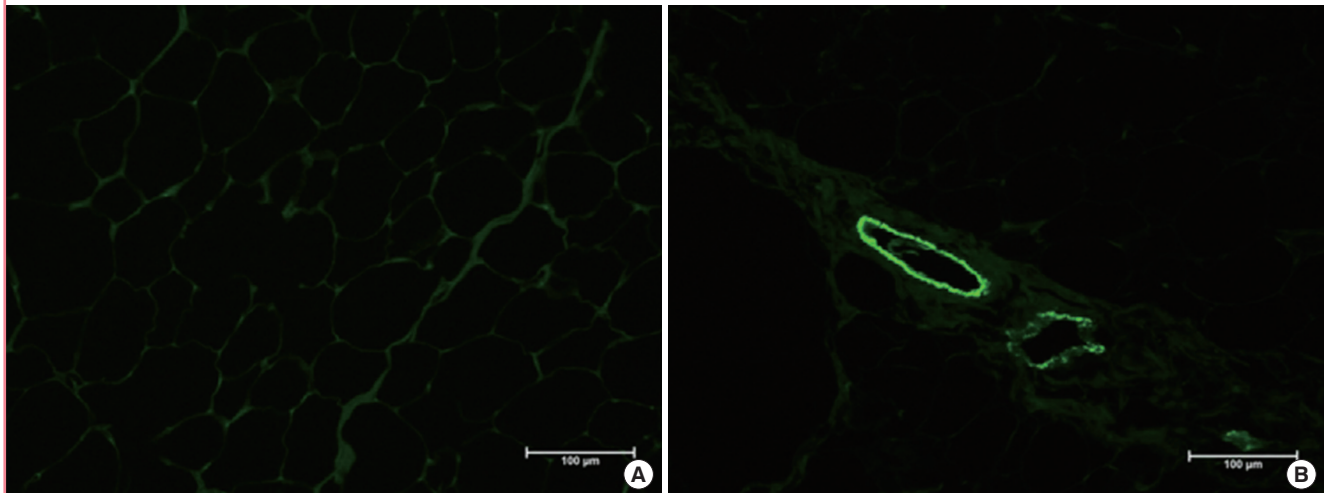
The results of this study strongly support the authors' hypothesis

Fig. 10. Macrovasculars of skin at three months

Representative photographs of the skin tissue of the control group (A) and the experimental group (B) stained with anti-human smooth muscle actin antibody three months after fat grafting.

**Fig. 11. Macrovasculars of fat at three months**

Representative photographs of the fat tissue of the control group (A) and the experimental group (B) stained with anti-human smooth muscle actin antibody three months after fat grafting.



that preconditioning of fat graft recipient site with external application of negative pressure increases the recipient site vascularity, which improves the fat graft survival rate. In the pilot study, it was hard to preserve continuous negative pressure. Rabbits bite the NPWT tube and break the sealing of ear by their hind legs. To protect NPWT device and preserve continuous negative pressure, NPWT tube was wrapped by steel wire and ear was protected with bandage (Peha-faft). The ear was chosen as the recipient site because it has no subcutaneous fat. The fat was collected *via en bloc* harvesting to accurately measure the weight change. Fat tissues are vulnerable to hypoxic damage. Graft vascularization is induced by neoangiogenesis, which occurs in the vascular system of the host bed four days after the graft. Howev-

er, this revascularization process is limited to the peripheral region [11]. If the blood supply is delayed in adipocytes, necrosis occurs. Thus, because early and adequate revascularization is critical for fat graft survival, an abundantly vascularized recipient site has been emphasized as an important factor in the improvement of fat graft survival [3,12]. Many studies using epidermal growth factor, fibroblast growth factor, and platelet-rich plasma have been conducted to improve the fat graft survival rate and have shown satisfactory results [11,13,14]. However, these methods had the disadvantages of requiring a professional laboratory and complex procedures. On the contrary, external application of negative pressure has the advantages of not requiring a professional laboratory, being easy to conduct, and having good

outcomes. Negative pressure therapy has many effects, the authors were particularly interested in its role in promoting angiogenesis [9]. If hypoxia occurs in tissues due to negative pressure, hypoxia-inducible-factor 1 α is expressed. This substance stimulates VEGF expression, which promotes angiogenesis [15]. In a study by Heit et al. [9], negative pressure to intact skin of mouse, subcutaneous tissue blood vessel density was 1.9-fold increased and intense remodeling of vessels were shown. Thus authors hypothesized same mechanism as NPWT promotes angiogenesis could be occurred at the negative pressure applied intact skin, further study about this required. Various animal studies have been conducted on NPWT and have showed that NPWT has various effects depending on the intensity of the negative pressure. Many previous animal studies on NPWT showed that angiogenesis and vascularity increased when -125 mm Hg pressure was applied for one week [15,16]. Accordingly, the present study also applied -125 mm Hg pressure for one week. The cyclical use of NPWT yields a more robust response. However, as cyclical suction on a wound causes more pain, continuous suction is commonly used. Considering this trend, continuous suction has been applied to animals in various studies [9,16]. The numbers of graft microvessels increased until one week after the fat graft and decreased thereafter [1,17]. In a study by Kato et al. [18], necrosis occurred in all adipocytes seven days after the fat graft, except for the most superficial survival zone of the fat. Immunohistochemistry one week after the fat graft showed that the microvessel density of the grafted fat significantly increased in the experimental group compared to that of the control group. Hormone-stimulated lipolysis analysis was introduced by Zhu et al. [19]. On the present study, same as the research by Zhu et al. [19], linear correlation of fat tissue viability with glycerol release was observed *via* a standard curve. The viable adipocytes were observed more in the experimental group compared to the control group. The clinical significance of lipolysis assay was reconfirmed in the measurement of fat survival rate three months after the graft. Thus, the lipolysis assay is useful for further study of fat viability.

In the present experimental group, microvessel density was lower and mature vessel density was higher three months after fat grafting than one week after the fat grafting. These results are may attributable to the maturation or degeneration of the neo-genic capillary that increased due to application of negative pressure [20]. The mature vessel density of skin of experimental group at one week after fat grafting and the microvessel density of grafted fat of experimental group at three months after grafting was lower than control group, although there were no statistical significant. We consider the result was caused by limited number of animals. If we studied with more number of animals,

the result would be almost same between experimental and control groups. Various studies have been conducted to improve the fat graft survival rate, as shown in Brava, wherein the volume and vascularity of the recipient site are increased by an external expansion device [2,7,8,21]. In the study on Brava, the graft survival rate increased via pre-expansion after large volume fat grafting on the breast. Greater interest was shown in the reduction of graft-to-capacity ratio and interstitial pressure than in increase in recipient site vascularity. However, in small-volume fat grafting, including facial fat grafting, the interstitial pressure of the recipient site is low, so a large recipient volume is unnecessary. Thus, if negative pressure is applied before small-volume fat grafting, recipient site vascularity and fat graft survival are expected to improve [8,22]. The present study had a few limitations. In the study using Brava, the applied negative pressure was lower than the -125 mm Hg used in the present study. In a study by Heit et al. [9] on external volume expansion using a murine model, the application of -25 mm Hg pressure for one week increased the vessel density 1.9-fold. In the present study, a -125 mm Hg pressure was applied to maximize the angiogenic effect of negative pressure. However, further study is required at various negative pressures and treatment durations, with simultaneous evaluation of increases in volume expansion and vascularity of the recipient site and changes in fat graft survival rate. This animal study showed that preconditioning of fat graft recipient site with external application of negative pressure increased recipient site vascularity and thus fat graft survival. Although the negative pressure therapy currently used in clinical practice focuses less on the importance of improvement in recipient site vascularity than on the volumetric pre-expansion of the recipient site, improvement in recipient site vascularity also improves fat graft survival, which shows that negative pressure can be useful for increasing fat graft survival rate after small-volume fat grafting.

REFERENCES

1. Langer S, Sinitsina I, Biberthaler P, et al. Revascularization of transplanted adipose tissue: a study in the dorsal skinfold chamber of hamsters. *Ann Plast Surg* 2002;48:53-9.
2. Del Vecchio DA, Del Vecchio SJ. The graft-to-capacity ratio: volumetric planning in large-volume fat transplantation. *Plast Reconstr Surg* 2014;133:561-9.
3. Yazawa M, Mori T, Tuchiya K, et al. Influence of vascularized transplant bed on fat grafting. *Wound Repair Regen* 2006;14:586-92.
4. Schintler MV. Negative pressure therapy: theory and practice. *Diabetes Metab Res Rev* 2012;28 Suppl 1:72-7.

5. Timmers MS, Le Cessie S, Banwell P, et al. The effects of varying degrees of pressure delivered by negative-pressure wound therapy on skin perfusion. *Ann Plast Surg* 2005;55:665-71.
6. Kairinos N, Solomons M, Hudson DA. Negative-pressure wound therapy I: the paradox of negative-pressure wound therapy. *Plast Reconstr Surg* 2009;123:589-98.
7. Khouri RK, Eisenmann-Klein M, Cardoso E, et al. Brava and autologous fat transfer is a safe and effective breast augmentation alternative: results of a 6-year, 81-patient, prospective multicenter study. *Plast Reconstr Surg* 2012;129:1173-87.
8. Khouri RK, Rigotti G, Cardoso E, et al. Megavolume autologous fat transfer: part I. Theory and principles. *Plast Reconstr Surg* 2014;133:550-7.
9. Heit YI, Lancerotto L, Mesteri I, et al. External volume expansion increases subcutaneous thickness, cell proliferation, and vascular remodeling in a murine model. *Plast Reconstr Surg* 2012;130:541-7.
10. Gigliofiorito P, Marangi GF, Langella M, et al. The effects of negative pressure on blood supply and the adipogenic role of edema. *Plast Reconstr Surg* 2013;131:931e-932e.
11. Oh DS, Cheon YW, Jeon YR, et al. Activated platelet-rich plasma improves fat graft survival in nude mice: a pilot study. *Dermatol Surg* 2011;37:619-25.
12. Baran CN, Celebioglu S, Sensoz O, et al. The behavior of fat grafts in recipient areas with enhanced vascularity. *Plast Reconstr Surg* 2002;109:1646-51.
13. Park B, Kong JS, Kang S, et al. The effect of epidermal growth factor on autogenous fat graft. *Aesthetic Plast Surg* 2011;35:738-44.
14. Tamura E, Fukuda H, Tabata Y. Adipose tissue formation in response to basic fibroblast growth factor. *Acta Otolaryngol* 2007;127:1327-31.
15. Erba P, Ogawa R, Ackermann M, et al. Angiogenesis in wounds treated by microdeformational wound therapy. *Ann Surg* 2011;253:402-9.
16. Scherer SS, Pietramaggiori G, Mathews JC, et al. Short periodic applications of the vacuum-assisted closure device cause an extended tissue response in the diabetic mouse model. *Plast Reconstr Surg* 2009;124:1458-65.
17. Nishimura T, Hashimoto H, Nakanishi I, et al. Microvascular angiogenesis and apoptosis in the survival of free fat grafts. *Laryngoscope* 2000;110:1333-8.
18. Kato H, Mineda K, Eto H, et al. Degeneration, regeneration, and cicatrization after fat grafting: dynamic total tissue remodeling during the first 3 months. *Plast Reconstr Surg* 2014;133:303e-313e.
19. Zhu M, Cohen SR, Hicok KC, et al. Comparison of three different fat graft preparation methods: gravity separation, centrifugation, and simultaneous washing with filtration in a closed system. *Plast Reconstr Surg* 2013;131:873-80.
20. Chen SZ, Li J, Li XY, et al. Effects of vacuum-assisted closure on wound microcirculation: an experimental study. *Asian J Surg* 2005;28:211-7.
21. Del Vecchio DA, Bucky LP. Breast augmentation using pre-expansion and autologous fat transplantation: a clinical radiographic study. *Plast Reconstr Surg* 2011;127:2441-50.
22. Del Vecchio D, Rohrich RJ. A classification of clinical fat grafting: different problems, different solutions. *Plast Reconstr Surg* 2012;130:511-22.