

# Non-Melanocytic Benign Tumors of the Face: A Retrospective Study

Kyoung Min Lee, Jung Soo Lim, Kyung Hee Min, Jong Hun Lee, Sung Hee Hong, Hye Kyung Lee

*Department of Plastic and Reconstructive Surgery, Eulji General Hospital, Eulji University School of Medicine, Seoul, Korea*

**Background** Although plastic surgeons daily encounter various facial tumors in the field, reports limited on face are scarce. In our study, we want to provide basic epidemiologic data to help clinicians to decide the proper management for their patients.

**Methods** We retrospectively reviewed the medical records of patients including age and gender, location and size of the tumor, histopathologic result, recurrence, type of anesthesia and any associated disorders who had undergone a surgical removal of their facial tumors and received the histopathologic report in the same institution between January 2009 and October 2012.

**Results** One hundred eighty-nine patients with 203 non-melanocytic benign tumors were included. The most frequent site of tumors was the central subunit of the forehead, followed by the lateral subunit of the cheek and the auricular unit. Of 36 different histopathologic results, the epidermal cyst was most frequent, followed by lipoma, pilomatricoma and osteoma. Statistical analysis showed that males were dominant in the epidermal cyst and lipoma groups. While, females were dominant in the osteoma and pilomatricoma groups. No associations were found between lesions and other diseases.

**Conclusions** Our study is the at most specific and concentrated study on non-melanocytic benign tumors of the face. We expect the epidemiologic data of our study may help plastic surgeons who are confronted with so many facial lesions in the field to decide on the most proper management for their patients.

**Keywords** Benign tumors / Face / Retrospective studies

**Correspondence:** Kyung Hee Min  
Department of Plastic and Reconstructive Surgery, Eulji General Hospital, Eulji University School of Medicine, 68 Hangeulbisuk-ro, Nowon-gu, Seoul 139-872, Korea  
Tel: +82-2-970-8255  
Fax: +82-2-978-4772  
E-mail: mkh797@hanmail.net

This article had presented at 70th Congress of the Korean Society of Plastic and Reconstructive Surgeons on November 9–11, 2012, in Seoul, Korea.

No potential conflict of interest relevant to this article was reported.

Received: 30 Jul 2014 • Revised: 27 Nov 2014 • Accepted: 27 Nov 2014  
pISSN: 2234-6163 • eISSN: 2234-6171 • <http://dx.doi.org/10.5999/aps.2015.42.2.201> • Arch Plast Surg 2015;42:201-206

## INTRODUCTION

In the field of plastic surgery, we see various facial tumors with many different appearances. We don't only see conspicuous lesions such as melanocytic skin lesions and skin cancers, but we also meet patients with benign lesions that warrant attention only after growing big enough to be seen or palpated. Lesions on the face raise critical aesthetic problems for patients. For those cases,

surgical resections are performed either for the histological diagnosis or for aesthetics. There are many reviews on benign tumors [1-7], but reports especially referring to the face are scarce.

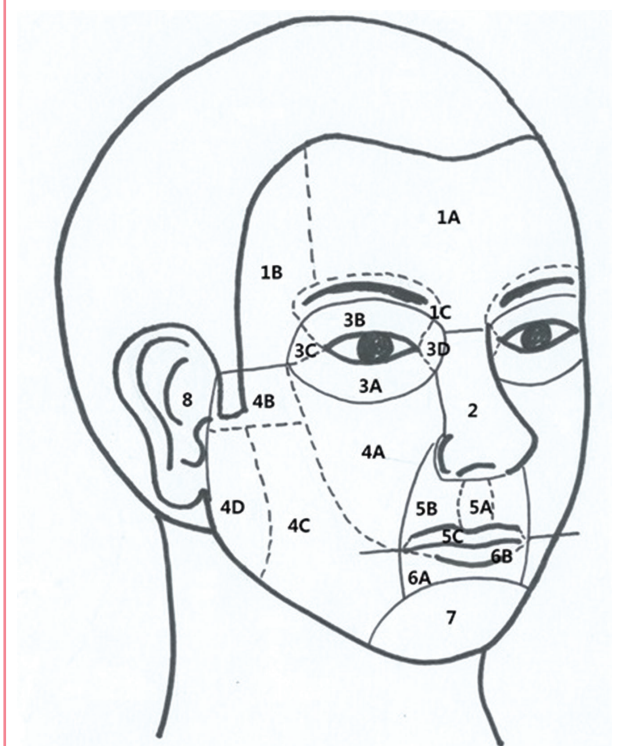
We retrospectively analyzed clinical data of these non-melanocytic benign facial lesions in order to determine the nature of tumors and to provide basic epidemiologic data to help clinicians in their decision on the best approach and treatment for their patients.

## METHODS

We retrospectively reviewed medical records of patients whose facial lesions had been removed surgically in the department of plastic surgery at a single institution between January 2009 and October 2012. Histopathologic examination was enforced for nearly all cases that involved surgical removal. Melanocytic and malignant lesions were excluded. We analyzed the following variables: age, sex, location, size, histopathology, single or multiple, recurrence, type of anesthesia and any other associated disorders. Patients were divided into four groups according to their age; younger than 6 years (from birth to preschool age), between 6 and 18 years (from middle childhood to adolescence), between 19 and 64 years (adult age), and older than 64 years (old age). The location was categorized by facial aesthetic units (Fig. 1) [8]. The SPSS ver. 22.0 software program (IBM Co., Armonk, NY, IL, USA) was used. Variance and frequency were analyzed and the association between each variable was evaluated using the Pearson  $\chi^2$  test.

**Fig. 1. Facial aesthetic units**

1, forehead unit (1A, central subunit; 1B, lateral subunit; 1C, eyebrow subunit); 2, nasal unit; 3, eyelid units (3A, lower-lid unit; 3B, upper-lid unit; 3C, lateral canthal subunit; 3D, medial canthal subunit); 4, cheek unit (4A, medial subunit; 4B, zygomatic subunit; 4C, lateral subunit; 4D, buccal subunit); 5, upper-lip unit (5A, philtrum subunit; 5B, lateral subunit; 5C, mucosal subunit); 6, lower-lip unit (6A, central subunit; 6B, mucosal subunit); 7, mental unit; 8, auricular unit [8].



## RESULTS

One hundred eighty-nine patients with 203 non-melanocytic benign tumors were included. 92% of patients had a single lesion and 88% of surgical removals were conducted with local anesthesia. There were 107 male (57%) and 82 female (43%). The recurrence rate was 11% (20 out of 189 patients) and the most common recurring type was the epidermal cyst (12 out of 82 lesions) (Table 1). The patients' ages ranged between 11 months and 84 years, with a mean age of  $36.41 \pm 17.5$  years. The most frequent age group was the adult age group, especially in the fourth and fifth decades of life. The mean size of tumors was  $0.96 \pm 0.45$  cm and the most frequent size group was 0.6–1 cm (39%) followed by 1.1–2 cm (35%) (Fig. 2).

The most frequent site of tumors was the central subunit of the forehead (1A) with 39 (19.2%), followed by the lateral subunit

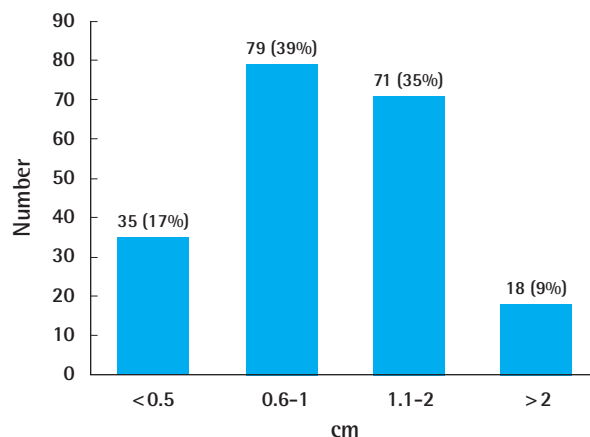
**Table 1. Characters of patients**

Subtypes of character	Frequency
Gender	
Male	107 (57)
Female	82 (43)
Anesthesia	
Local	166 (88)
General	23 (12)
No. of tumors	
Single	173 (92)
Multiple	16 (8)
Recurrence	
Recurred	20 (11)
Unrecurred	169 (89)
Total	189 (100)

Values are presented as number (%).

**Fig. 2. Numbers of lesions by size**

The mean size of tumors was  $0.96 \pm 0.45$  cm and the most frequent size group was 0.6–1 cm (39%) followed by 1.1–2 cm (35%).



of the cheek (4C) with 38 (18.7 %) and the auricular unit (8) with 31 (15.3%). Lipoma was most frequently found (35.9%) in the central subunit of the forehead. On the other hand, epidermal cyst of the most common pathologic type was most frequent in both lateral subunits of the cheek (73.7%) and in the auricular unit (45.2%).

Of the 36 different histopathologic results, the epidermal cyst was most frequent with 82 (40.4%), followed by lipoma with 22 (10.8%), pilomatricoma with 19 (9.4%), osteoma with 9 (4.4%), chronic inflammation with 6 (3%), pyogenic granuloma with 6 (3%), dermal fibroma with 5 (2.5%) and seborrheic keratosis with 5 (2.5%). Chronic inflammation was accompanied by granuloma or foreign body reactions which was marked

with histiocytic and giant cell infiltration. Abscess resulted from ruptured cystic lesions with foreign body reaction. By age groups, all 8 cases younger than 6 years presented with pilomatricoma and epidermal cyst was most frequent in all other age groups (Table 2).

According to the statistical analysis, some histopathologic types were strongly associated with gender and age group in a statistically significant manner ( $P < 0.05$ ). In the epidermal cyst and lipoma groups, males were dominant and the ratio of male to female patients was 2.24:1 and 2.14:1, respectively. Conversely, females were dominant in the osteoma and pilomatricoma groups, with a male to female patient ratio of 1:3.5 and 1:2.17, respectively. By age group, the peak of age-frequency distribu-

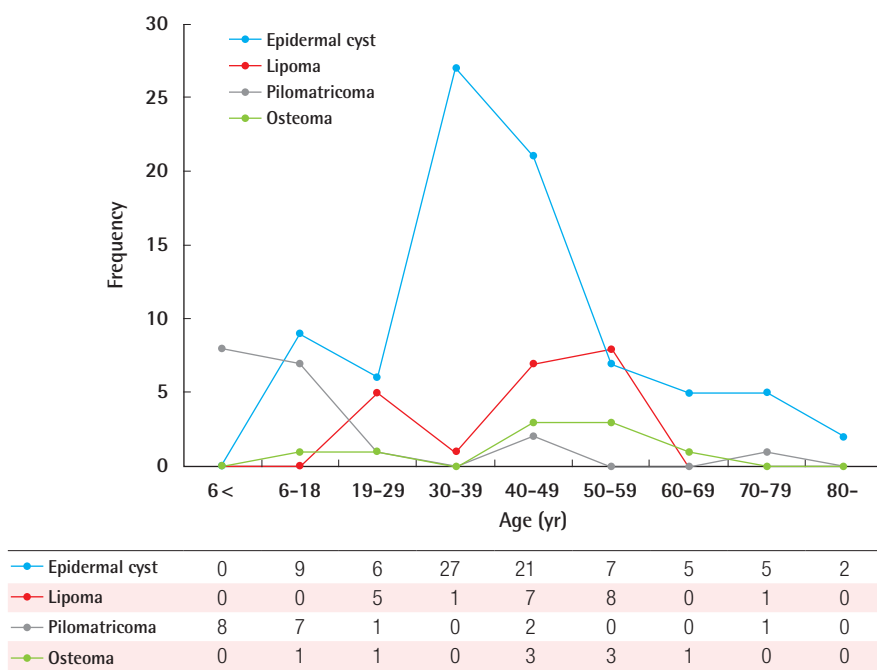
**Table 2. Distribution of non-melanocytic benign tumors according to age and gender**

Histopathologic result	Age (yr)				Gender		Total
	< 6	6–18	19–64	≥ 65	Male (%)	Female (%)	Frequency (%)
Epidermal cyst	0	9	63	10	58 (28.6)	24 (11.8)	82 (40.4)
Lipoma	0	0	21	1	15 (7.4)	7 (3.4)	22 (10.8)
Pilomatricoma	8	6	3	2	6 (3.0)	13 (6.4)	19 (9.4)
Osteoma	0	1	8	0	2 (1)	7 (3.4)	9 (4.4)
Chronic inflammation	0	0	6	0	2 (1)	4 (2)	6 (3.0)
Pyogenic granuloma	0	0	5	1	4 (2)	2 (1)	6 (3.0)
Dermal fibroma	0	0	5	0	2 (1)	3 (1.5)	5 (2.5)
Seborrheic keratosis	0	0	3	2	1 (0.5)	4 (2)	5 (2.5)
Dermoid cyst	0	1	2	1	3 (1.5)	1 (0.5)	4 (2.0)
Hemangioma	0	0	2	2	2 (1)	2 (1)	4 (2.0)
Trichilemmal cyst	0	1	2	1	1 (0.5)	3 (1.5)	4 (2.0)
Wart	0	0	3	1	3 (1.5)	1 (0.5)	4 (2.0)
First branchial groove lesion	0	1	2	0	2 (1)	1 (0.5)	3 (1.5)
Xanthelasma	0	0	3	0	0 (0)	3 (1.5)	3 (1.5)
Actinic keratosis	0	0	0	2	2 (1)	0 (0)	2 (1.0)
Chalazion	0	1	1	0	0 (0)	2 (1)	2 (1.0)
Chondroid syringoma	0	0	1	1	1 (0.5)	1 (0.5)	2 (1.0)
Steatocystoma	0	1	1	0	2 (1)	0 (0)	2 (1.0)
Trichoepithelioma	0	1	1	0	1 (0.5)	1 (0.5)	2 (1.0)
Trichofolliculoma	0	0	1	0	0 (0)	1 (0.5)	1 (0.5)
Angiomyoma	0	0	1	0	0 (0)	1 (0.5)	1 (0.5)
Vascular leiomyoma	0	0	1	0	0 (0)	1 (0.5)	1 (0.5)
Eccrine poroma	0	0	1	0	0 (0)	1 (0.5)	1 (0.5)
Cylindroma	0	0	1	0	0 (0)	1 (0.5)	1 (0.5)
Abscess	0	1	0	0	1 (0.5)	0 (0)	1 (0.5)
Degenerated cartilage and fibrosis	0	0	1	0	1 (0.5)	0 (0)	1 (0.5)
Dilated pore	0	0	1	0	0 (0)	1 (0.5)	1 (0.5)
Eruptive vellus hair cyst	0	0	1	0	0 (0)	1 (0.5)	1 (0.5)
Hamartomatous lesion	0	1	0	0	1 (0.5)	0 (0)	1 (0.5)
Keloid	0	0	1	0	1 (0.5)	0 (0)	1 (0.5)
Mucocele	0	0	1	0	0 (0)	1 (0.5)	1 (0.5)
Nodular epidermal proliferation	0	0	1	0	0 (0)	1 (0.5)	1 (0.5)
Reactive hyperplasia of lymph node	0	1	0	0	1 (0.5)	0 (0)	1 (0.5)
Sebaceous hyperplasia	0	1	0	0	0 (0)	1 (0.5)	1 (0.5)
Antholytic dyskeratosis	0	0	1	0	1 (0.5)	0 (0)	1 (0.5)
Arterial malformation	0	0	1	0	1 (0.5)	0 (0)	1 (0.5)
Total	8	26	145	24	113	90	203 (100.0)

Values are presented as number or number (%).

**Fig. 3. Age-frequency distribution**

The peak of age-frequency distribution of four most common pathologic types was varied by age groups.



**Table 3. Analysis of frequency and distribution of epidermal cysts by facial aesthetic unit**

Facial unit	Age (yr)				Gender		Total Frequency (%)
	< 6	6-18	19-64	≥ 65	Male	Female	
1A	0	0	3	2	1	4	5 (6.1)
1B	0	0	0	0	0	0	0 (0.0)
1C	0	1	4	0	4	1	5 (6.1)
2	0	2	1	0	2	1	3 (3.7)
3A	0	0	0	0	0	0	0 (0.0)
3B	0	0	3	3	3	3	6 (7.3)
3C	0	0	1	0	1	0	1 (1.2)
3D	0	0	1	0	0	1	1 (1.2)
4A	0	1	1	1	2	1	3 (3.7)
4B	0	0	0	0	0	0	0 (0.0)
4C	0	1	24	3	22	6	28 (34.1)
4D	0	0	5	1	4	2	6 (7.3)
5A	0	0	0	0	0	0	0 (0.0)
5B	0	0	1	0	1	0	1 (1.2)
6A	0	0	1	0	1	0	1 (1.2)
6B	0	0	0	0	0	0	0 (0.0)
7	0	2	6	0	6	2	8 (9.8)
8	0	2	12	0	11	3	14 (17.1)
Total	0	9	63	10	58	24	82 (100)

tion was the fourth decade of life in the epidermal cyst group, the fifth and sixth decades of life in both the lipoma and osteoma groups, and the first and second decades of life in the Pilomatricoma group (Fig. 3).

Focusing on the most frequent diagnostic group, epidermal cyst, the most frequent site was the lateral subunit of the cheek with 28 (34.1%), followed by the auricular unit with 14 (17.1%)

and the mental unit with 8 (9.8%) (Table 3).

No associations were found between lesions and other diseases.

## DISCUSSION

There are numerous studies investigating benign skin tumors, especially in the field of dermatology, but these literatures are

about benign tumors on the whole body or study populations are limited to either adults or children [1,2]. The reviews on facial benign lesions are also limited on a specific type of tumor like lipomas or cutaneous cysts [3,4].

Our study was a retrospective analysis on non-melanocytic benign facial tumors by various factors that frequently attend in the field of plastic surgeons.

The forehead unit was the most common predilection site (19.2%), followed by the lateral subunit of the cheek (18.7%) and the auricular unit (15.3%). This is a fairly different result from the predilection site of malignant tumors in the nasal unit [9]. This is because unlike facial malignant tumors which have well-known risk factors (e.g., ultraviolet radiation), benign facial tumors have no definite risk factor. The author therefore speculates that units with relatively larger surface areas are more likely to become the predilection site.

Epidermal cyst is a firm, movable, somewhat protruded subcutaneous lesion that most commonly occurs on the face, scalp, neck and trunk [5]. In the face, the lateral subunit of the cheek (34.1%) and the auricular unit (17.1%) were the most affected sites with the peak of the age-frequency distribution in the fourth decade of life (32.9%). Inner lining cells of this lesion are covered with a stratified squamous epithelium and a granular cell layer is existed adjacent to the keratin and lipid-rich debris containing cyst lumen [6,7]. It is essential to pathologically confirm giant atheromas which mean huge epidermal cysts to rule out malignancy although such changes are rare [10]. In most cases of epidermal cysts, a surgical excision with a minimal incision is the treatment of choice. In some cases of large cysts filled with pus and debris, the surgeon should consider incision and drainage first and then a delayed excision is needed.

This study has the limitation that it is only able to describe the recurrence rate of the epidermal cyst (14.5%, 11 out of 76 patients), due to lack of operative findings about whether the cystic walls were ruptured or not. For further study, it will be helpful that recording operative findings more accurately, so that we can evaluate the correlation between rupture and recurrence.

The second most common benign facial lesions in our study are lipomas which are round, soft, slow-growing and mostly benign tumors that are found in the subcutaneous tissues [11]. In our study, the forehead units were the most affected sites in lipoma (68.2%, 15 out of 22) and the ratio of male to female patients was 1.75:1. These tumors can also be found in deeper tissues such as intramuscular and intermuscular layer, abdominal organs, in the internal auditory canal and even in the cerebellopontine angle [12-14]. Even though those are asymptomatic and there is no specific treatment required, a rapidly growing lipoma could possibly be a liposarcoma. In that case, a complete surgical

excision including capsulectomy is needed to prevent local recurrence. As also found in other literatures, in our study, lipomas have been identified in all age groups but usually first appear between 40 years and 60 years of age (77.27%, 17 out of 22) [15].

In the group with subjects younger than 6 years of age, all 8 cases presented as pilomatricoma which derive from the matrix of the hair follicle and are calcifying cystic nodules that frequently occur in the head and neck area. In commonly arises during the first two decades of life and a carcinomatous transformation of a pre-existing benign pilomatricoma is rare [16]. In our study, 14 out of 19 (77.77%) patients were younger than 18 years old. The ratio of male to female patients was 1:2.2 and the auricular unit (31.6%, 6 out of 19) was the most affected site in pilomatricoma.

Some tumors appearing in children may be markers of other disorders. For example, multiple pilomatricoma may be a cutaneous marker of myotonic dystrophy [17] and should then be seen in a familial setting [18], trichoepithelioma in Brooke-Spiegler syndrome; multiple epidermal cysts in Gardner syndrome and neurofibromas in neurofibromatosis. In our study, there was no association found between skin tumors and other disorders.

Although numerous studies have reported the epidemiology of several benign tumors, our study is the most specific and concentrated on the non-melanocytic benign tumors of the face. We expect the epidemiologic data of our study may help plastic surgeons encountering so many facial lesions in the field to decide the most proper management for their patients.

## REFERENCES

1. Pariser RJ. Benign neoplasms of the skin. *Med Clin North Am* 1998;82:1285-307.
2. Barro-Traore F, Traore A, Konate I, et al. Epidemiological features of tumors of the skin and mucosal membranes in the department of dermatology at the Yalgado Ouedraogo National Hospital, Ouagadougou, Burkina Faso. *Sante* 2003; 13:101-4.
3. Truhan AP, Garden JM, Caro WA, et al. Facial and scalp lipomas: case reports and study of prevalence. *J Dermatol Surg Oncol* 1985;11:981-4.
4. Al-Khateeb TH, Al-Masri NM, Al-Zoubi F. Cutaneous cysts of the head and neck. *J Oral Maxillofac Surg* 2009;67:52-7.
5. Handa U, Chhabra S, Mohan H. Epidermal inclusion cyst: cytomorphological features and differential diagnosis. *Diagn Cytopathol* 2008;36:861-3.
6. Fitzpatrick TB, Wolff K, Suurmond D, et al. *Fitzpatrick's color atlas & synopsis of clinical dermatology*. New York:

- McGraw-Hill Medical; 2005.
7. Orgill DP. Benign and malignant nonmelanocytic tumors of the skin and soft tissue. In: Neligan P, Gurtner GC, editors. *Plastic surgery*. 3rd ed. New York: Elsevier Saunders; 2012. p.707-42.
  8. Fattahi TT. An overview of facial aesthetic units. *J Oral Maxillofac Surg* 2003;61:1207-11.
  9. Choi JH, Kim YJ, Kim H, et al. Distribution of Basal cell carcinoma and squamous cell carcinoma by facial esthetic unit. *Arch Plast Surg* 2013;40:387-91.
  10. Chiu MY, Ho ST. Squamous cell carcinoma arising from an epidermal cyst. *Hong Kong Med J* 2007;13:482-4.
  11. Anders KH, Ackerman AB. Neoplasms of the sub-cutaneous fat. In: Freedberg IM, Fitzpatrick TB, editors. *Fitzpatrick's dermatology in general medicine*. 5th ed. New York: McGraw-Hill; 1999. p.1292-300.
  12. Koh HK, Bhawan J. Tumors of the skin. In: Moschella SL, Hurley HJ, editors. *Dermatology*. 3rd ed. Philadelphia: Saunders; 1992. p.1721-808.
  13. Bigelow DC, Eisen MD, Smith PG, et al. Lipomas of the internal auditory canal and cerebellopontine angle. *Laryngoscope* 1998;108:1459-69.
  14. Zimmermann M, Kellermann S, Gerlach R, et al. Cerebellopontine angle lipoma: case report and review of the literature. *Acta Neurochir (Wien)* 1999;141:1347-51.
  15. Enzinger FM, Weiss SW. *Soft tissue tumors*. 3rd ed. St. Louis: Mosby; 1988.
  16. Sassmannshausen J, Chaffins M. Pilomatrix carcinoma: a report of a case arising from a previously excised pilomatrixoma and a review of the literature. *J Am Acad Dermatol* 2001;44:358-61.
  17. McCulloch TA, Singh S, Cotton DW. Pilomatrix carcinoma and multiple pilomatrixomas. *Br J Dermatol* 1996;134:368-71.
  18. Geh JL, Moss AL. Multiple pilomatrixomata and myotonic dystrophy: a familial association. *Br J Plast Surg* 1999;52:143-5.