

LETTERS

Incorporating a Racket-Handle Skin Bridge and Venous Supercharging to Improve Reliability of the Distally Based Anterolateral Thigh Flap

Fangbo Lin¹, Manzhi Wong², Khong-Yik Chew², Bien-Keem Tan²

¹Department of Plastic Reconstructive and Aesthetic Surgery, Auckland University, Auckland, New Zealand (Aotearoa); ²Department of Plastic Reconstructive Aesthetic Surgery, Singapore General Hospital, Singapore

Correspondence: Bien-Keem Tan

Department of Plastic Reconstructive Aesthetic Surgery, Singapore General Hospital, Outram Road, Singapore 168609

Tel: +65-6321-4686, Fax: +65-6227-3573, E-mail: bienkeem@gmail.com

No potential conflict of interest relevant to this article was reported.

Received: 22 Sep 2014 • Revised: 17 Oct 2014 • Accepted: 22 Oct 2014
pISSN: 2234-6163 • eISSN: 2234-6171
<http://dx.doi.org/10.5999/aps.2015.42.2.240> • Arch Plast Surg 2015;42:240-241

Copyright © 2015 The Korean Society of Plastic and Reconstructive Surgeons
This is an Open Access article distributed under the terms of the Creative Commons Attribution Non-Commercial License (<http://creativecommons.org/licenses/by-nc/3.0/>) which permits unrestricted non-commercial use, distribution, and reproduction in any medium, provided the original work is properly cited.

Sir,

The distally based anterolateral thigh flap is one anatomical variant of the versatile regional flap commonly employed to reconstruct large knee defects [1]. Venous congestion poses a common concern for such flaps as oedema can potentiate complications such as tip necrosis and eventually scar development. To limit loss of mobility secondary to scarring in the knee, the surgeon should take a preventative approach and optimise venous drainage when utilising anterolateral thigh flaps. We present a case combining two manoeuvres, the

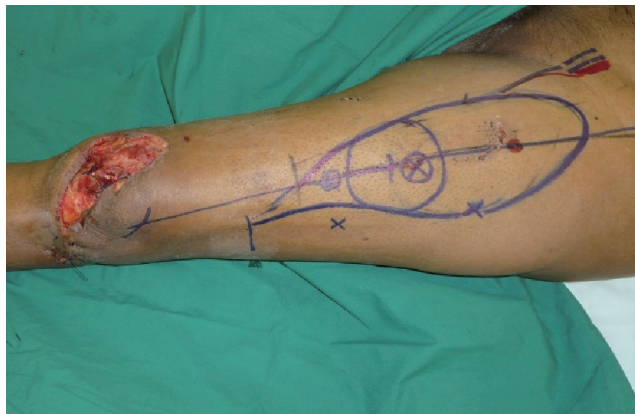

Fig. 1. We planned to preserve a skin bridge in the distal flap, the pivot point for rotational transposition, which acted as a channel for venous outflow.

racket handle with skin bridge technique [2] and anterograde venous drainage augmentation [3] to maximise venous outflow.

Our 62-year-old patient presented with an open patella fracture sustained in a road traffic accident where initial treatment including wound debridement and cerclage wiring was performed. Concurrent skin loss sized 12 cm by 6 cm over the knee was resurfaced later with an anterolateral thigh flap. During the reconstruction, we located the dominant cutaneous perforator in the distal thigh and traced it back to the descending branch of the lateral femoral circumflex artery. The proximal descending branch was clamped with a micro-clamp before division to check that there was adequate retrograde perfusion. In this case, we noted that the distal segment was still pulsating strongly after clamping, indicating robust arterial flow from collateral supply in the knee [2]. Maximisation of venous drainage is imperative in these flaps to reduce risk of congestion and subsequent complications such as necrosis, scarring and flap loss (Figs. 1–5).

Two manoeuvres were employed in this case to improve venous drainage; the first was a racket-shaped design which gently tapered

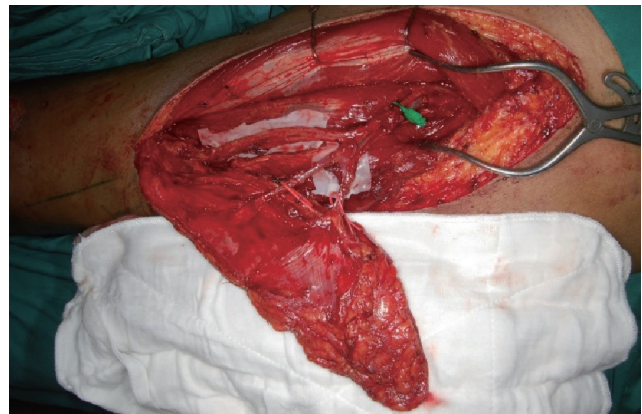

Fig. 2. Two cutaneous perforators were identified and shown to be strongly pulsatile even after the descending branch was clamped proximally.

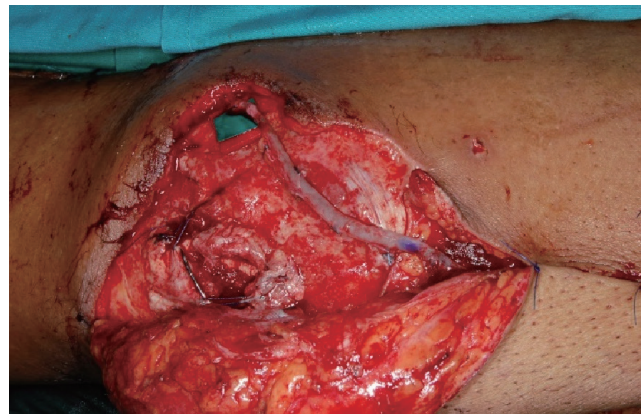

Fig. 3. The great saphenous vein was mobilised to the descending lateral circumflex vein so an anastomoses can be formed after flap transposition.

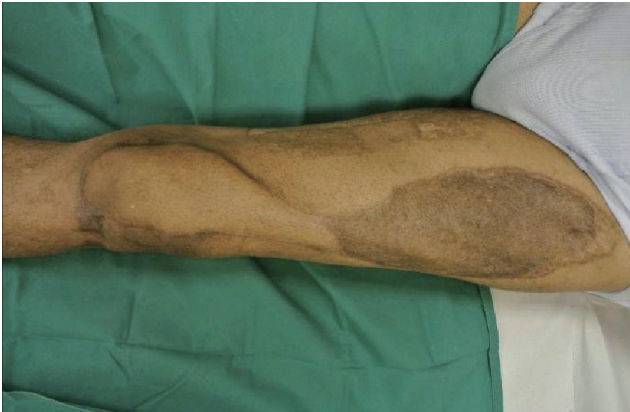

Fig. 4. At two year follow-up the defect has been closed with little overlying tension and minimal scarring allowing for acceptable range of movement. Minor scar revision of the dog-ear over the pivot point of the flap had been done.

into a short “handle”. This was a full-thickness skin bridge at the pivot point where the proximal flap was rotated 180 degrees downward towards the recipient site. The bridge acted to offer cutaneous and subcutaneous continuity and maintained an intact subdermal plexus to serve as additional channel for venous drainage [2]. After the flap was transposed to the knee, a vein graft was utilised to connect the descending femoral circumflex vein to the great saphenous to further augment drainage [3].

The patient experienced no evidence of postoperative flap congestion despite being at higher risk due to his large flap and at two year follow-up, showed good mobility ranging between 0 and 120 degrees flexion in the knee.

Anterolateral thigh flaps are well understood and the anatomy well delineated, offering a large expanse of skin commonly utilised as free flaps. The distally based variant, supplied by retrograde arterial flow, can be used for coverage of knee defects [1]. Robust retrograde flow was observed intraoperatively in our case, likely secondary to medial geniculate contribution. Our concern was with insufficient venous drainage risking flap congestion and subsequent development of marginal flap necrosis [3]. The case illustrates two techniques available to alleviate venous congestion with either the preservation of a dermal and subcutaneous bridge in our racket handle or the antero-gradual anastomosis of a distal vein to drain the main pedicle vein. Although both techniques have been employed in this case to optimise venous drainage, each strategy is probably sufficient by itself to enhance venous outflow as there will be situations when only one is feasible. A skin bridge is unadvised in obese patients, as the thickness of subcutaneous fat physically restricts the pivoting of the flap, greatly limiting its reach. Conversely, venous anastomosis may be impractical in cases where the great saphenous vein is thrombosed, inflamed, or previously harvested for coronary bypass surgery.

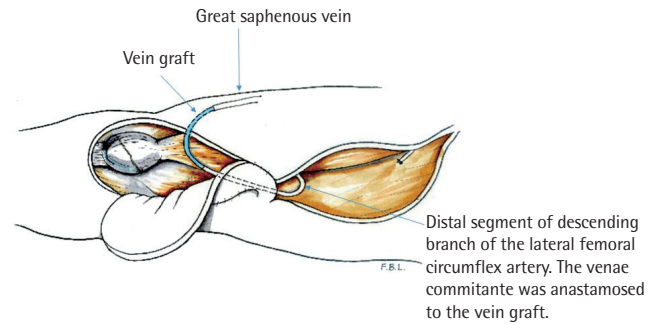


Fig. 5. Diagram of the transposed anterolateral thigh flap after anastomosing the main pedicle vein with the great saphenous vein.

References

1. Wong CH, Goh T, Tan BK, et al. The anterolateral thigh perforator flap for reconstruction of knee defects. *Ann Plast Surg* 2013;70:337-42.
2. Erba P, Raffoul W, Bauquis O. Safe dissection of the distally based anterolateral thigh flap. *J Reconstr Microsurg* 2012;28:405-11.
3. Lin CH, Hsu CC, Lin CH, et al. Antegrade venous drainage in a reverse-flow anterolateral thigh flap. *Plast Reconstr Surg* 2009;124:273e-274e.

Thinning: The Difference between Free and Propeller Perforator Flaps

Benoit Chaput¹, Christian Herlin², Farid Bekara², Nicolas Bertheuil³

¹Department of Plastic reconstructive Surgery and Burns, University of Toulouse, Toulouse; ²Department of Plastic Reconstructive Surgery Unit, Lapeyronie Burn Center, Montpellier; ³Department of Plastic, Reconstructive and Aesthetic Surgery, Hospital Sud, University of Rennes, Rennes, France

Correspondence: Benoit Chaput

Department of Plastic Reconstructive Surgery and Burns, University of Toulouse, CHU Rangueil, 1, Avenue Jean POULHES, 31059 Toulouse, France
Tel: +33672391770, Fax: +5-61-32-22-37, E-mail: Benoitchaput31@gmail.com

No potential conflict of interest relevant to this article was reported.

Received: 26 Dec 2014 • Revised: 6 Jun 2015 • Accepted: 7 Jun 2015

pISSN: 2234-6163 • eISSN: 2234-6171

<http://dx.doi.org/10.5999/aps.2015.42.2.241> • Arch Plast Surg 2015;42:241-242

Copyright © 2015 The Korean Society of Plastic and Reconstructive Surgeons

This is an Open Access article distributed under the terms of the Creative Commons Attribution Non-Commercial License (<http://creativecommons.org/licenses/by-nc/3.0/>) which permits unrestricted non-commercial use, distribution, and reproduction in any medium, provided the original work is properly cited.

Dear Sir,

We read with great interest the manuscript by Prasetyono et al. [1] titled “Practical considerations for perforator flap thinning proce-