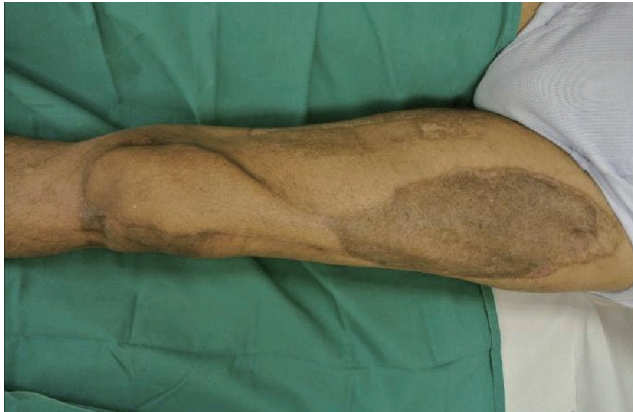

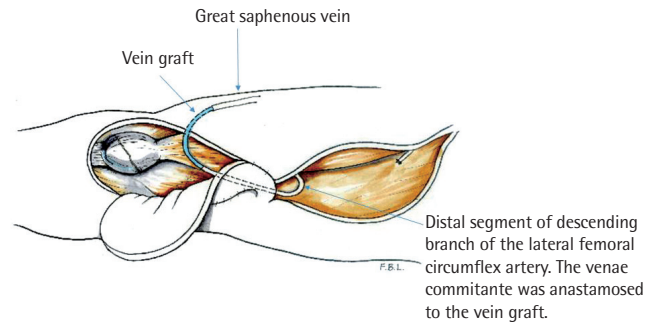


**Fig. 4.** At two year follow-up the defect has been closed with little overlying tension and minimal scarring allowing for acceptable range of movement. Minor scar revision of the dog-ear over the pivot point of the flap had been done.

into a short “handle”. This was a full-thickness skin bridge at the pivot point where the proximal flap was rotated 180 degrees downward towards the recipient site. The bridge acted to offer cutaneous and subcutaneous continuity and maintained an intact subdermal plexus to serve as additional channel for venous drainage [2]. After the flap was transposed to the knee, a vein graft was utilised to connect the descending femoral circumflex vein to the great saphenous to further augment drainage [3].

The patient experienced no evidence of postoperative flap congestion despite being at higher risk due to his large flap and at two year follow-up, showed good mobility ranging between 0 and 120 degrees flexion in the knee.

Anterolateral thigh flaps are well understood and the anatomy well delineated, offering a large expanse of skin commonly utilised as free flaps. The distally based variant, supplied by retrograde arterial flow, can be used for coverage of knee defects [1]. Robust retrograde flow was observed intraoperatively in our case, likely secondary to medial geniculate contribution. Our concern was with insufficient venous drainage risking flap congestion and subsequent development of marginal flap necrosis [3]. The case illustrates two techniques available to alleviate venous congestion with either the preservation of a dermal and subcutaneous bridge in our racket handle or the antero-gradual anastomosis of a distal vein to drain the main pedicle vein. Although both techniques have been employed in this case to optimise venous drainage, each strategy is probably sufficient by itself to enhance venous outflow as there will be situations when only one is feasible. A skin bridge is unadvised in obese patients, as the thickness of subcutaneous fat physically restricts the pivoting of the flap, greatly limiting its reach. Conversely, venous anastomosis may be impractical in cases where the great saphenous vein is thrombosed, inflamed, or previously harvested for coronary bypass surgery.



**Fig. 5.** Diagram of the transposed anterolateral thigh flap after anastomosing the main pedicle vein with the great saphenous vein.

## References

1. Wong CH, Goh T, Tan BK, et al. The anterolateral thigh perforator flap for reconstruction of knee defects. *Ann Plast Surg* 2013;70:337-42.
2. Erba P, Raffoul W, Bauquis O. Safe dissection of the distally based anterolateral thigh flap. *J Reconstr Microsurg* 2012;28:405-11.
3. Lin CH, Hsu CC, Lin CH, et al. Antegrade venous drainage in a reverse-flow anterolateral thigh flap. *Plast Reconstr Surg* 2009;124:273e-274e.

## Thinning: The Difference between Free and Propeller Perforator Flaps

Benoit Chaput<sup>1</sup>, Christian Herlin<sup>2</sup>, Farid Bekara<sup>2</sup>, Nicolas Bertheuil<sup>3</sup>

<sup>1</sup>Department of Plastic reconstructive Surgery and Burns, University of Toulouse, Toulouse; <sup>2</sup>Department of Plastic Reconstructive Surgery Unit, Lapeyronie Burn Center, Montpellier; <sup>3</sup>Department of Plastic, Reconstructive and Aesthetic Surgery, Hospital Sud, University of Rennes, Rennes, France

**Correspondence:** Benoit Chaput

Department of Plastic Reconstructive Surgery and Burns, University of Toulouse, CHU Rangueil, 1, Avenue Jean POULHES, 31059 Toulouse, France

Tel: +33672391770, Fax: +5-61-32-22-37, E-mail: Benoitchaput31@gmail.com

No potential conflict of interest relevant to this article was reported.

Received: 26 Dec 2014 • Revised: 6 Jan 2015 • Accepted: 7 Jan 2015  
pISSN: 2234-6163 • eISSN: 2234-6171  
<http://dx.doi.org/10.5999/aps.2015.42.2.242> • Arch Plast Surg 2015;42:242-242

Copyright © 2015 The Korean Society of Plastic and Reconstructive Surgeons

This is an Open Access article distributed under the terms of the Creative Commons Attribution Non-Commercial License (<http://creativecommons.org/licenses/by-nc/3.0/>) which permits unrestricted non-commercial use, distribution, and reproduction in any medium, provided the original work is properly cited.

Dear Sir,

We read with great interest the manuscript by Prasetyono et al. [1] titled “Practical considerations for perforator flap thinning proce-

dures revisited". We want to discuss some points related to this article and highlight some differences between thinning a free perforator flap versus a propeller perforator flap.

We absolutely agree with the authors regarding the possibility of thinning (or defatting) a flap in which the perforators are generally central, but when the perforators are lateralized we believe that the problem is completely different. Indeed, free perforator flaps are most frequently harvested with centralized perforating vessels on the skin paddle, unlike propeller perforator flaps, in which the perforators are lateralized, because of the necessity of rotation.

We often achieve significant thinning of our free perforator flaps without necrosis or any skin suffering. However, thinning our propeller flaps is often more hazardous and sometimes results in extensive unexplained skin problems.

Therefore, we prospectively compared five tibial posterior perforator flaps harvested with suprafascial dissection including distal 2/3 thinning (in the subcutaneous plane) of the flap and five harvested with subfascial dissection without thinning. The size and rotation were similar; i.e.,  $4 \times 12 \pm 2$  cm with a twist between  $120^\circ$  and  $180^\circ$ . We noted almost no distal suffering in the subfascial group versus distal problems of 10%–20% for three flaps in the suprafascial group. Moreover, all of the flaps harvested in the suprafascial plane and thinned had an initial venous congestion phase greater and more worrying than did the flaps harvested with subfascial dissection.

We believe that the problem of thinning is more venous than arterial. Thinning alters the arterial vasculature little as the dermal plexus

is respected, as explained by Hong et al. [2], but it could reduce venous back flow.

We selected the posterior tibial perforating flap because it is clear that venous problems are much more common in the limbs, and especially the leg, than in the trunk.

Regarding the article by Prasetyono et al., we note some signs of venous suffering at the edge of anterolateral thigh perforator in Fig. 5C and D; these are almost never seen in practice with this flap, which remains very reliable and reproducible. Therefore, the extensive thinning was probably involved in this phenomenon.

In conclusion, perhaps the main problem with thinning is not an impaired arterial supply, but venous back flow, as the subdermal plexus is preserved. If it appears less risky for free perforator flaps or when the perforators are centered on the skin paddle, thinning can be harmful when the perforators are lateralized. For the lower limb, it seems best to avoid thinning propeller perforator flaps unless absolutely necessary.

## References

1. Prasetyono TO, Bangun K, Buchari FB, et al. Practical considerations for perforator flap thinning procedures revisited. *Arch Plast Surg* 2014; 41:693-701.
2. Hong JP, Choi DH, Suh H, et al. A new plane of elevation: the superficial fascial plane for perforator flap elevation. *J Reconstr Microsurg* 2014;30:491-6.