

IMAGES**A Simple, Reliable, and Inexpensive Method for Seroma Drainage**

Matteo Gioacchini, Manuela Bottoni, Luca Grassetti, Alessandro Scalise, Giovanni Di Benedetto

Clinic of Plastic and Reconstructive Surgery, Department of Clinic and Experimental Medicine, Marche Polytechnic University, Ancona United Hospitals, Ancona, Italy

Correspondence: Giovanni Di Benedetto
Clinic of Plastic and Reconstructive Surgery, Department of Clinic and Experimental Medicine, Marche Polytechnic University, Ancona United Hospitals, Via Conca, Ancona 71-60020, Italy
Tel: +39-071-596-5444, Fax: +39-071-596-3453
E-mail: g.m.dibenedetto@univpm.it

No potential conflict of interest relevant to this article was reported.

Received: 25 Jun 2014 • Revised: 29 Jul 2014 • Accepted: 1 Aug 2014
pISSN: 2234-6163 • eISSN: 2234-6171
<http://dx.doi.org/10.5999/aps.2015.42.3.361> • Arch Plast Surg 2015;42:361-362

Copyright © 2015 The Korean Society of Plastic and Reconstructive Surgeons
This is an Open Access article distributed under the terms of the Creative Commons Attribution Non-Commercial License (<http://creativecommons.org/licenses/by-nc/3.0/>) which permits unrestricted non-commercial use, distribution, and reproduction in any medium, provided the original work is properly cited.

Seromas and hematomas are relatively common complications of a variety of surgical procedures. In plastic surgery, they may occur in the postoperative period of abdominoplasty or abdominal wall reconstruction, mastectomy or breast reconstruction, lymphadenectomy, or voluminous neoplasm excision. Furthermore, in our experience, seromas are particularly common in surgical procedures involving the use of biological substitutes [1].

Clinical treatment of seromas is usually performed by repeated evacuation by means of suction using an

appropriately sized syringe (usually 10–50 mL in volume) according to the amount of fluid to be evacuated [2]. In some cases, an ultrasound examination can highlight the depth, volume, and extension of the fluid. In the case of seromas that are more than 100 mL in volume, the use of several syringes is necessary. Whenever a syringe is filled, it should be replaced or depleted by unplugging it from the hypodermic needle, thus exposing the patient to a high risk of infection. Therefore, negative pressure cannot be maintained continuously [3]. In order to avoid these issues, we have developed a new and simple method that allows us to reduce the material used and to minimize the risk of infection.

This device involves the use of basic materials that are easily available in every hospital: a hypodermic needle, preferably a 20 G syringe needle, and high-vacuum Redon drainage. For this system, we used a high-vacuum Redon bottle (Drainobag 300V Lock, B-Braun, Melsungen AG, Germany); however, any kind of drainage can be used. First, it is necessary to make an oblique incision in the terminal portion of the rubber connector, taking care not to excessively shape the rubber in order to maintain the negative pressure. It is now sufficient to plug the connector into the needle hub to achieve the drainage system (Figs. 1, 2). Usually, an accurate plug between the needle and the connector is sufficient to maintain the negative pressure. To avoid disconnections, due, for example, to the stretching of the drainage tube, a plaster may be added to the connection.

After pricking the skin and identifying the seroma, it is possible to open the drainage. The liquid will be drained from the drainage system without the use of different syringes. If a change of the drain site is

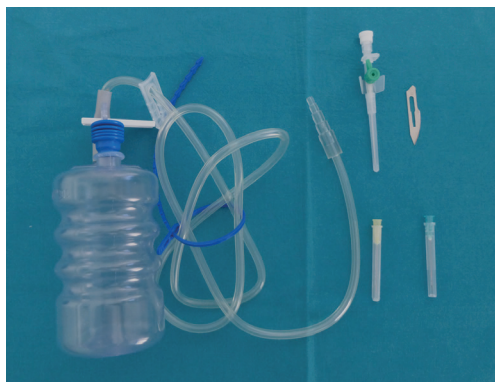

Fig. 1. Equipment for seroma drainage system: a 20 G hypodermic needle (alternatively a 21 G hypodermic needle or a needle cannula), high-vacuum Redon drainage, and a blade.

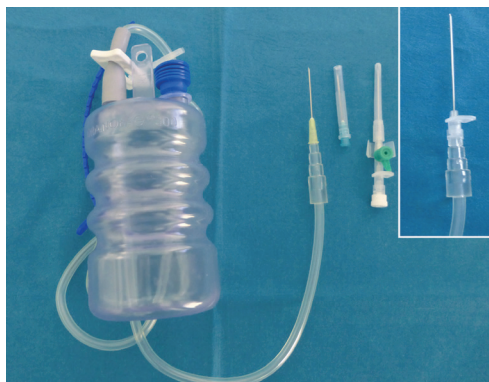


Fig. 2. The assembled seroma drainage system. In the box, the system with the cannula needle.

necessary, simply close the Redon, prick the skin in another site, and reopen the drainage. It will suck the liquid without losing the negative pressure.

This simple technique offers many advantages such as the availability of the required materials, lower risk of infection due to absence of material changing, a reduction in the risk of losing seromas (possible during the syringe changes), easier handling of the needle as compared to the whole syringe, a reduced number of devices with a decrease in costs, and higher accuracy of the drained fluid volume quantification.

This easy drainage method can be used daily for both seromas and liquid hematomas. It is also possible to connect a cannula needle [4] as an alternative to the simple needle. This can be attached to the skin appropriately in order to obtain permanent aspiration. This technique appears to be more accurate and cheaper than traditional drainage methods and can be an excellent alternative in voluminous seroma drains.

References

1. Glasberg SB, Light D. AlloDerm and Strattice in breast reconstruction: a comparison and techniques for optimizing outcomes. *Plast Reconstr Surg* 2012;129:1223-33.
2. Singh A, Thind MS, Mander KS, et al. Syringe suction drain. *Br J Plast Surg* 1992;45:484-5.
3. Tan O, Atik B, Parmaksizoglu D. An adjustable syringe suction drain. *Plast Reconstr Surg* 2005;116:2060-1.
4. Borman H. A simple apparatus for fluid evacuation: syringe suction drain. *Plast Reconstr Surg* 1999;104:1939-40.

Severe Facial Dermatitis Following Rhinoplasty due to an Unusual Etiopathogenesis: Rosacea

Süleyman Taş

Department of Plastic, Reconstructive and Aesthetic Surgery, R.T.E. University Training and Research Hospital, Rize, Turkey

Correspondence: Süleyman Taş

Department of Plastic, Reconstructive and Aesthetic Surgery, R.T.E. University Training and Research Hospital, Rize/center, 53100, Turkey
Tel: +90-464-2130491, Fax: +90-464-2170364
E-mail: drsuleymantas@live.com

I thank Dr. Inci Sema Taş for her valuable help in the preparation of this article.

No potential conflict of interest relevant to this article was reported.

Received: 1 Dec 2014 • Revised: 10 Jan 2015 • Accepted: 14 Jan 2015

pISSN: 2234-6163 • eISSN: 2234-6171

<http://dx.doi.org/10.5999/aps.2015.42.3.362> • Arch Plast Surg 2015;42:362-364

Copyright © 2015 The Korean Society of Plastic and Reconstructive Surgeons

This is an Open Access article distributed under the terms of the Creative Commons Attribution Non-Commercial License (<http://creativecommons.org/licenses/by-nc/3.0/>) which permits unrestricted non-commercial use, distribution, and reproduction in any medium, provided the original work is properly cited.

Cutaneous problems following rhinoplasty are minor, early, and temporary [1]. Usually, contact dermatitis with rash and pustules is observed, caused by the benzoin solution or gum used for increasing the adhesion of the tape. If the tape is applied too tightly, it can cause skin necrosis. Persistent redness and telangiectasia of the nasal skin are late cutaneous problems following rhinoplasty [1].

Rosacea is a chronic erythematous disease of the

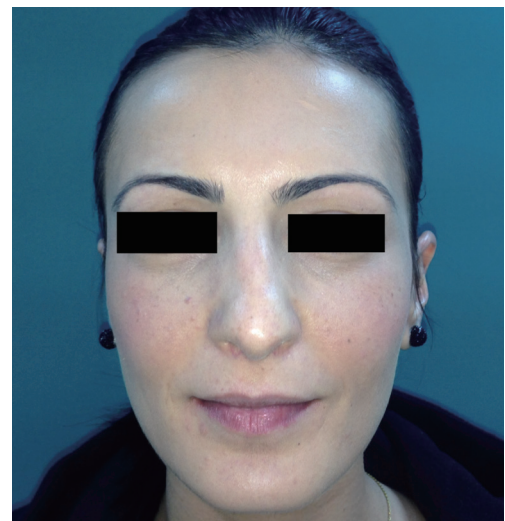

Fig. 1.
Preoperative appearance.