

A Review of Macrodystrophia Lipomatosa: Revisitation

Theddeus OH Prasetyono, Enjeline Hanafi*, Windi Astriana*

Division of Plastic Surgery, Department of Surgery, Cipto Mangunkusumo Hospital/Faculty of Medicine, University of Indonesia, Jakarta, Indonesia

Macrodystrophia lipomatosa (MDL) is a rare congenital non-hereditary disorder that has significant impact on patient morbidity. This study provides a comprehensive review of the natural history, diagnosis, management, and outcomes of the disorder. A literature search in PubMed was conducted to identify cases of MDL from January 1950 to 14 February 2014. After ruling out articles without information related to the management of the disorder, a summary of 32 studies was performed. An additional three cases from the authors are also presented. Based on 57 journal articles and three additional cases from the authors, around 108 cases of MDL were reviewed. Most patients were males who were admitted to a treatment clinic in the first four years of life. The lower extremities were more frequently affected, with unilateral presentation being most common. They commonly underwent a single-staged surgical procedure with follow-up periods ranging from more than one year up to 21 years. Out of 43 cases that underwent surgical procedures, 13 reported no complications, and there were seven cases of esthetic satisfaction and 15 cases of significant functional improvement. Depending on the severity of a patient's condition, the use of non-invasive diagnostic tools should be carefully considered. Surgery might be a better choice of management than observation, taking into account possible future complications in the absence of surgery and the beneficial outcomes of surgical procedures.

Keywords Congenital limb deformities / Fingers / Lower extremity / Upper extremity

Correspondence:

Theddeus OH Prasetyono
Division of Plastic Surgery,
Department of Surgery,
Cipto Mangunkusumo Hospital/
Faculty of Medicine, University of
Indonesia, Medical Staff Building 4th
Floor, Jl. Diponegoro 71 Jakarta 13410,
Indonesia
Tel: +62-817858899
Fax: +62-21-31903152
E-mail: teddyohprasetyono@yahoo.
com

*Research assistant to the first author

This article contains Appendices 1-4.

No potential conflict of interest relevant to this article was reported.

Received: 11 Dec 2014 • Revised: 16 Apr 2015 • Accepted: 23 Apr 2015

pISSN: 2234-6163 • eISSN: 2234-6171 • <http://dx.doi.org/10.5999/aps.2015.42.4.391> • Arch Plast Surg 2015;42:391-406

INTRODUCTION

Macrodystrophia lipomatosa (MDL) is a rare congenital non-hereditary disorder in which a disproportionate overgrowth of fibroadipose tissue manifests as gigantism of a small part or the whole of an extremity(-ies). It causes significant functional and esthetic problems for patients and families. Although its impact on the well-being of patients is significant, not much is known about this disorder. A systematic review of more than 100 studies by Tahiri et al. [1] discussed the diagnostic approaches and

management of 180 cases of MDL. However, the summary could be considered inadequate, because the cases reported were only those involving the median nerve.

In addition to the invasive gold standard of histopathological examination, other non-invasive examinations could help diagnose MDL. Both surgical and non-surgical approaches can be used in the management of MDL, with varying complications and outcomes in different cases [2,3].

To our knowledge, there is currently no study that provides comprehensive guidance on how to diagnose and manage pa-

tients with MDL. The present study provides a comprehensive summary of the disorder in a review format. Furthermore, discussion of diagnosis and management choices of the given cases is included to provide better understanding of the results of the review.

METHODS

A literature search in PubMed was conducted to identify cases of MDL from January 1950 to 14 February, 2014. MDL and macrodactyly were used as the search terms. Studies that fulfilled the inclusion and exclusion criteria were included. The inclusion criterion was all case series and case reports with the diagnosis of MDL. Exclusion criteria were articles with systematic review and literature review, as well as letters to editors. The abstract and full text of each article were obtained and screened by two independent reviewers (E.H. and W.A.). Duplication of cases was prevented by repeated matching by the authors.

An initial literature search revealed a total of 73 articles. Articles without information related to the management of the disorder were excluded, after which a total of 32 studies was obtained that was further appraised by using forms adapted from the Center for Evidence-Based Management [4].

Additionally, a case series of three patients who were enrolled at our hospital unit between January 2013 and December 2013 is also presented in this study. These cases are included in the summary.

Details, such as age, gender, anatomical location and size of affected areas, diagnostic tools used, management, length of fol-

low-up, post-surgery complications, and outcomes were collected as basic data. The data was then simplified into several tables.

Age was defined as the age of the first presentation to the hospital due to MDL. Anatomical location was categorized as unilateral or bilateral and which part(s) of the anatomical area was affected. Management of MDL was divided into surgical (multi-staged, single-staged, or unspecified) and non-surgical. Unspecified surgery was categorized as unspecified when the article did not provide enough information for us to decide, and observation was not a part of this category. Non-surgical management consisted of on-demand and intentional observation. Length of follow-up was defined as the period of time after the first management was implemented until the last time the patient presented for assessment. Post-surgical complication(s) were defined as any mild or severe event related to the affected area after surgery. Finally, outcomes were divided into esthetic and functional. While esthetic outcome is defined subjectively by the patient or parent, the functional outcome is decided objectively by doctors or authors. Significant and fair functional improvements differed in how the surgery affected the patient's daily function. If the surgery had a strong positive impact on the patient's daily activity, improvement was classified as significant. If the changes only had a mild impact, improvement was defined as fair. Improvement was defined as unspecified when there was no information on the function of the affected extremity prior to the surgery.

RESULTS

There were a total of 108 cases of MDL identified from both the

Table 1. Characteristics of patients in the authors' unit

No.	Age (yr)	Gender	Length of follow-up (mo)	Anatomical Location	Size	Diagnostic tools	Management	Complications	Outcome	
									Esthetic	Functional
1	18	Male	14	Calcaneal and Achilles area of the right foot	Right foot shoe size was three sizes higher than the left foot	MRI	Childhood: amputation of 4th and 5th toes. At 18 yr: mass reduction	N/A	Satisfactory	Significant improvement
2	6	Female	3	Second, third, and fourth toes of the left foot	Metatarsal head-to-head size was double that of the normal right foot; third toe was six times the normal length and circumference	MRI	Central ray amputation and soft tissue and bone reduction of the second and fourth rays	Delayed wound healing; healed by skin graft	Satisfactory	Fair improvement
3	14 mo	Male	2	Thumb, index, and thenar area of the right hand	Circumferences were three and four times higher than normal	Plain radiography	Staged mass reduction and joint reconstruction separated by six-month interval	N/A	Satisfactory	Fair improvement

MRI, magnetic resonance imaging; N/A, not available.

57 journal articles obtained from the literature search combined with the three additional cases from the authors. Among these cases, only 43 journal articles contained information about clinical management of MDL. With the addition of three cases from the authors, there were 46 cases that could be reviewed. A summary of these all-inclusive studies is provided in the Appendices (Appendices 1, 2). The details of the three additional MDL cases can be seen in Table 1.

Table 2 [5] describes the clinical characteristics of all the cases, including three cases from the authors. Twenty-three percent of patients admitted were children, particularly in the first four years of life; more than half of the patients were male. Out of 46 patients, 28 underwent a single-staged surgical procedure, 11 had multi-staged surgery, and four patients went through unspecified surgery. Only three patients with two unilateral cases and one bilateral case were under observation alone. Among the 46 cases, only one indicated bilateral involvement, specifically in the upper extremities. The treatment was different for each side in this case; the left side underwent surgery, while the right side was only observed.

The length of follow-up was not provided by most articles. From the available information on follow-up, only nine patients were monitored up to one year, while 13 patients were followed-

up for periods ranging from more than one year up to 21 years. A length of follow-up for more than 21 years occurred in only two patients. After surgery, most patients reported no significant complications and good esthetic and functional outcomes. The unavailability of such data, however, is around 50% among all patients who had surgery. In the patient with bilateral involvement, the operated extremity was performing better functionally compared to the non-operated extremity.

The review also shows that almost 60% of the cases involved the lower extremity (Table 3). The hand and foot were found to be common sites of MDL, with percentages of 54.1% and 64.4%, respectively. MDL affects upper limbs in 31.7% of cases and 5.1% in lower limbs only.

There are several characteristics that describe patients who undergo surgical and non-surgical treatment. A patient could have an amputation if there are severe functional and esthetic disturbances due to MDL. Debulking or reduction is usually performed if nerve and tendon preservation are planned in addition to esthetic preservation. Other types of surgery are performed depending on the condition of the patient. On the other hand, non-surgical cases are divided into observation on demand and intentional observation. Observation on demand occurs in patients who refused surgical treatment, while intentional observation is chosen in the presence of other urgent medical conditions or as decided by the physicians. Local single-digit involvement is said to be an indication for observation due to the principle of digit preservation in reconstruction.

Different radiographic tools are utilized in MDL. Plain radiography (X-ray) can detect any abnormalities in bone, soft tissues, and joints. Magnetic resonance imaging (MRI) can show fat tissue predominance and the condition of nerves and their sheaths. Computed tomography (CT) scans are used to detect proliferation of fat with bone overgrowth. Ultrasonography can be performed to detect any calcification and abnormal blood flow. There are also other additional examinations, such as nerve conduction tests and electromyography that are performed as necessary.

Characteristic	Reported with management (n = 46)	Reported without management (n = 62)	Total (n = 108)
Age on admission (yr)			
0–4	19 (41.3)	6 (9.7)	25 (23.1)
5–9	5 (10.9)	8 (12.9)	13 (12.0)
10–19	6 (13.0)	4 (6.5)	10 (9.3)
20–29	5 (10.9)	0	5 (4.6)
30–39	2 (4.3)	3 (4.8)	5 (4.6)
40–49	5 (10.9)	4 (6.5)	9 (8.3)
≥ 50	3 (6.5)	0	3 (2.8)
No data	4 (8.7)	34 (54.8)	38 (3.5)
Gender			
Male	31 (67.4)	27 (43.5)	58 (53.7)
Female	15 (32.6)	24 (38.7)	39 (36.1)
No data	0	11 (10.2)	11 (10.2)
Management			
Surgical			
Single	28		
Multiple	11		
Unspecified	4		
Non-surgical ^{a)}	4		
Length of follow-up (yr)			
0–1	9		
> 1–20	12		
≥ 21 ^{a)}	3 ^{a)}		
No data	22		

Values are presented as number of cases (%).

^{a)}Bilateral case patient [5].

Value	No. of cases (%)
Upper extremities (n = 41)	
Upper extremities	13 (31.7)
Hand only	23 (56.1)
Unspecified	5 (12.2)
Lower extremities (n = 59)	
Lower extremities	3 (5.1)
Foot only	38 (64.4)
Unspecified	18 (30.5)

DISCUSSION

About 89 years after its first report [6], MDL has become widely known as a disorder of proliferation of mesenchymal and adipose tissue. The affected area grows in a normal pattern or much faster than the unaffected area, causing a gigantic disproportional appearance [7]. In recent years, there have been few articles describing cases diagnosed as MDL.

In this study, we found that the admission with MDL occurs primarily before the age of four. Problems start to surface with the growth of the child. Toddlers are reported to have difficulty in wearing shoes and to sustain repeated injuries, which may affect their daily activities, especially their learning development, social interaction, and self-confidence [2]. Secondary functional problems, such as secondary osteoarthritis and compression of neurovascular elements, usually arise when the patients are older [8]. This is why some patients first present at a later age. Esthetic problems, on the other hand, can begin at any age [2,8-11]. Patients or their parents seek treatment typically due to the cosmetic appearance of the affected area, although functional reasons also play an important role.

MDL can be categorized into static and progressive types. In static MDL, the affected area grows proportionately, while in progressive MDL, disproportionate growth occurs [12]. Some studies have postulated that the growth of the affected area may slow down or cease if patients have finished their growth spurts [8,10,13]. This idea, however, seems more likely to apply to the static type of MDL. As the rest of the body ends its growth, the growth of the affected area may stop as well.

MDL has no gender predominance [14-16]. The difference in the number of males and females with MDL in this study are too insignificant to be considered as predominance. Our study also found that unilateral distribution is common, because bilateral distribution only occurred in three cases. Hand or foot involvement is more common than whole extremities. Specifically, there is a high possibility for the first, second and third digits of the hand or foot to be involved singularly or adjacently. The combination of the second and third digits has the highest frequency (Table 4) [17-20].

The findings may be related to the theory that MDL manifests according to the distribution of the sclerotome [21]; this is a group of mesenchymal cells that gives rise to the skeletal tissue of the body and develops into the vertebrae and ribs [22]. As the little finger is rarely affected (Appendices 3, 4), it is also possible that the distribution is based on the median or plantar nerve innervations.

The diagnosis of MDL is made through clinical presentation and radiographic examination. Many modalities have been re-

Table 4. Digital combinations in macrodystrophia lipomatosa

Value	Hand	Foot	Unspecified extremity	Total
One digit only	10	16	2	28
1st and 2nd digit	5	1	3	9
2nd and 3rd digit	3	6	7	16
3rd and 4th digit	1 ^{a)}	0	2	3
4th and 5th digit	2 ^{a)}	1	0	3
1st, 2nd, and 3rd digit	2	4	1	7
2nd, 3rd, and 4th digit	1	5	2	8
3rd, 4th, and 5th digit	0	0	1	1
1st, 2nd, 3rd, and 4th digit	0	1	1	2
2nd, 3rd, 4th, and 5th digit	0	0	3	3
1st, 2nd, 3rd, 4th, and 5th digit	0	0	1	1
Unspecified digit(s)	12 ^{b)}	7 ^{c)}	0	19
Total	36	41	23	100

Values are presented as number of cases.

Digital combination is adapted from Gupta et al. [17].

^{a)}One bilateral case with information on each side [5]; ^{b)}One bilateral case [18];

^{c)}Two bilateral cases [19,20].

ported to act as adjuncts in confirming the diagnosis, providing histopathological examination could not be performed [11,13,15]. Basic radiographic modalities that have widely been used are X-ray [23-26], MRI [10,16,27-31], CT scan [11,14,32,33], and ultrasonography [2,14,33,34]. Additional examinations, such as nerve conduction tests and electromyography [27,35], may also be performed. In fact, X-ray alone might be sufficient to diagnose MDL. This idea is supported by the presence of cases that used radiography as the single diagnostic tool, including one case from the author. If the extent of the disorder is unclear, or the composition of the macrodactyly tissue is doubtful, an MRI may be performed. Nonetheless, choices of diagnostic modality are made according to the clinical features, the availability of the modality and the goal of the examination.

As discussed previously, the management of MDL depends on age, clinical manifestation, and the extent of the disorder [2,8,36]. It can be divided into non-surgery and surgery. The decision regarding frequency of follow-up observation generally lies with the patients or parents, and with the physicians. Two types of observation are stated: observation on demand and intentional observation. The first type is determined by the patients or parents, while the latter might be led by the physicians. The benefits of observation are still unknown. However, there might be a lower recurrence rate once the patients have had surgery. In the bilaterally affected case report, there was an example of a worse outcome that was related to the decision of observation [5]. The follow-up duration of 42 years resulted in an unspecified functional outcome for the operated limb and a reduced functional outcome for the non-operated limb. The reason behind these

observations was not discussed in the study. Considering the occurrence of such an outcome, it might have been better if the patient had had surgery on both extremities. A suggestion by the first author is that the right non-operated limb should undergo amputations of the third and fourth rays with an additional approach to the little finger, so that the patient could maintain his right hand grasp function. Overall, there is not enough strong evidence to support non-surgical management of MDL.

Surgery is more preferable than non-surgery to manage MDL [5,36]. The type of surgery often performed is amputation, followed by debulking or reduction. These are mostly executed in single-staged surgery. Multi-staged surgery usually occurs in more complex cases with a longer duration of follow-up. This could involve epiphysiodesis, osteotomy, and carpal tunnel release. Epiphysiodesis and osteotomy are performed with an objective to halt the growth of the abnormal limb and correct the deformities caused by disproportionate growth [34,37]. Carpal tunnel release is only performed when the patient complains of pain of the affected area.

Many patients underwent single-staged surgery in this study. It is important to note that these cases might have no follow-up data available, because many of them were presented as case reports or case series. The patients might or might not have presented for subsequent surgery in the future. Despite this, the length of follow-up in this study can be regarded as acceptable, as it covers more than a year. This time may be adequate for complications, both early and late, to surface. Some complications are loss of sensation, under-correction, and skin blackening [2, 9,27]. Loss of sensation can result from the damage from extensive lesions, which need extensive surgery. The risk of complication after extensive surgery is about 30%–50% for nerve injury,

and 33%–60% for recurrence of MDL [8,11]. Our study could not actually give the rate of recurrence of MDL due to the variety of patients' baseline characteristics and different rate of follow-up. Under-correction usually happens when there is an underestimation of the lesion dimension; this can be corrected readily. Skin blackening is caused by injury to the digital arteries [2]. A cautious approach during surgery and proper wound treatment are essential to prevent this. In order to ensure fewer complications, it is reported that ray removal might be a better choice [8]. If in the planning stage it is predicted that the function of the affected limb could not be preserved or that the digit may not function well despite its preservation, then ray amputation could be performed to prevent further complication, such as nerve entrapment, in the future. A suitable example can be observed in the second case given (Fig. 1).

Esthetic outcomes, as mentioned earlier, play an important part in the evaluation of surgery outcomes [10,11]. The satisfaction from the patients or parents may be higher than the physicians' expectation. Drastic changes in the size and shape of the affected area may give an impression that any reduced appearance of the area is good enough. In contrast, significant improvement in functional outcome can be hard to achieve. Retention of the function of the extremity, as well as procurement of appropriate function, depends solely on the surgery process and the severity of the disorder prior to surgery. An algorithm is proposed to guide physicians, who have more limited resources in dealing with MDL in particular (Fig. 2).

In this review, three additional cases are also given (Table 1). The cases consist of two males and one female patient aged 18 years, 14 months, and 6 years, respectively. The age distribution is older than in the other studies; however, the first case had had

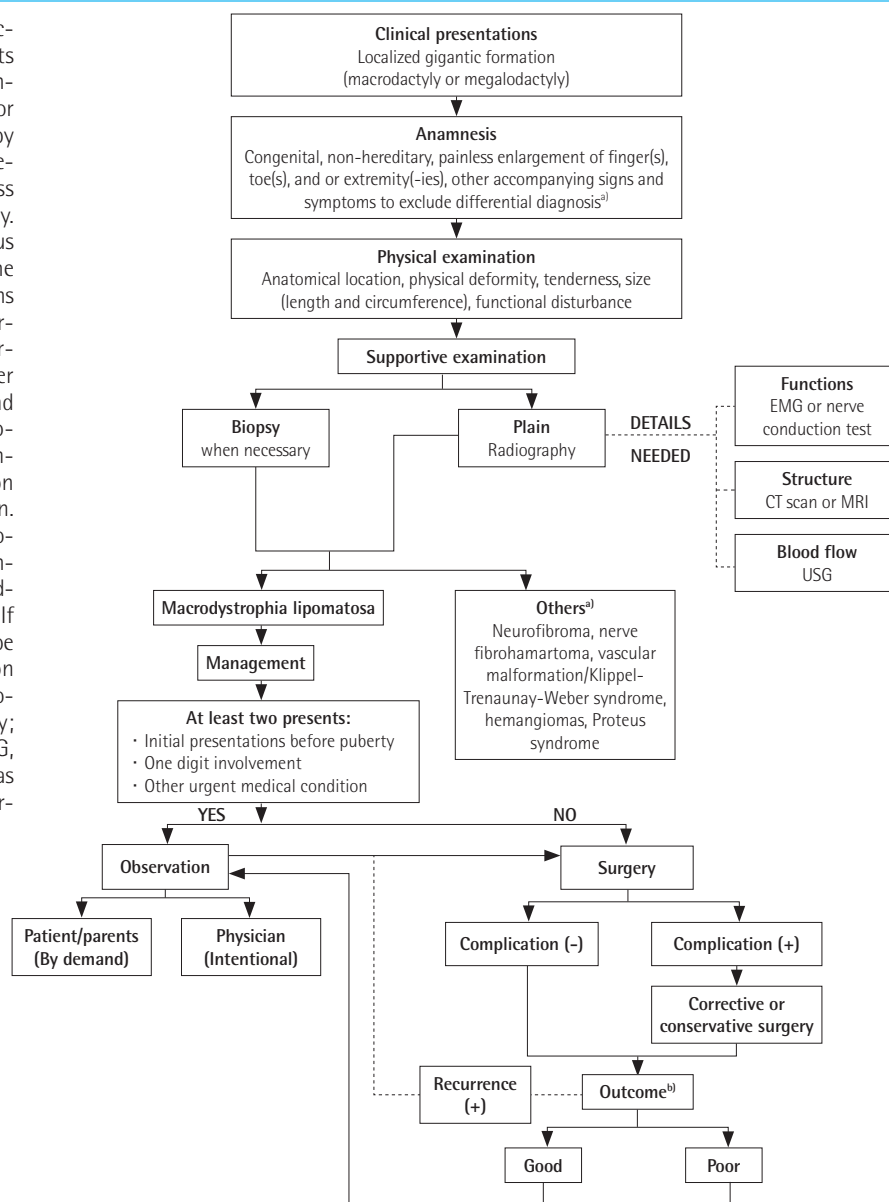
Fig. 1. Presentation of patient no. 2 in the unit

A 6-year-old female presented with a metatarsal head-to-head size that was double that of the normal right foot; her third toe was six times the normal length and circumference (A, B). X-ray indicated an enlargement of the second, third, and fourth digits (C, D).

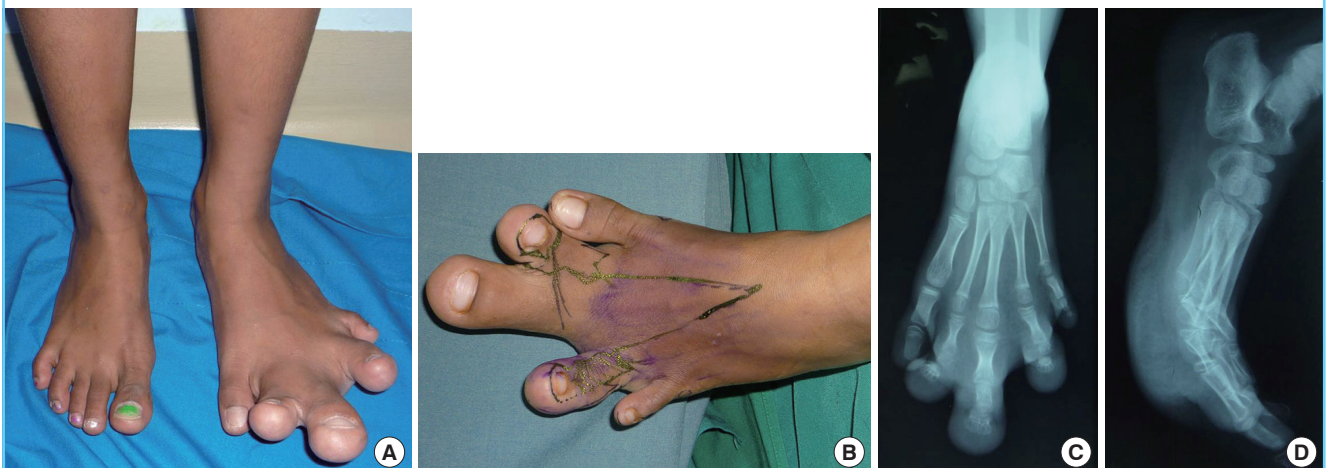

Fig. 2. Algorithm for management of macrodystrophia lipomatosa

This algorithm shows how to manage macrodystrophia lipomatosa (MDL) patients from early consultation to definitive management. Presentations of macrodactyly or megalodactyly should be accompanied by precise anamnesis. It should be asked whether the condition is painful or painless and if it is congenital and/or hereditary. Detailed physical examination should focus on the anatomical location, nature of the physical deformity, tenderness, dimensions of the affected area, and functional disturbances. At the least, X-ray should be performed as a diagnostic test, with further imaging tests performed if necessary and available. When the diagnosis of macrodystrophia lipomatosa is confirmed, management strategies comprise observation only or surgery followed by observation. Presentation of macrodystrophia lipomatosa before puberty, or with single digit involvement, or with concurrent urgent medical conditions calls for observation only. If these conditions are absent, surgery can be performed with subsequent observation for outcome and recurrence. EMG, electromyography; CT, computed tomography; MRI, magnetic resonance imaging; USG, ultrasonography. ^{a)}They usually manifest as macrodactyly without adipose tissue overgrowth; ^{b)}Both esthetic and functional.



surgery in his childhood, and thus the first presenting age was actually younger. The last two cases are also younger; they presented due to cosmetic and functional difficulties. Parents might have sought treatment earlier due to the need for the affected limbs to look 'normal' before the children started school. The distribution of the affected digits in these patients is similar to the findings of the review, which were that MDL occurs in multiple adjacent digits with second digit involvement. After radiographic examinations were performed, surgery planning resulted in single-staged surgery for all patients. However, due to technical reasons during the surgery, the 6-year-old female case received treatment in a multi-staged surgical manner. Joint man-

agement, rather than bony intervention, was performed by rebalancing the joint ligament. Ray amputation in the second case was performed with the consideration of removing ineffective digits to achieve better functional outcome. This decision was also in line with the findings of this review. Furthermore, from all three cases, only one patient had a complication of delayed wound healing. This can be fixed with a skin graft of the area. Impressively, all cases had positive outcomes, which might rationalize the decision of management made by the first author.

There are several limitations to this study. Level of evidence is an important aspect of this study. As it only uses case series and case reports, its evidence level is a four, the lowest level except

for that of an expert opinion. Thus the evidence we present is not as strong as a cohort or case-control study. However, it is difficult to conduct this type of studies in surgical settings due to ethical issues. Thus, this study can be considered sufficiently relevant to be used. Other weaknesses might be a bias during article selection. Incomplete information from the article title and abstract might infer different meanings of the real condition of the patients than can be clearly shown in full-text articles. Additionally, only a single database was used to find the relevant articles. Any studies that were not indexed by the database could have been missed. In addition, the inability to add more cases from the author and new cases from journal articles due to period-related inclusion criteria, might have caused many very recent cases of MDL to be neglected and excluded from this study.

In relation to the diagnosis and management of MDL, this study suggests several things. The use of non-invasive diagnostic tools should be carefully considered, according to the severity of the condition. Surgery might be a better choice of management than observation, taking into account future complications in the absence of surgery and the beneficial outcomes of surgical procedures for patients. Patients should be followed up regularly to determine the incidence of reoccurrence. Although an algorithm is proposed in this study, it has not been tested yet; its accuracy and efficiency might therefore still be questionable.

REFERENCES

1. Tahiri Y, Xu L, Kanevsky J, et al. Lipofibromatous hamartoma of the median nerve: a comprehensive review and systematic approach to evaluation, diagnosis, and treatment. *J Hand Surg Am* 2013;38:2055-67.
2. Sudesh P, Raj N, Kumar R, et al. Macrodystrophia lipomatosa. *Foot (Edinb)* 2012;22:172-4.
3. Cologlu H. A solution for surgical treatment of the combination lipofibromatous hamartoma and macrodystrophia lipomatosa: "vascularised digital nerve flap". *Handchir Mikrochir Plast Chir* 2013;45:39-41.
4. Center for Evidence-Based Management. Critical appraisal for a case study [Internet]. Amsterdam: Netherlands; [cited 2014 Apr 2]. Available from: <http://www.cebma.org/wp-content/uploads/critical-appraisal-question-for-a-case-study.pdf>.
5. van der Meer S, Nicolai JP, Schut SM, et al. Bilateral macrodystrophia lipomatosa of the upper extremities with syndactyly and multiple lipomas. *J Plast Surg Hand Surg* 2011;45:303-6.
6. Feriz H. Macrodystrophia lipomatosa progressiva. *Virchows Arch Pathol Anat Physiol Clin Med* 1925;260:308-68.
7. Rohilla S, Jain N, Sharma R, et al. Macrodystrophia lipomatosa involving multiple nerves. *J Orthop Traumatol* 2012;13:41-5.
8. Khan RA, Wahab S, Ahmad I, et al. Macrodystrophia lipomatosa: four case reports. *Ital J Pediatr* 2010;36:69.
9. Kwon JH, Lim SY, Lim HS. Macrodystrophia lipomatosa. *Arch Plast Surg* 2013;40:270-2.
10. Pandey AK. Magnetic resonance imaging of a case of monomelic macrodystrophia lipomatosa. *Australas Radiol* 2007;51 Suppl:B227-30.
11. Tuzuner T, Parlak AH, Kavak A, et al. A neglected case of macrodystrophia lipomatosa of the foot in an elderly man. *J Am Podiatr Med Assoc* 2005;95:486-90.
12. Barsky AJ. Macroductyly. *J Bone Joint Surg Am* 1967;49:1255-66.
13. Wang YC, Jeng CM, Marcantonio DR, et al. Macrodystrophia lipomatosa. MR imaging in three patients. *Clin Imaging* 1997;21:323-7.
14. Ozturk A, Baktiroglu L, Ozturk E, et al. Macrodystrophia lipomatosa: a case report. *Acta Orthop Traumatol Turc* 2004;38:220-3.
15. Singla V, Virmani V, Tuli P, et al. Case Report: Macrodystrophia lipomatosa: illustration of two cases. *Indian J Radiol Imaging* 2008;18:298-301.
16. D'Costa H, Hunter JD, O'Sullivan G, et al. Magnetic resonance imaging in macromelia and macroductyly. *Br J Radiol* 1996;69:502-7.
17. Gupta SK, Sharma OP, Sharma SV, et al. Macrodystrophia lipomatosa: radiographic observations. *Br J Radiol* 1992;65:769-73.
18. Albright SB, Wolfswinkel EM, Caceres KJ, et al. Bilateral macrodystrophia lipomatosa with syndactyly: a case report and literature review. *Hand Surg* 2013;18:267-72.
19. Aydos SE, Fitoz S, Bokesoy I. Macrodystrophia lipomatosa of the feet and subcutaneous lipomas. *Am J Med Genet A* 2003;119:63-5.
20. Yaghmai I, McKowne F, Alizadeh A. Macroductyly fibrolipomatosis. *South Med J* 1976;69:1565-8.
21. Goldman AB, Kaye JJ. Macrodystrophia lipomatosa: radiographic diagnosis. *AJR Am J Roentgenol* 1977;128:101-5.
22. Mosby I. Mosby's medical dictionary. St. Louis, MO: Mosby; 2009.
23. Moran V, Butler F, Colville J. X-ray diagnosis of macrodystrophia lipomatosa. *Br J Radiol* 1984;57:523-5.
24. Di Ianni F, Di Ianni G, Isidoro C, et al. On a case of "Macrodystrophia lipomatosa". *Eur Rev Med Pharmacol Sci* 1997;1:173-6.
25. Hildebrandt JW, Olson P, Paratainen H, et al. Radiologic case

- study: Macrodystrophia lipomatosa. *Orthopedics* 1993;16:1075-7.
26. Ly JQ, Beall DP. Quiz case. Macrodystrophia lipomatosa. *Eur J Radiol* 2003;47:16-8.
 27. Chiang CL, Tsai MY, Chen CK. MRI diagnosis of fibrolipomatous hamartoma of the median nerve and associated macrodystrophia lipomatosa. *J Chin Med Assoc* 2010;73:499-502.
 28. Soler R, Rodriguez E, Bargiela A, et al. MR findings of macrodystrophia lipomatosa. *Clin Imaging* 1997;21:135-7.
 29. Blacksins M, Barnes FJ, Lyons MM. MR diagnosis of macrodystrophia lipomatosa. *AJR Am J Roentgenol* 1992;158:1295-7.
 30. Boren WL, Henry RE Jr, Wintch K. MR diagnosis of fibrolipomatous hamartoma of nerve: association with nerve territory-oriented macrodactyly (macrodystrophia lipomatosa). *Skeletal Radiol* 1995;24:296-7.
 31. Turkington JR, Grey AC. MR imaging of macrodystrophia lipomatosa. *Ulster Med J* 2005;74:47-50.
 32. Curry NS, Schabel SI, Keuper JT. Computed tomography diagnosis of macrodystrophia lipomatosa. *J Comput Tomogr* 1988;12:295-7.
 33. Upadhyay D, Parashari UC, Khanduri S, et al. Macrodystrophia lipomatosa: radiologic-pathologic correlation. *J Clin Imaging Sci* 2011;1:18.
 34. Viola RW, Kahn A, Pottenger LA. Paraxial macrodystrophia lipomatosa of the medial right lower limb. *J Pediatr Orthop* 1991;11:671-5.
 35. Meyer BU, Roricht S. Fibrolipomatous hamartoma of the proximal ulnar nerve associated with macrodactyly and macrodystrophia lipomatosa as an unusual cause of cubital tunnel syndrome. *J Neurol Neurosurg Psychiatry* 1997;63:808-10.
 36. Watt AJ, Chung KC. Macrodystrophia lipomatosa: a reconstructive approach to gigantism of the foot. *J Foot Ankle Surg* 2004;43:51-5.
 37. Ho CA, Herring JA, Ezaki M. Long-term follow-up of progressive macrodystrophia lipomatosa: a report of two cases. *J Bone Joint Surg Am* 2007;89:1097-102.