

while the sarcoma was being resected. This resulted in a shorter operative time, less blood loss, and a faster postoperative recovery.

Finally, the arc of rotation of the ORAM flap was preferable to that of the ALT flap, which would have required a 'U-turn' to project the flap into the scrotum.

It is critical to repair the fascial defect at and around the deep and superficial ring of the inguinal canal, as this fascia layer reduces the risk of future inguinal hernias. After measuring the fascial defect over the deep inguinal ring (5 × 3 cm), we harvested equal dimensions of the left anterior rectus sheath as part of the myocutaneous flap. This anterior rectus sheath was then used after tunneling the flap to close the fascial defect over the deep inguinal ring, replacing like with like. This avoided the use of a synthetic mesh, which would have carried a risk of implant infection as well as being more expensive. Instead of using a mesh to close inguinal fascial defects of this type, it would be more prudent to make use of the fascial component of the flap to reconstruct such defects.

In conclusion, the contralateral pedicled ORAM flap is an attractive reconstructive option after the radical excision of a spermatic cord liposarcoma.

## References

1. Taylor GI, Corlett R, Boyd JB. The extended deep inferior epigastric flap: a clinical technique. *Plast Reconstr Surg* 1983;72:751-65.
2. Villa M, Saint-Cyr M, Wong C, et al. Extended vertical rectus abdominis myocutaneous flap for pelvic reconstruction: three-dimensional and four-dimensional computed tomography angiographic perfusion study and clinical outcome analysis. *Plast Reconstr Surg* 2011;127:200-9.
3. Koul AR, Nahar S, Prabhu J, et al. Free boomerang-shaped extended rectus abdominis myocutaneous flap: the longest possible skin/myocutaneous free flap for soft tissue reconstruction of extremities. *Indian J Plast Surg* 2011;44:396-404.

## Technical Considerations to Avoid Microvascular Complications during Groin Lymph Node Free Flap Transfer

Pedro Ciudad<sup>1</sup>, Georgios Orfaniotis<sup>1</sup>, Juan Socas<sup>2</sup>, Rory Dower<sup>1</sup>, Kidakorn Kiranantawat<sup>1</sup>, Fabio Nicoli<sup>1</sup>, Stamatis Sapountzis<sup>1</sup>, Michele Maruccia<sup>1</sup>, Hung-Chi Chen<sup>1</sup>

<sup>1</sup>Department of Plastic Surgery, China Medical University Hospital, Taichung, Taiwan; <sup>2</sup>Department of Plastic and Reconstructive Surgery, Indiana University School of Medicine, Indianapolis, IN, USA

**Correspondence:** Hung-Chi Chen  
Department of Plastic Surgery, China Medical University Hospital,  
2 Yuh-Der Road, Taichung 40447, Taiwan  
Tel: +88-6975682158, Fax: +88-6975682158  
E-mail: D19722@mail.cmuh.org.tw

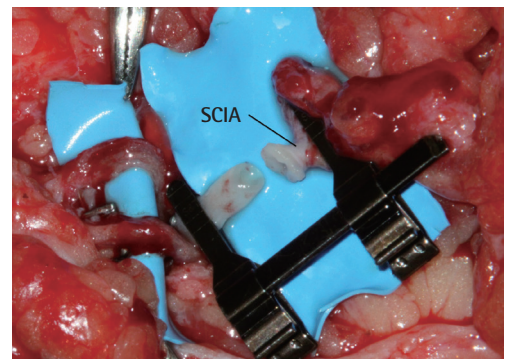
No potential conflict of interest relevant to this article was reported.

Received: 28 May 2015 • Revised: 14 Jun 2015 • Accepted: 15 Jun 2015  
pISSN: 2234-6163 • eISSN: 2234-6171  
<http://dx.doi.org/10.5999/aps.2015.42.5.650> • Arch Plast Surg 2015;42:650-652

Copyright © 2015 The Korean Society of Plastic and Reconstructive Surgeons  
This is an Open Access article distributed under the terms of the Creative Commons Attribution Non-Commercial License (<http://creativecommons.org/licenses/by-nc/3.0/>) which permits unrestricted non-commercial use, distribution, and reproduction in any medium, provided the original work is properly cited.

Groin lymph node free flap (G-LNF) transfer is a well-known technique for the treatment of lymphedema. Despite promising early and long-term results, concerns regarding postoperative donor site lymphedema and adequacy of the G-LNF vessels have limited the popularity of G-LNF transfer amongst microsurgeons.

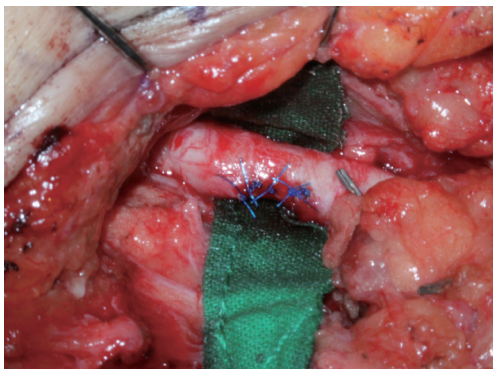
G-LNF can be based either on the superficial circumflex iliac artery (SCIA), the superficial inferior epigastric artery (SIEA), or a small, unnamed medial branch of the femoral artery (MBFA) [1].



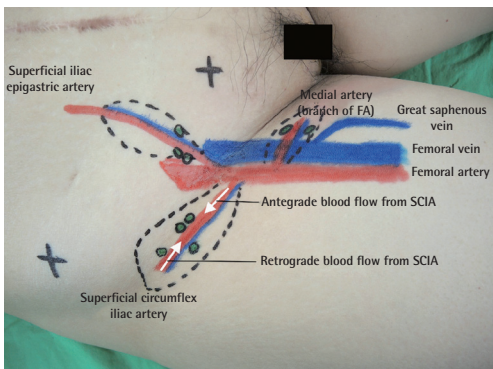
**Fig. 1.**

A patch of the femoral artery was harvested to increase the caliber of the superficial circumflex iliac artery (SCIA).

We have observed some pitfalls with the use of the microsurgical G-LNF that can jeopardize the success rate of this flap. Herein, we share some of the technical considerations that we have found useful in overcoming these problems. They can be summarized as follows: (1) Size discrepancy of artery: The SCIA is well known for having a small diameter and a short pedicle, both of which can cause problems during anastomosis. The sudden change of caliber at the anastomosis site may cause turbulent blood flow, which can predispose the patient to platelet aggregation [2]. This altered vascularity may compromise the functioning of the fine lymphatic structures and lymph nodes of the G-LNF. A number of microsurgical techniques have been developed to address the problem of anastomotic size discrepancy [2]. Our method is to include a small “cuff”



**Fig. 2.** Femoral artery repaired.



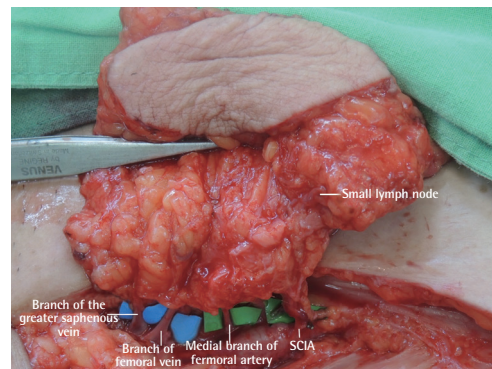
**Fig. 3.** The anatomical landmark shows options in the groin area for the discrepancy in the vascular diameter during groin lymph node free flap transfer. Note also that the vascularized groin lymph node flap could be harvested with retrograde arterial flow and antegrade venous return. FA, femoral artery; SCIA, superficial circumflex iliac artery.

measuring 1–1.2 mm from the femoral artery at the origin of SCIA. This cuff allows us to perform the anastomosis more easily and improves the patency rate of the anastomosis (Fig. 1). The femoral artery is repaired with 5-0 Prolene (Fig. 2).

(2) Alternatives to SCIA: In cases where the SCIA has been found to be unsuitable for microvascular anastomosis, the flap should be re-designed on the basis of the SIEA or MBFA (Fig. 3). It is well established that the groin area has different sub-groups of lymph nodes, and studies have already provided useful anatomical information about the lymph nodes that need to be targeted for vascularized lymph node transfer [3-5]. Therefore, when using the MBFA, care should be taken to avoid harvesting the sentinel lymph nodes in the leg, thereby preserving the lymphatic drainage and avoiding iatrogenic lymphedema, as reported by previous authors [5]. When using the G-LNF, surgeons should take into account the findings of studies conducted on the position of the sentinel nodes draining the lower limb present in this region [4,5].

(3) Retrograde vascularization of SCIA: The lateral part of the SCIA can be used in certain circumstances to vascularize the flap in a retrograde manner. This is particularly useful when the lymph nodes are adjacent to the femoral artery, causing the vascular stump to be too short for anastomosis. It can also be used in the rare situation where the caliber of the SCIA decreases towards its origin from the femoral artery (Fig. 4).

(4) Venous discrepancy: In cases of venous discrepancy, the dissection can be extended to include a branch of the greater saphenous vein or another suitable cutaneous vein with a larger caliber, which can then be used for venous anastomosis.



**Fig. 4.** Different options for the vascular pedicle of the flap on the basis of Fig. 3. SCIA, superficial circumflex iliac artery.

(5) Recipient vein: With respect to the choice of recipient vein(s), we recommend the use of the deep venous system, which is unlikely to be affected during secondary debulking procedures.

The senior author has used the techniques described above, over a 25-year period (1990–2015), with good results and without any problems at the donor site. On the basis of our experience and the findings of the currently available anatomical studies, surgeons can expect to achieve low complication rates and improved outcomes with the use of the groin lymph node free flap.

## References

1. Cheng MH, Chen SC, Henry SL, et al. Vascularized groin lymph node flap transfer for postmastectomy upper limb lymphedema: flap anatomy, recipient sites, and outcomes. *Plast Reconstr Surg* 2013;131:1286-98.
2. Lopez-Monjardin H, de la Pena-Salcedo JA. Techniques for management of size discrepancies in microvascular anastomosis. *Microsurgery* 2000;20:162-6.
3. Zhang H, Chen W, Mu L, et al. The distribution of lymph nodes and their nutrient vessels in the groin region: an anatomic study for design of the lymph node flap. *Microsurgery* 2014;34:558-61.
4. Dayan JH, Dayan E, Kagen A, et al. The use of magnetic resonance angiography in vascularized groin lymph node transfer: an anatomic study. *J Reconstr Microsurg* 2014;30:41-5.
5. Scaglioni MF, Suami H. Lymphatic anatomy of the inguinal region in aid of vascularized lymph node flap harvesting. *J Plast Reconstr Aesthet Surg* 2015;68:419-27.

## Breakthrough Technique for Free Tissue Transfer of Poorly Vascularized Lower Extremity: Arteriovenous Loop Revisited

Hee-Eun Cho, Si-Gyun Roh, Nae-Ho Lee, Kyung-Moo Yang

Department of Plastic and Reconstructive Surgery, Chonbuk National University Hospital, Jeonju, Korea

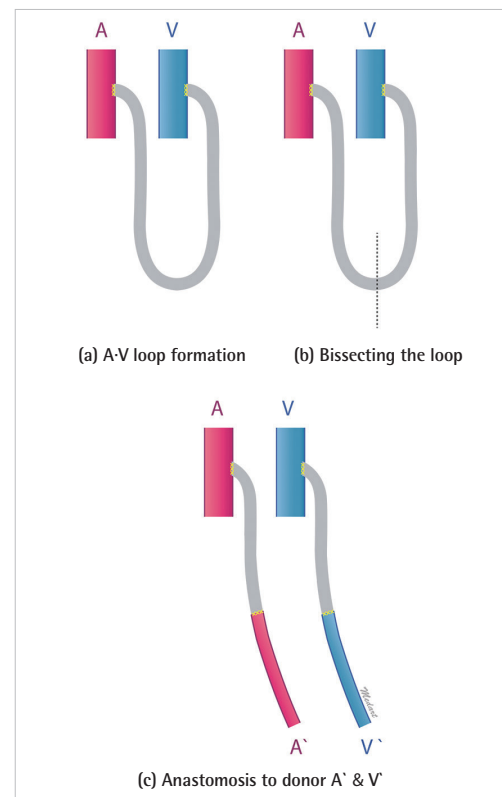
**Correspondence:** Si-Gyun Roh  
Department of Plastic and Reconstructive Surgery, Chonbuk National University Hospital, Chonbuk National University Medical School, 20 Geonjiro Deokjin-gu, Jeonju 54907, Korea  
Tel: +82-63-250-1860, Fax: +82-63-250-1866, E-mail: pssroh@jbnu.ac.kr

No potential conflict of interest relevant to this article was reported.

Received: 28 Feb 2015 • Revised: 30 Mar 2015 • Accepted: 30 Mar 2015  
pISSN: 2234-6163 • eISSN: 2234-6171  
<http://dx.doi.org/10.5999/aps.2015.42.5.652> • Arch Plast Surg 2015;42:652-655

Copyright © 2015 The Korean Society of Plastic and Reconstructive Surgeons  
This is an Open Access article distributed under the terms of the Creative Commons Attribution Non-Commercial License (<http://creativecommons.org/licenses/by-nc/3.0/>) which permits unrestricted non-commercial use, distribution, and reproduction in any medium, provided the original work is properly cited.

Severely damaged lower extremities with poor vessels are challenging situations for reconstructive surgeons. Patients with such extremities may have problems resulting from an inadequacy of recipient vessels caused by factors such as arterial occlusive disease or



**Fig. 1.** Schematic representation of an arteriovenous loop (A-V loop).