

Clinical Approaches to Vascular Anomalies of the Lip

Jeong Yeop Ryu¹, Joon Seok Lee¹, Jeong Woo Lee¹, Kang Young Choi¹, Jung Dug Yang¹,
Byung Chae Cho¹, Seok-Jong Lee^{2,3}, Jong Min Lee^{2,4}, Seung Huh^{2,5}, Ho Yun Chung^{1,2}

¹Department of Plastic and Reconstructive Surgery, ²Vascular Anomaly Center, Departments of ³Dermatology, ⁴Radiology, and ⁵Vascular Surgery, Kyungpook National University School of Medicine, Daegu, Korea

Background The incidence of vascular anomalies in the head and neck is higher than in the extremities. It is especially common for vascular anomalies to involve the lip. The lips are a functionally and aesthetically important component of the head and neck area. A retrospective analysis of data from our vascular anomaly center was performed in order to understand the characteristics and treatment requirements of vascular anomalies of the lip and to establish which treatments are likely to lead to the best outcomes.

Methods A retrospective review was performed of the medical records of patients diagnosed with vascular anomalies of the upper or lower lip from January 2001 to September 2013. Using clinical photographs, radiologic findings, and patient records, the diagnosis of each case and the location of the vascular anomaly were recorded, along with information about treatment and follow-up.

Results A total of 1,606 patients were diagnosed with vascular anomalies over this time period, of whom 127 (7.9%) were found to have vascular anomalies in the lip only. Surgical treatment with or without embolization, sclerotherapy, laser therapy, medication only, and observation were the treatment strategies adopted in these cases.

Conclusions Vascular anomalies of the lip should be diagnosed accurately. Radiologic diagnosis played a crucial role in treatment planning, and several techniques were used to treat vascular anomalies of the lip. When surgical excision is indicated for the correction of vascular anomalies of the lip, the aesthetic and functional characteristics of the lip should be considered.

Keywords Vascular diseases / Lip / Plastics

Correspondence: Ho Yun Chung
Department of Plastic and Reconstructive Surgery, Kyungpook National University School of Medicine, 130 Dongdeok-ro, Jung-gu, Daegu 41944, Korea
Tel: +82-53-420-5692
Fax: +82-53-425-3879
E-mail: chunghoyun@gmail.com

This research was supported by the Basic Science Research Program of the National Research Foundation of Korea (NRF), funded by the Ministry of Education (NRF-2014R1A1A4A01009584).

No potential conflict of interest relevant to this article was reported.

Received: 21 Mar 2015 • Revised: 19 Jun 2015 • Accepted: 19 Jun 2015

pISSN: 2234-6163 • eISSN: 2234-6171 • <http://dx.doi.org/10.5999/aps.2015.42.6.709> • Arch Plast Surg 2015;42:709-715

INTRODUCTION

Vascular anomalies are caused by various soft-tissue, skin, and mucosal abnormalities of vascular development. Mulliken and Glowacki [1] developed the current classification of vascular

anomalies. They suggested a classification based on the biological characteristics, clinical features, and histological features of the anomalies, and the International Society for the Study of Vascular Anomalies established the current classification system based on their suggestions.

Vascular anomalies can occur throughout the body, but are more common in the head and neck than in the extremities [2]. Vascular anomalies in the head and neck frequently involve the lips, which are important from a functional and aesthetical perspective. Moreover, vascular anomalies occur more frequently in the lips than in any other single area of the body. The lips hold food while an individual eats and allow for proper pronunciation, together with the tongue, cheek, and palate. Well-paired lips improve one’s overall facial appearance. Thus, vascular anomalies of the lips can affect the facial anatomy and result in anatomical distortions, depending on the degree of severity.

In light of the functional and aesthetic importance of the lips, we conducted this study to analyze vascular anomalies of the lips based on a review of patient records.

METHODS

In this retrospective study, we screened patients who were admitted to our vascular anomaly center between January 2001 and September 2013, and included all patients who were diagnosed with vascular anomalies of the upper or lower lip. Patients with vascular anomalies showing wide involvement of the cheek or chin in addition to the lip were excluded from the study.

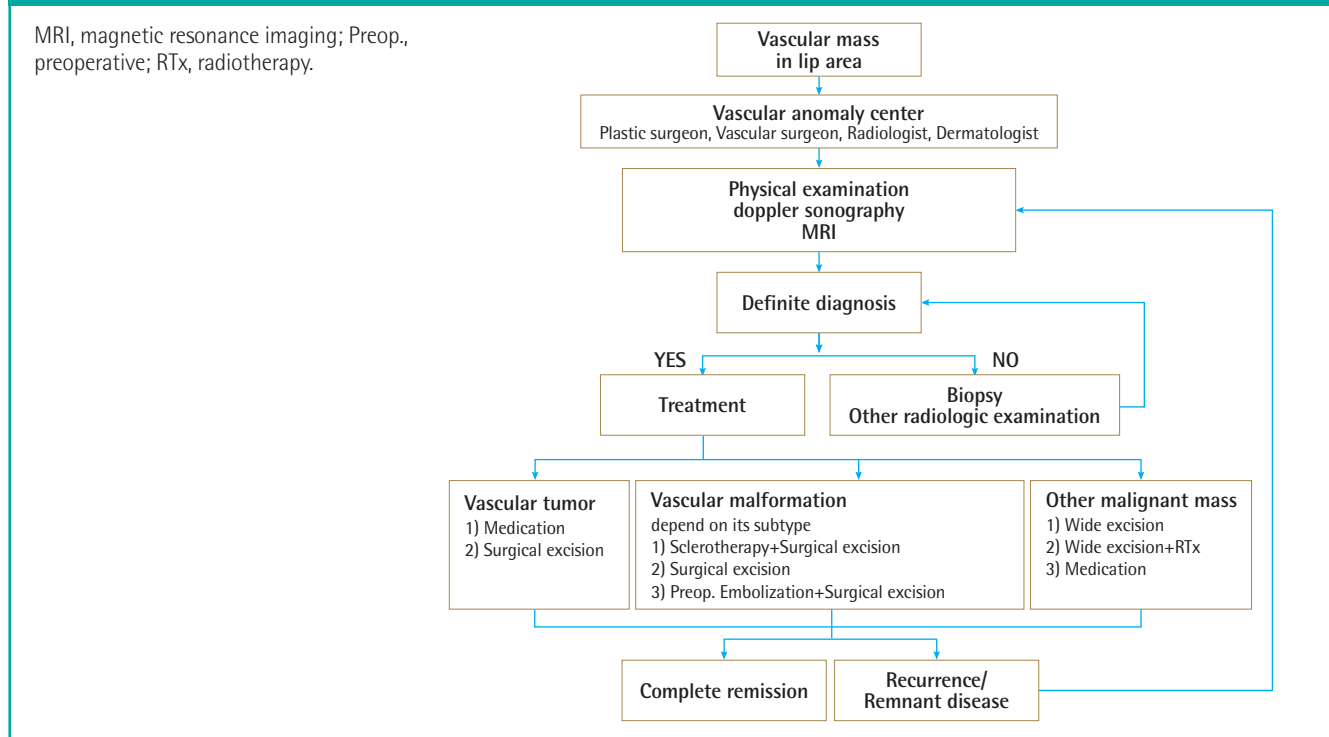
The clinical photographs and radiologic findings of each patient were analyzed, along with the location and diagnosis of the

vascular anomaly.

A team of plastic surgeons, dermatologists, radiologists, and vascular surgeons jointly collected patient histories and performed physical examinations, determined the vascular anomaly subtype using Doppler ultrasonography, and assessed the extent of the lesion using magnetic resonance imaging (MRI). Once the diagnosis was established, the optimal treatment was determined through discussion among the providers in the vascular anomaly center. When surgery was performed, histological findings were confirmed through biopsy [3]. Treatment outcomes were continuously assessed, and treatment was repeated when necessary.

Treatment was administered according to the subtype of vascular anomaly. Surgical excision with or without embolization, sclerotherapy, laser therapy, medication only, and observation were employed to treat vascular anomalies. Combined treatment was defined as the simultaneous performance of preoperative embolization and surgical excision, and multiple treatment was defined as the performance of sclerotherapy, medication, and surgical excision at different time points. Patients received multiple treatment in cases involving postoperative marginal remission or recurrence, as noted through observational monitoring. The outcomes were reviewed, and were the basis for formulation of an algorithm for the clinical treatment of vascular anomalies (Fig. 1).

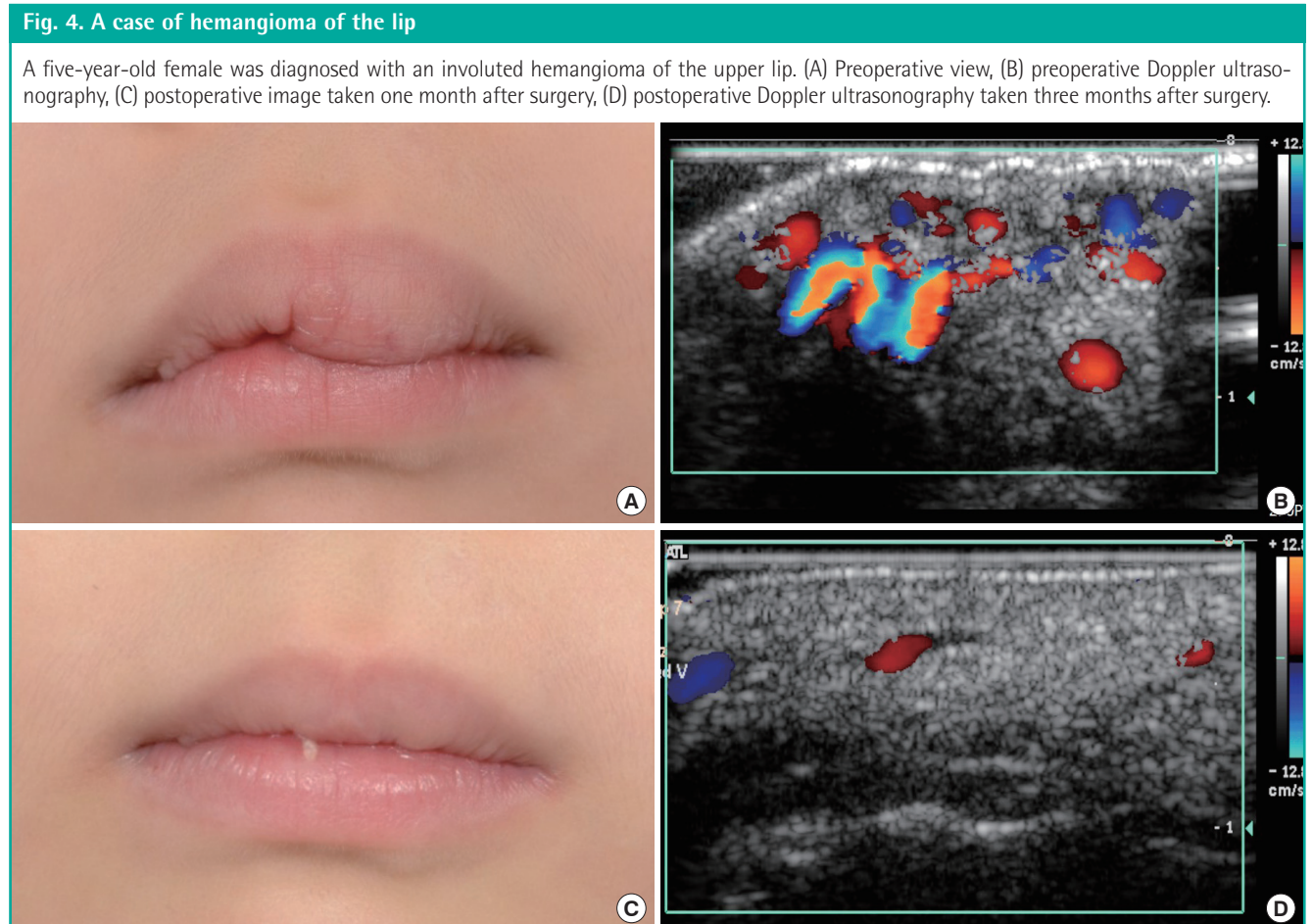
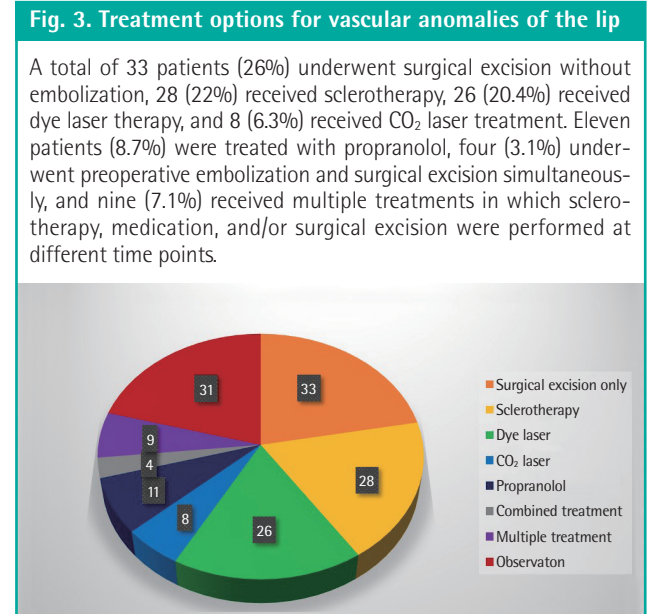
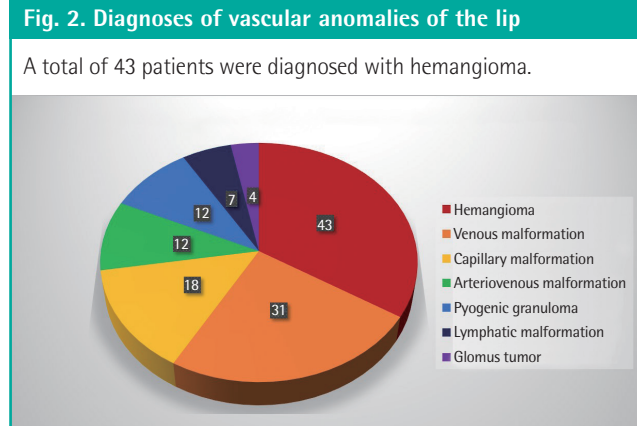
Fig. 1. Treatment algorithm for vascular anomalies of the lip



RESULTS

A total of 1,606 patients were diagnosed with vascular anomalies in our vascular anomaly center. Of these patients, 127 (7.9%) were diagnosed with a vascular anomaly of the lip. The average age of patients with a vascular anomaly of the lip was 27.6 ± 20.99 years (range, 10 months–73 years). Forty-nine of the patients (38.6%) were male and 78 (61.4%) were female. The average

follow-up duration was 15.05 ± 25.84 months (range, 1–89 months). The anomaly was in the lower lip in 62 patients (49%), the upper lip in 45 patients (35%), and both lips in 20 patients (16%).



It was on the left side of the lip in 67 patients (52.7%), the right side of the lip in 35 patients (27.5%), and both sides of the lip in 25 patients (19.8%).

A total of 43 patients were diagnosed with hemangioma, 31 with venous malformation, 18 with capillary malformation, 12 with arteriovenous malformation, 12 with pyogenic granuloma, 7 with lymphatic malformation, and 4 with a glomus tumor (Fig. 2).

A total of 33 patients (26%) underwent surgical excision without embolization, 28 (22%) received sclerotherapy, 26 (20.4%) received dye laser treatment, and 8 (6.3%) received CO₂ laser treatment. Eleven patients (8.7%) received treatment with propranolol, four patients (3.1%) received both preoperative embolization and surgical excision, and nine patients (7.1%) received multiple treatments, in which sclerotherapy, medication, and/or surgical excision were performed at different times. Of all patients 31 patients showed mild symptoms and were observed (Fig. 3). In 74.8% of the patients, treatment resulted in

nearly complete remission, and 8.3% experienced recurrence and required other procedures, such as sclerotherapy or additional surgical excision. In addition, 15.4% of patients showed remission of approximately 50% of the original vascular anomaly, and 1.5% were lost to follow-up or showed little effect from treatment.

Case 1

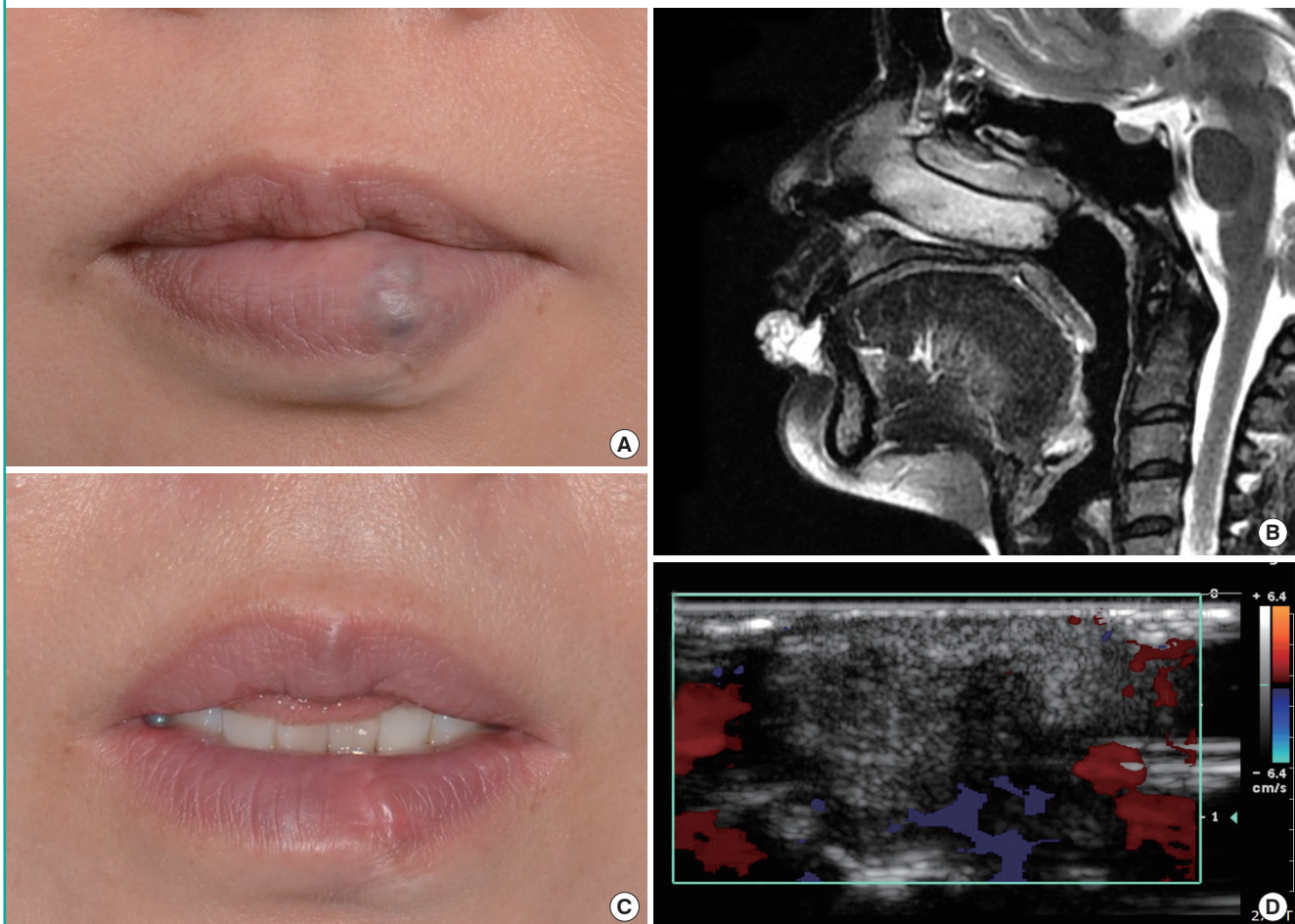
A five-year-old female was diagnosed with an involuted hemangioma of the upper lip. After diagnosis using preoperative Doppler ultrasonography, surgical excision was performed. Subsequently, we observed a satisfactory lip appearance during follow-up and confirmed near-total remission of the lesion on postoperative Doppler ultrasonography (Fig. 4).

Case 2

A 43-year-old woman was diagnosed with a venous malformation of the lower lip. We were able to diagnose venous malfor-

Fig. 5. A case of venous malformation of the lip

A 43-year-old woman was diagnosed with a venous malformation of the lower lip. (A) Preoperative view, (B) preoperative magnetic resonance imaging, (C) postoperative view five months after surgery, (D) postoperative Doppler ultrasonography taken five months after surgery.



mation with a pathological venous chamber on preoperative Doppler ultrasonography, and we confirmed the extent of the lesion on MRI. Surgical excision was performed because the lesion was well localized, and we found that the appearance of the lip improved after surgery. We also confirmed the remission of most lesions on postoperative Doppler ultrasonography (Fig. 5).

Case 3

A six-year-old male was diagnosed with an arteriovenous malformation of the lower lip. Arteriovenous malformation with arteriovenous shunt flow was diagnosed on preoperative Doppler ultrasonography, and the extent of the lesion was confirmed on MRI. We performed sclerotherapy since the nidus of the arteriovenous malformation was not localized. The appearance of the lip improved after surgery and we confirmed the remission of most lesions on postoperative Doppler ultrasonography (Fig. 6).

DISCUSSION

The lip has special anatomical characteristics, such as the white line, white skin roll, red line, vermilion, and Cupid's bow [4].

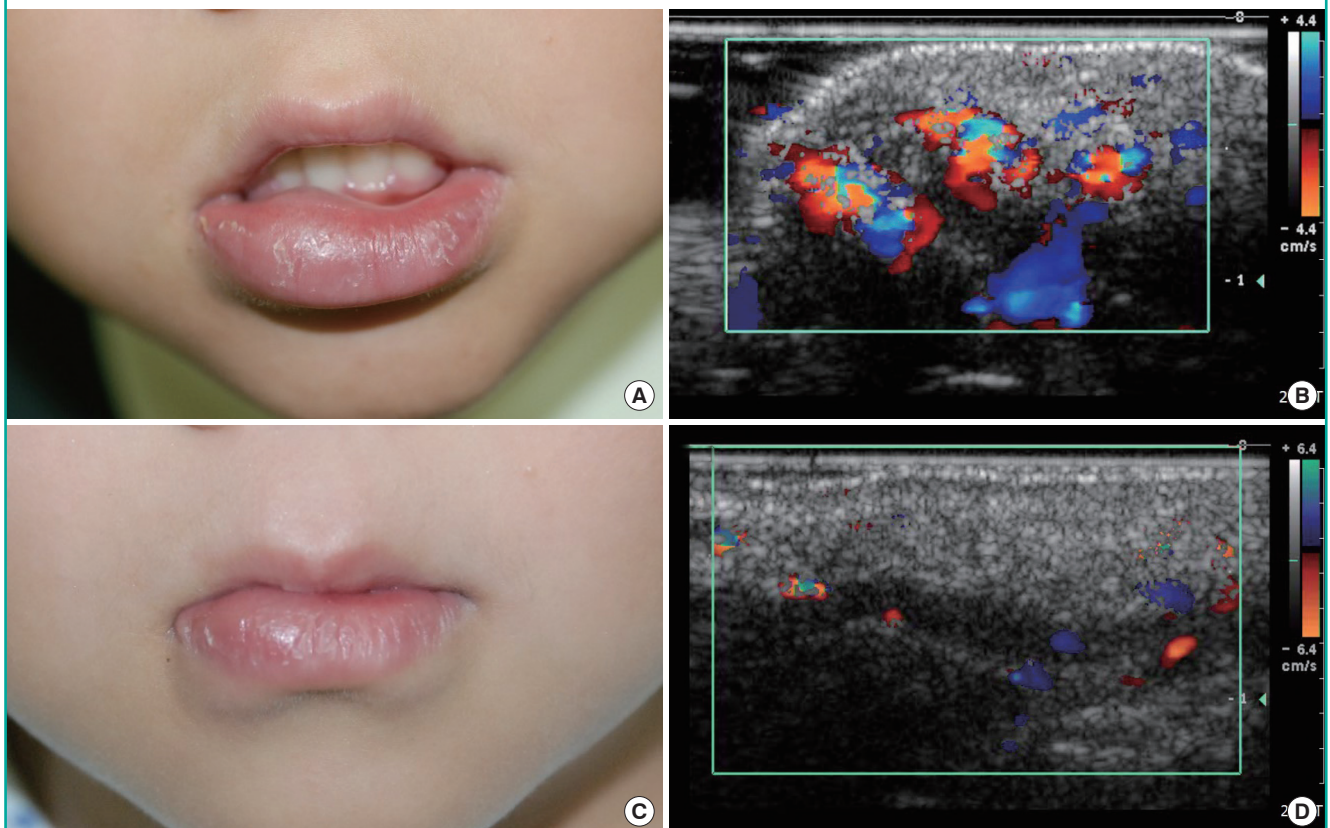
The diagnosis of vascular anomalies that can affect such features is very important. First, the vascular anomaly subtype should be diagnosed using Doppler ultrasonography, and the extent of the lesion must be determined by MRI in order to guide the direction of treatment.

Various masses can develop on the lips, including malignancies and neurologic tumors, such as neurofibromas, as well as vascular tumors and malformations. In our experience, it was very helpful to exchange opinions with specialists from other fields when assessing the results of one or more types of radiologic examination; moreover, it was useful to finalize the diagnosis through examination *via* various perspectives of each specialist in the vascular anomaly team. In occasional cases where the diagnosis was difficult or uncertain, a definitive diagnosis was made through biopsy (Fig. 1).

The vascular anomaly team usually discussed the physical examination and radiologic findings to arrive at a diagnosis. However, some cases involved small anomalies and in some cases, we encountered difficulty with radiologically diverse diagnoses—for instance, what was observed as a glomus tumor in one of our cases appeared as hypervascularity on ultrasound, while exhibit-

Fig. 6. A case of arteriovenous malformation of the lip

A six-year-old male was diagnosed with an arteriovenous malformation of the lower lip. (A) Preoperative view, (B) preoperative Doppler ultrasonography, (C) postoperative image taken one year after surgery, (D) postoperative Doppler ultrasonography taken one year after surgery



ing a characteristic pattern of enhancement on T1 contrast and a high T2 signal on MRI. Hence, algorithms were formulated in order to determine when a biopsy was necessary for a definitive diagnosis [3].

The most frequent diagnosis in this study was hemangioma. Venous malformation was the second most frequent, followed by capillary malformation and arteriovenous malformation. In fact, hemangioma is the most common tumor of infancy, and 65% of such cases of hemangioma involve the head and neck region [5]. Hemangioma can be divided into two subtypes based on histological characteristics: hemangioma of infancy and congenital hemangioma. Hemangioma is caused by vascular endothelial cell hyperplasia, the cause of which is not yet clearly understood. Propranolol is commonly administered to treat cases of hemangioma before involution [6,7], and surgical excision or sclerotherapy is considered after involution.

Venous malformation occurs due to errors in vascular morphogenesis. Various types of venous malformation occur, ranging from small and well-localized masses to diffuse malformations. According to Boon et al. [8], 47% of cases of venous malformation occur in the head and neck region, 40% on the extremities, and 13% on the trunk. Furthermore, venous malformation is typically sporadic, and 90% of cases show a solitary lesion [9]. Venous malformation also occurs on the lip, presenting as a solitary lesion, and proper diagnosis and treatment are needed in such cases. Sclerotherapy is the first choice for the treatment of venous malformation, but surgical excision may be performed in cases where the lesion is small, solitary, and well localized.

Capillary malformation is a vascular malformation once known as a port wine stain that can occur throughout the body. It can be well localized or extensive. Pulsed-dye laser treatment is the first-line treatment for capillary malformation, although CO₂ laser treatment can be also effective. In particular, since pulsed-dye laser treatment is known to be more effective in treating capillary malformation in the head and neck region than in the extremities [10-12], pulsed-dye laser treatment is a natural choice for capillary malformations of the lip. Surgical excision can be performed in a limited number of cases where the lesion is small and well localized. Arteriovenous malformation is caused by direct blood shunting from an artery to a vein due to the absence of a capillary bed. The artery and vein can be directly connected by a fistula or indirectly connected by an abnormal vessel channel termed a nidus. This occurs frequently in the central nervous system, and the most common extracranial site is the head and neck [13,14]. Therefore, arteriovenous malformation is commonly observed on the lip, and a palpable thrill or bruit may exist. Arteriovenous malformation of the lip is also

diagnosed using Doppler ultrasonography and MRI, after which a treatment plan is proposed. The main options for the treatment of arteriovenous malformation are surgical excision with or without preoperative embolization and sclerotherapy.

Indications for the surgical excision of vascular anomalies of the lip must be strictly applied. Surgical excision should be considered with care, because the lip has a diverse and unique anatomical structure, as discussed above, and damage to these structures during excision may result in aesthetic problems [15]. Therefore, surgical excision of vascular anomalies should ideally be performed only for small, well-localized, single lesions. For multiple or non-localized lesions, sclerotherapy, embolization, and medical therapy are recommended over surgical excision. In addition, surgically managed malignancies require flap coverage after complete resection and wide excision. Moreover, aesthetic outcomes are important when dealing with vascular anomalies, especially in the lip, which is visible and has a complex anatomy.

Of particular note is the fact that problems such as bleeding may occur in cases of vascular malformations, depending on the pattern of flow. Accordingly, the correct deployment of preoperative embolization is crucial for reducing morbidity. Moreover, because hematomas can often occur following surgery for general vascular anomalies, rigorous control of bleeding should be implemented. Since wide excisions involving the lips can have negative aesthetic and functional impacts, various adjuvant therapies (e.g., sclerotherapy, laser therapy, medication, etc.) should be used whenever possible, and especially when it is essential to minimize the extent of surgical excision.

Moreover, considering the common recurrence of vascular anomalies and invisible pathological lesions, complete resection is not guaranteed, so nonsurgical treatment is more practical. If nonsurgical treatment only leads to a small volume reduction in soft-tissue hypertrophy caused by a vascular anomaly, surgery can be performed after nonsurgical debulking treatment.

In conclusion, it is important to accurately diagnose vascular anomalies of the lip area through a radiologic work-up, as well as by taking a patient history and performing a physical examination. Treatment options include surgical excision, radiological intervention, laser therapy, and medical treatment. The unique anatomical characteristics of the lips should be considered when performing surgical excisions, which should be carried out according to strict indications.

REFERENCES

1. Mulliken JB, Glowacki J. Hemangiomas and vascular malformations in infants and children: a classification based on

- endothelial characteristics. *Plast Reconstr Surg* 1982;69:412-22.
2. Buckmiller LM, Richter GT, Suen JY. Diagnosis and management of hemangiomas and vascular malformations of the head and neck. *Oral Dis* 2010;16:405-18.
 3. Frey JD, Levine PG, Darvishian F, et al. Angiosarcoma of the breast masquerading as hemangioma: exploring clinical and pathological diagnostic challenges. *Arch Plast Surg* 2015;42:261-3.
 4. Neligan P, Rodriguez ED, Losee JE. *Plastic surgery*. New York: Elsevier Saunders; 2013.
 5. O TM, Scheuermann-Poley C, Tan M, et al. Distribution, clinical characteristics, and surgical treatment of lip infantile hemangiomas. *JAMA Facial Plast Surg* 2013;15:292-304.
 6. Izadpanah A, Izadpanah A, Kanevsky J, et al. Propranolol versus corticosteroids in the treatment of infantile hemangioma: a systematic review and meta-analysis. *Plast Reconstr Surg* 2013;131:601-13.
 7. Szychta P, Stewart K, Anderson W. Treatment of infantile hemangiomas with propranolol: clinical guidelines. *Plast Reconstr Surg* 2014;133:852-62.
 8. Boon LM, Mulliken JB, Enjolras O, et al. Glomuvenous malformation (glomangioma) and venous malformation: distinct clinicopathologic and genetic entities. *Arch Dermatol* 2004;140:971-6.
 9. Limaye N, Wouters V, Uebelhoer M, et al. Somatic mutations in angiopoietin receptor gene TEK cause solitary and multiple sporadic venous malformations. *Nat Genet* 2009;41:118-24.
 10. van der Horst CM, Koster PH, de Borgie CA, et al. Effect of the timing of treatment of port-wine stains with the flashlamp-pumped pulsed-dye laser. *N Engl J Med* 1998;338:1028-33.
 11. Tan OT, Sherwood K, Gilchrist BA. Treatment of children with port-wine stains using the flashlamp-pulsed tunable dye laser. *N Engl J Med* 1989;320:416-21.
 12. Jasim ZF, Handley JM. Treatment of pulsed dye laser-resistant port wine stain birthmarks. *J Am Acad Dermatol* 2007;57:677-82.
 13. Gomes MM, Bernatz PE. Arteriovenous fistulas: a review and ten-year experience at the Mayo Clinic. *Mayo Clin Proc* 1970;45:81-102.
 14. Mulliken JB, Fishman SJ, Burrows PE. Vascular anomalies. *Curr Probl Surg* 2000;37:517-84.
 15. Kim Y, Oh SJ, Lee J, et al. Surgical treatment of dermatomal capillary malformations in the adult face. *Arch Plast Surg* 2012;39:126-9.