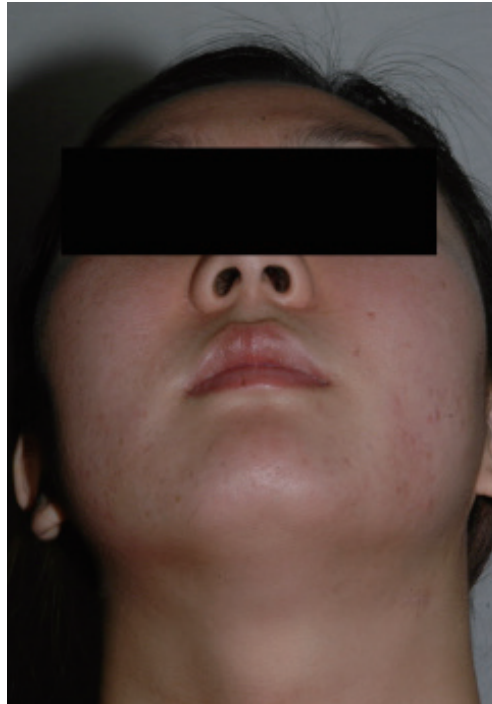

**Fig. 5.**  
The patient shows no swelling three years after the operation.

functions, surgical treatment is indicated [5].

The pathogenesis of peripheral osteoma has not been elucidated, but three hypotheses can be proposed according to its cause. First, the developmental theory suggests that peripheral osteomas result from developmental abnormalities, but this is not convincing because most patients have passed their growth phase. Second, the neoplastic theory contradicts the fact that osteoma proliferates extremely slowly. Third, the reactive theory can explain the case of osteoma that occurs after trauma. The subperiosteal hematic extravasation caused by the injury could have facilitated neoplastic degeneration of the injured tissues [4].

We report here a case of osteoma in the mandibular angle. As osteomas can induce clinical symptoms such as facial asymmetry and pain, clinicians must carefully conduct physical examinations during patients' preliminary medical examination. Diagnosis can be made according to the results of preoperative evaluation and appropriate imaging tests, which can be the foundation for surgical planning. Through histological examination, and regular clinical and imaging follow-up after surgery, full recovery can be achieved. We believe that this study can be helpful for clinicians and researchers investigating facial osteoma.

## References

1. Matteson SR. Oral radiology: benign tumors of the jaws. In: White SC, Pharoah MJ, editors. *Oral radiology: principles and interpretation*. 6th ed. Toronto: Mosby; 2009. p. 392-3.
2. Durao AR, Chilvarquer I, Hayek JE, et al. Osteoma of the zygomatic arch and mandible: report of two cases. *Rev Port Estomatol Cir Maxilofac* 2012;53:103-7.
3. Mittal A, Iyer N. Large peripheral osteoma of the mandible. *Oral Radiology* 2008;24:39-41.
4. Rodriguez Y Baena R, Rizzo S, Fiandrino G, et al. Mandibular traumatic peripheral osteoma: a case report. *Oral Surg Oral Med Oral Pathol Oral Radiol Endod* 2011;112:e44-8.
5. Han BL, Shin HS. Alternative treatment of osteoma using an endoscopic holmium-YAG laser. *Arch Plast Surg* 2012;39:422-5.

## Intercostal Nerve Schwannoma Encountered during a Rib-Latissimus Dorsi Osteomyocutaneous Flap Operation

Kwang Seog Kim, Seung Ryeol Ji, Hong Min Kim, Yu Jin Kwon, Jae Ha Hwang, Sam Yong Lee

*Department of Plastic and Reconstructive Surgery, Chonnam National University Medical School, Gwangju, Korea*

**Correspondence:** Kwang Seog Kim  
Department of Plastic and Reconstructive Surgery, Chonnam National University Medical School, 42 Jebong-ro, Dong-gu, Gwangju 61469, Korea  
Tel: +82-62-220-6363, Fax: +82-62-227-1639  
E-mail: pskim@chonnam.ac.kr

This article was presented at the 70th Congress of The Korean Society of Plastic and Reconstructive Surgeons on November 9–11, 2012, in Seoul, Korea.

No potential conflict of interest relevant to this article was reported.

Received: 18 Jun 2015 • Revised: 10 Jul 2015 • Accepted: 21 Jul 2015  
pISSN: 2234-6163 • eISSN: 2234-6171  
<http://dx.doi.org/10.5999/aps.2015.42.6.800> • Arch Plast Surg 2015;42:800-802

Copyright © 2015 The Korean Society of Plastic and Reconstructive Surgeons  
This is an Open Access article distributed under the terms of the Creative Commons Attribution Non-Commercial License (<http://creativecommons.org/licenses/by-nc/3.0/>) which permits unrestricted non-commercial use, distribution, and reproduction in any medium, provided the original work is properly cited.

Schwannomas are benign, slow-growing tumors that arise from the Schwann cells of peripheral nerve sheaths and are also known as neurilemmomas or

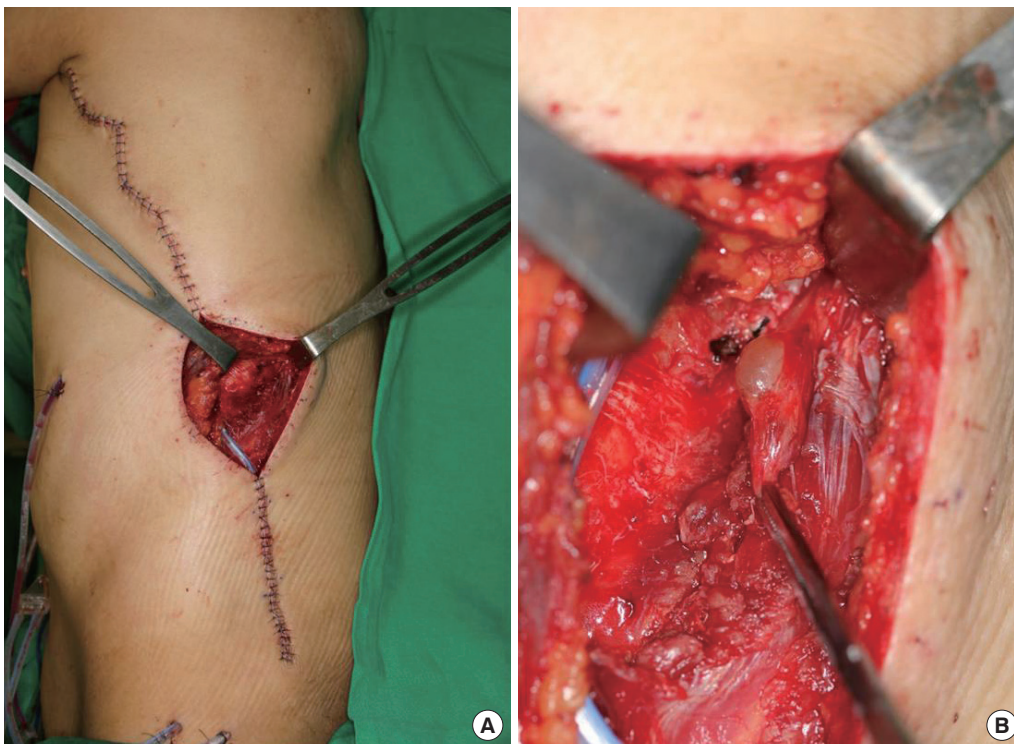
neurinomas. These tumors are covered with a well-demarcated capsule and commonly measure 2–4 cm in diameter. They frequently occur in the head and neck or in the extremities. The lesions themselves do not cause an inflammatory reaction, and patients usually present when these lesions compress the associated peripheral nerve and cause sensory or motor issues secondary to neuropathy. Schwannomas do not have a predilection for sex or ethnicity, but tend to develop between the second and fifth decades of life. Surgical resection is curative, and the possibility of recurrence or malignant transformation is considered extremely low [1,2]. Schwannomas of the intercostal nerve are extremely rare with few cases of large or symptomatic lesions reported in the literature. No intercostal schwannomas have been reported as an incidental finding. Here, we report a small intercostal schwannoma found during a chest wall reconstruction.

A 58-year-old male patient with a sternal mass underwent excisional biopsy of a sternal lesion. The mass was found to be a chondrosarcoma on histopathology, and the patient subsequently underwent a secondary operation for wide resection and reconstruction of the chest wall defect. In the operating room, the sternal mass was resected en bloc with a wide surgical margin. In order to restore the resulting chest wall defect, a composite island flap

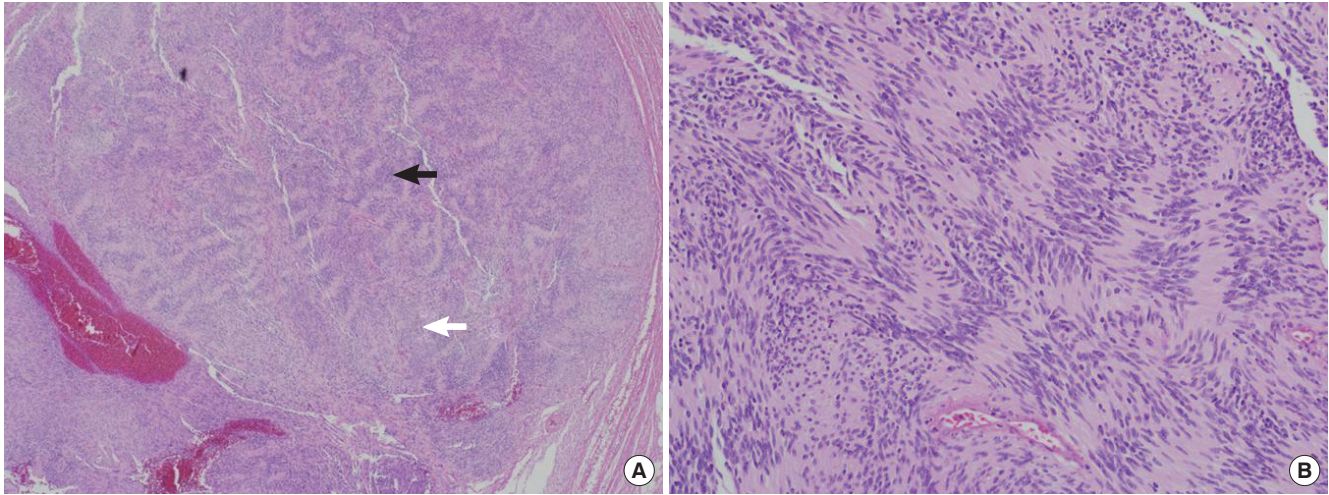
was elevated, including the left tenth rib and the latissimus dorsi muscle. During this process, a 1-cm × 1-cm mass was incidentally found along the subcostal groove of the tenth rib (Fig. 1). This well demarcated mass was excised. The remainder of the operation was uneventful. The results of the histologic examination of this lesion were consistent with a schwannoma (Fig. 2). Upon inquiry, the patient did report occasional bouts of pain in the area, which was described as sharp stabbing pain that worsened with coughing and exercise. However, the preoperative chest computed tomography images did not indicate the presence of the intercostal schwannoma. He did not report any paresthesia or hypoesthesia in the area innervated by the tenth intercostal nerve. The patient was discharged 14 days after the operation without any complications. The patient did not report any subsequent episodes of the pain.

The most common presentation of schwannomas is a palpable mass, the percussion of which result in a painful paresthesia along the involved peripheral nerve [3]. In the case described here, the patient recalled a sharp shooting pain along the tenth intercostal nerve distribution of the left chest wall that worsened with coughing and exercise.

While uncommon, schwannomas of the intercostal nerve can grow to compress the nerve against the



**Fig. 1.**  
(A, B) Intraoperative photographs. A 1-cm × 1-cm mass was incidentally found under the left tenth rib.



**Fig. 2.**

Histopathologic images of the specimen. (A) The low-power view shows a biphasic pattern with a cellular Antoni A area (black arrow) and a hypocellular Antoni B area (white arrow) (H&E, ×40). (B) The high-power view shows tumor cells forming nuclear palisades (Verocay bodies) consisting of alternating parallel rows of tumor cell nuclei and their densely packed, aligned cell processes (H&E, ×400).

subcostal groove, causing intercostal neuralgia, including pain, tenderness, paresthesia, and hypoesthesia. Chronic intercostal neuralgia is relatively common among adults, and is caused by herpes zoster infection, diabetic polyneuropathy, vertebral facet joint hypertrophy or arthritis, and malposition of the costovertebral joint (slipping rib syndrome) [3]. Intercostal neuralgia can also be caused by tumors and/or inflammation in the mediastinal, paravertebral, and costal areas [4]. The intercostal schwannoma and neuralgia in our case did not cause significant disability to the patient, which was most likely due to the fact that the lesion was smaller than most intercostal schwannomas (1 cm × 1 cm compared to the usual size of 2–4 cm).

The intercostal nerves are a part of the somatic nervous system, and originate from the anterior root of the thoracic spinal nerve (T1–T12). Each intercostal nerve is responsible for the sensation of the skin and parietal pleura and the motor activation of the intercostal muscle at its respective level. Since the tenth intercostal nerve is not responsible for significant sensory or motor function, we were able to completely excise the schwannoma in our patient without any morbidities or complications.

This patient was a very rare case of intercostal schwannoma. The small tumor was responsible for intercostal neuralgia. Such small intercostal schwannomas are difficult to detect clinically because the intercostal nerve is located deep in the chest wall and may not be apparent in radiologic studies.

However, larger lesions may involve the surrounding tissue and cause symptoms such as pleural effusion, dyspnea, and Horner's syndrome [5]. Therefore, incidentally found intercostal schwannomas, although generally benign and asymptomatic, should be excised to prevent the development of symptoms or complications from further growth.

## References

1. Yoo G, Byeon JH, Rhie JW, et al. A case of neurilemmomatosis (schwannomatosis). *J Korean Soc Plast Reconstr Surg* 1995;22:670-6.
2. Park WJ, Rhee SK, Kang YK, et al. Schwannoma of the extremities. *J Korean Bone Joint Tumor Soc* 2003;9:148-54.
3. Stumpo M, Poppi M, Rizzo G, et al. Intercostal neuralgic schwannoma: a case report. *Muscle Nerve* 2002;25:753-4.
4. Gilbert RW, Kim JH, Posner JB. Epidural spinal cord compression from metastatic tumor: diagnosis and treatment. *Ann Neurol* 1978;3:40-51.
5. Morimoto J, Nakajima T, Iizasa T, et al. Successful resection of schwannoma from an intercostal nerve causing bloody pleural effusion: report of a case. *Surg Today* 2011;41:989-91.