

noted that some recurrent and metastatic tumors contain zones of increased cellularity and mitotic activity [2]. In this type of tumor, adequate surgical excision of the tumor is necessary because of the frequent recurrence of LGFMS [1]. The young patient age and superficial location likely contribute to a benign clinical diagnosis in many cases of superficial LGFMS. This clinical impression could potentially result in a delayed biopsy or excision and potentially worsen the patient outcome. The recommended treatment for LGFMS includes radical surgery, wide en bloc surgical resection, complete resection, compartmental excision, and local excision. Adjuvant radiotherapy or chemotherapy has not been recommended in previous reports. As these tumors are prone to metastasis after a long interval, sometimes after as many as 45 years, a thorough clinical follow-up is recommended. However, no study to date has recommended any protocol for the follow-up [5]. Thus, we described a rare case of facial LGFMS in a woman. She had no evidence of local recurrence or metastases at the postoperative 8-month follow-up.

References

1. Abe Y, Hashimoto I, Nakanishi H. Recurring facial low-grade fibromyxoid sarcoma in an elderly patient: a case report. *J Med Invest* 2012;59:266-9.
2. Evans HL. Low-grade fibromyxoid sarcoma: a report of 12 cases. *Am J Surg Pathol* 1993;17:595-600.
3. Liao KS, Huang WT, Yang SF, et al. Intramuscular low-grade fibromyxoid sarcoma: a case report. *Kaohsiung J Med Sci* 2009;25:448-54.
4. Folpe AL, Lane KL, Paull G, et al. Low-grade fibromyxoid sarcoma and hyalinizing spindle cell tumor with giant rosettes: a clinicopathologic study of 73 cases supporting their identity and assessing the impact of high-grade areas. *Am J Surg Pathol* 2000;24:1353-60.
5. Indap S, Dasgupta M, Chakrabarti N, et al. Low grade fibromyxoid sarcoma (Evans tumour) of the arm. *Indian J Plast Surg* 2014;47:259-62.

Squamous Cell Carcinoma Arising from an Epidermal Inclusion Cyst

Jin-Won Lee, Jin-Yong Shin, Si-Gyun Roh, Nae-Ho Lee, Kyung-Moo Yang

Department of Plastic and Reconstructive Surgery, Chonbuk National University Medical School, Jeonju, Korea

Correspondence: Si-Gyun Roh
Department of Plastic and Reconstructive Surgery, Chonbuk National University Medical School, 20 Geonji-ro Deokjin-gu, Jeonju 54907, Korea
Tel: +82-63-250-1860, Fax: +82-63-250-1866, E-mail: pssroh@jbnu.ac.kr

No potential conflict of interest relevant to this article was reported.

Received: 27 Mar 2015 • Revised: 31 Jul 2015 • Accepted: 31 Jul 2015
pISSN: 2234-6163 • eISSN: 2234-6171
<http://dx.doi.org/10.5999/aps.2016.43.1.112>
Arch Plast Surg 2016;43:112-114



Copyright © 2016 The Korean Society of Plastic and Reconstructive Surgeons
This is an Open Access article distributed under the terms of the Creative Commons Attribution Non-Commercial License (<http://creativecommons.org/licenses/by-nc/3.0/>) which permits unrestricted non-commercial use, distribution, and reproduction in any medium, provided the original work is properly cited.

Epidermal inclusion cysts are commonly encountered benign cystic lesions that can occur anywhere in the body. However, malignant changes are rare, and only a few cases of malignant change have previously been reported [1,2].

Anton-Badiola et al. [2], based on a total of 13 reported cases, found that the mean age at presentation of squamous cell carcinoma arising from an epidermal inclusion cyst was 43.2 years. They also observed that it occurred more frequently in men, that the head and neck area was the most commonly

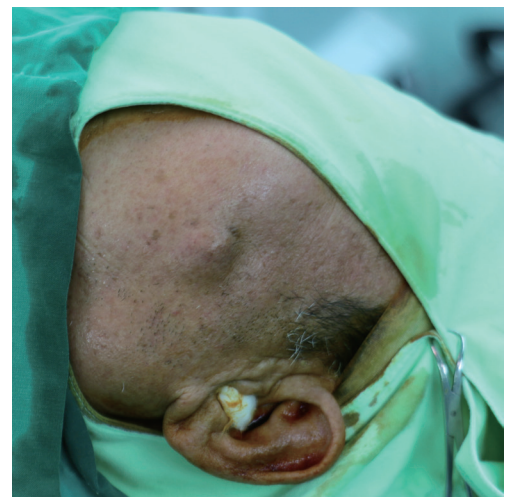

Fig. 1.

A 62-year-old male who presented with a 2×2-cm soft bulging mass on the left cheek.

affected region, and that the mean diameter was 5.7 cm.

Although a specific triggering factor for this malignant transformation has not yet been established, a well-known risk factor for malignancy is chronic irritation of the skin. Several possible factors, such as sun-related actinic damage and human papilloma virus skin infection, have been suggested to be triggering factors [2-5]; however, more research regarding the direct influence of these factors on malignancy is needed.

A 62-year-old male presented with a cyst on his left cheek that had grown rapidly in size over the course of three months (Fig. 1). Physical examination revealed a mildly hard, fixed, bulging, and painless mass measuring 2 cm in diameter.

At first, we thought this was likely to be a simple cystic mass. Thus, only a straightforward ultrasonography study was performed, leading to the biopsy of a benign-appearing palpable mass lesion in the cheek, performed under local anesthesia. The permanent biopsy was performed immediately by a pathologist. Contrary to expectations, the pathologic finding was well-differentiated squamous cell carcinoma arising from an epidermal inclusion cyst.

Gross examination showed an elliptical patch of skin measuring 2.5 × 2.5 cm, with an attached nodular lesion measuring 2.0 cm in diameter with an irregular margin. Upon dissection, the cut surface revealed a cystic mass containing yellowish keratin material.

Microscopically, malignant cells were found to have infiltrated the interior of an epidermal cyst, comprising 30% of its total size. Multiple neoplastic

cells with large nuclei were found next to an epidermal inclusion cyst (Fig. 2). These pleomorphic cells appeared to arise from the overlying squamous epithelium of the cyst (Fig. 3). These cells showed an irregular patterned contour and obvious nucleoli with abnormal mitosis (Fig. 4). All of these features indicated a lesion of well-differentiated squamous cell carcinoma arising from an epidermal inclusion cyst.

Further evaluation was then performed. Contrast-enhanced computed tomography showed a heterogeneous and irregular margin in the subcutaneous fat layer with no cervical lymph node metastasis. A Tc-99m whole body bone scan showed no bone metastasis. Seven days later, reoperation was performed to extend the surgical margin, and total excision with a 1-cm margin was performed under local anesthesia. Free surgical resection margins were observed on the frozen biopsy. After the excision, the skin and soft tissue defect measured 4.0 × 4.0 cm and the defect was covered by a bilateral V-Y advancement flap. No clinical evidence of recurrence was observed more than one year postoperatively.

In our case, the patient had a mass that rapidly grew over the course of three months. We suggest that the rapid growth of the mass was an element of tumoral pathogenesis, causing the benign epithelium to undergo abnormal dysplastic change.

Epidermal inclusion cysts and squamous cell carcinoma are commonly encountered skin lesions in practice. The malignant transformation of these cysts is rare, and few cases showing such malignant changes have been previously reported.

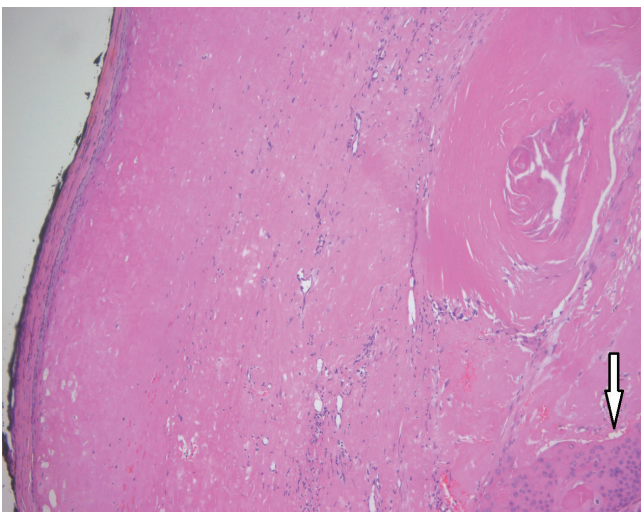


Fig. 2. Neoplastic cells with large nuclei (white arrow) were found under the epidermal inclusion cyst containing keratin (H&E, × 100).

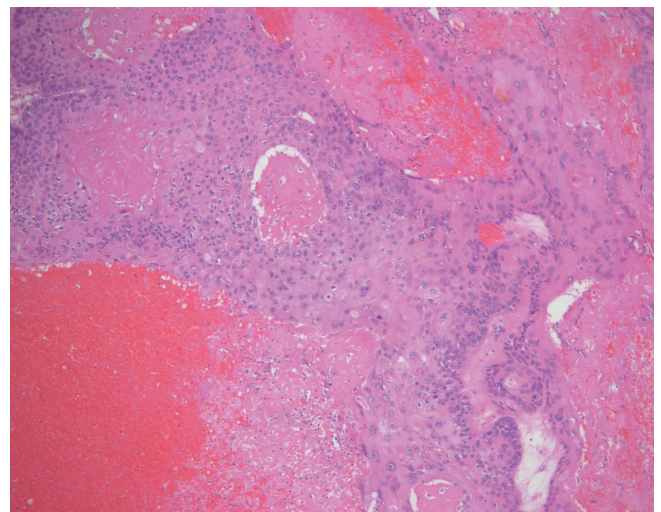


Fig. 3. The tumor cells had large nuclei and showed pleomorphism of each cell (H&E, × 100).

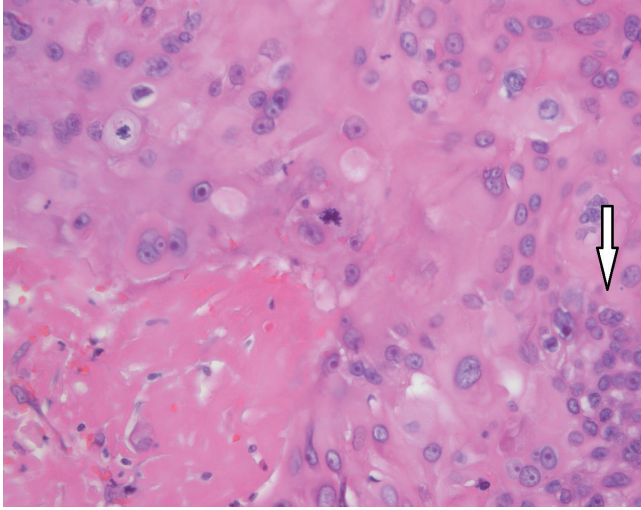


Fig. 4.

Normal epithelial cells have a regular margin with a circular shape. Malignant cells have an irregular polygonal shape (white arrow) (H&E, ×400).

The etiology of malignant transformation in epidermal inclusion cysts remains uncertain. Chronic irritation of the lesion has been frequently suggested as a triggering factor.

Due to the infrequency of malignant changes, not all epidermal inclusion cysts are routinely excised, and not all excised cysts are sent to pathologists for accurate examination.

In summary, despite the rarity of malignant transformations of epidermal inclusion cysts, we suggest that malignant changes should be suspected in cases showing rapid growth, ulceration, or frequent recurrence. Moreover, complete excision with pathological examination should be performed in all cases of epidermal inclusion cysts to avoid misdiagnosis.

References

1. Chiu MY, Ho ST. Squamous cell carcinoma arising from an epidermal cyst. *Hong Kong Med J* 2007;13:482-4.
2. Anton-Badiola I, San Miguel-Fraile P, Peteiro-Cancelo A, et al. Squamous cell carcinoma arising on an epidermal inclusion cyst: a case presentation and review of the literature. *Actas Dermosifiliogr* 2010;101:349-53.
3. Lin CY, Jwo SC. Squamous cell carcinoma arising in an epidermal inclusion cyst. *Chang Gung Med J* 2002;25:279-82.
4. Tokunaga M, Toya M, Endo Y, et al. A case of an undifferentiated squamous cell carcinoma arising from an epidermal cyst. *Case Rep Dermatol Med* 2013;2013:469516.

S. Morritt AN, Tiffin N, Brotherston TM. Squamous cell carcinoma arising in epidermoid cysts: report of four cases and review of the literature. *J Plast Reconstr Aesthet Surg* 2012;65:1267-9.

Extra-Abdominal Desmoid Tumor in the Donor Site of an Extended Latissimus Dorsi Flap

Jai-Kyong Pyon, Bo Young Kang, Goo-Hyun Mun, Sa-Ik Bang, Kap Sung Oh, So-Young Lim

Department of Plastic Surgery, Samsung Medical Centre, Sungkyunkwan University School of Medicine, Seoul, Korea

Correspondence: Jai-Kyong Pyon

Department of Plastic Surgery, Samsung Medical Center, Sungkyunkwan University School of Medicine, 81 Irwon-ro, Gangnam-gu, Seoul 06351, Korea
Tel: +82-2-3410-2236, Fax: +82-2-3410-0036
E-mail: ps priest.pyon@samsung.com

No potential conflict of interest relevant to this article was reported.

Received: 12 Mar 2015 • Revised: 6 Apr 2015 • Accepted: 13 Apr 2015
pISSN: 2234-6163 • eISSN: 2234-6171
<http://dx.doi.org/10.5999/aps.2016.43.1.114>
Arch Plast Surg 2016;43:114-116



Copyright © 2016 The Korean Society of Plastic and Reconstructive Surgeons
This is an Open Access article distributed under the terms of the Creative Commons Attribution Non-Commercial License (<http://creativecommons.org/licenses/by-nc/3.0/>) which permits unrestricted non-commercial use, distribution, and reproduction in any medium, provided the original work is properly cited.

Desmoid tumors are slow-growing fibrous neoplasms, arising from deep musculoaponeurotic structures, and can occur in the abdominal wall, abdominal cavity, or outside the abdomen. Although desmoid tumors are histologically benign and do not metastasize, they are often regarded as semimalignant lesions due to their tendency towards local invasion and repetitive recurrence.

Reports suggest that desmoid tumors represent about 0.03% of tumors and less than 3% of all soft tissue tumors. The incidence of desmoid tumors is known to be about two to four persons per million members of the general population per year [1]. Although desmoid tumors are usually associated with Gardner's syndrome, which is a variant of familial adenomatous polyposis, they can arise sporadically.

The exact etiology of the development of sporadic desmoid tumors is unknown; however, there have been reports of desmoid tumor development following trauma or abdominal surgery, such as