

Discussion

Cephalometric Angular Measurements of the Mandible Using Three-Dimensional Computed Tomography Scans in Koreans

Kang Young Choi¹, Nak Heon Kang²

¹Department of Plastic and Reconstructive Surgery, Kyungpook National University School of Medicine, Daegu; ²Department of Plastic and Reconstructive Surgery, Chungnam National University School of Medicine, Daejeon, Korea

Radiologic imaging has become an essential instrument in medicine. In computed tomography (CT) imaging, the X-ray emitter and sensors rotate about the axial plane and overlapping X-ray beams penetrate the body from various directions. Most internal organs differ from each other in radiation-absorptive density, and this leads to variations in the amount of radiation detected by the sensor. Computers analyze this variability in radiation absorption and tomographically deduce two-dimensional (2D) data on the internal tissue density and shape. To sum up, CT imaging produces computer images after measuring X-rays from various directions and processing their radiation-absorptive density.

With recent advances in image processing technology, raw data from CT machines can be used to construct three-dimensional (3D) tomographic data, known as “volume rendering.” Unlike surface rendering, 3D images from volume rendering allow rotation and translation along all three axes (*x*, *y*, and *z*), as well as observation of stair-step artifacts and the inner surface of the bone cortex. This enables simple and rapid interpretation of the internal anatomy and physiology [1]. Recently, even 3D printing technology using 3D CT has been evolving into patient-specific individualized medicine [2].

In CT images, distances are calculated using the number of pixels between two points. This pixel-distance is converted to the physical distance of the object measured using a pixel-space to millimeter conversion factor (i.e., Pixel Spacing) stored in the Digital Imaging and Communications in Medicine (DICOM) Tag (0028, 0030) (Fig. 1). Using the ‘image calculate’ parameter, distances measured on 2D CT images correlate extremely well with the physical objects the images represent. All of this can readily be accomplished on picture archiving and communication system (PACS) monitors. However, distance projection in a 3D model is a different matter. The images are simplified

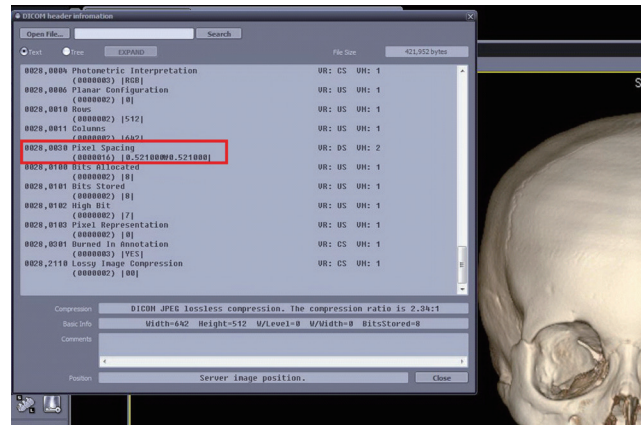


Fig. 1. Digital Imaging and Communications in Medicine (DICOM) Tag Information. The red box indicates a DICOM Tag (0028, 0030 Pixel Spacing), and other information stored with this DICOM Tag.

2D projections of the real 3D model, which is transmitted from the PACS server to the client without the metadata such as Pixel Spacing, monitor resolution, image magnification, or *z*-axis values. Thus, the information needed to translate pixel distance into physical distance is lost during this process, which implies that interpersonal anthropometric comparisons are not possible with 3D CT images. Of course, 3D images can still allow for intrapersonal comparisons (e.g., before and after an intervention), but this can only represent relative, not absolute, changes in anthropometry [3].

In the study titled “Cephalometric parameters of the mandible on three-dimensional computed tomography scans in Koreans,” the authors sought to establish linear cephalometric means for the Korean population using 3D CT reconstructions. Unlike 2D cephalometry, conventional 3D CT allows for absolute measurement of cephalometric angles. However, absolute linear measurements cannot be obtained unless imaging and capturing settings are the same in every object. This is why there is no published research on absolute measurements using 3D CT despite numerous potential applications for such information.

In a study on the effect of aging on the midmaxilla, Shaw and Kahn [4] had used 3D CT images for measuring the various angular parameters. In a similar study using 3D CT to evaluate mandibular aging, Pessa et al. [5] had used sectional images—not 3D models—for direct measurement of the mandible. In addition, Oh et al. [6] argued that only angular measurements would be statistically significant in a study comparing 3D CT images to conventional lateral cephalometry.

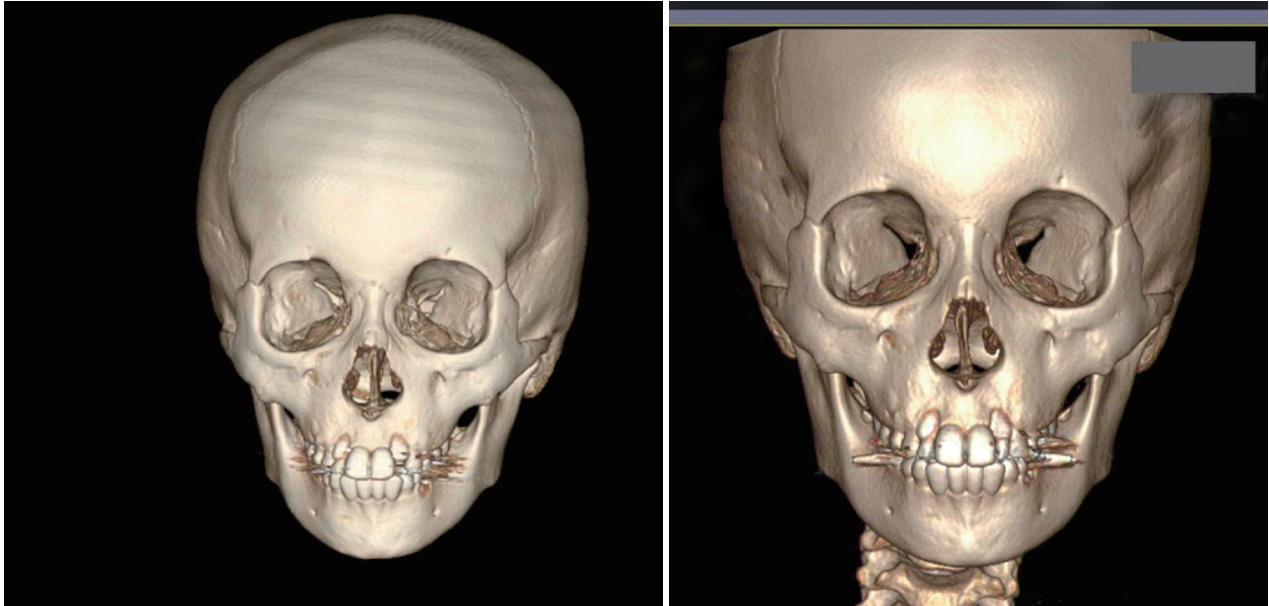

Fig. 2. Three-dimensional-computed tomography (3D CT) reconstructed model. It is difficult to use one 3D CT reconstructed image as a reference for another due to the different absolute values generated by differing conditions such as display field of view, tilt, and window, as in the two images shown here.

In reality, absolute values differ even for a single patient whose CT scans were obtained under differing conditions (Fig. 2). However, if the various conditions of CT scans are unified, not only the measurement of the absolute values but also interpersonal comparison is possible. The following factors are needed: First, the physical values for the CT scans must be the same across all scans. These include the field of view, angle value, z-axis value, monitor resolution, and image magnification. With these conditions held constant, images can be reconstructed in the display window on the screen and measurements can be screen-captured and sent to the PACS. In such contexts, the linear and angular measurements are representative of the physical values.

To conclude, retrospective studies on 3D CT anthropometry can be difficult because of confounding factors that can influence comparisons. Therefore, to obtain accurate data, investigators should design studies prospectively with the variables of the CT scanner set consistently for all images obtained. Even under such conditions, limitations still exist in volume measurement and comparisons in individual physical properties (i.e., Hounsfield units).

REFERENCES

1. Kuszyk BS, Heath DG, Bliss DF, et al. Skeletal 3-D CT: advantages of volume rendering over surface rendering. *Skeletal Radiol* 1996;25:207-14.
2. Choi JW, Kim N. Clinical application of three-dimensional printing technology in craniofacial plastic surgery. *Arch Plast Surg* 2015;42:267-77.
3. Whymys BJ, Vorperian HK, Gentry LR, et al. The effect of computed tomographic scanner parameters and 3-dimensional volume rendering techniques on the accuracy of linear, angular, and volumetric measurements of the mandible. *Oral Surg Oral Med Oral Pathol Oral Radiol* 2013;115:682-91.
4. Shaw RB Jr, Kahn DM. Aging of the midface bony elements: a three-dimensional computed tomographic study. *Plast Reconstr Surg* 2007;119:675-81.
5. Pessa JE, Slice DE, Hanz KR, et al. Aging and the shape of the mandible. *Plast Reconstr Surg* 2008;121:196-200.
6. Oh S, Kim CY, Hong J. A comparative study between data obtained from conventional lateral cephalometry and reconstructed three-dimensional computed tomography images. *J Korean Assoc Oral Maxillofac Surg* 2014;40:123-9.

Correspondence: Nak Heon Kang

Department of Plastic and Reconstructive Surgery, Chungnam National University School of Medicine, 282 Munhwa-ro, Jung-gu, Daejeon 35015, Korea
Tel: +82-42-280-7380, Fax: +82-42-280-7384, E-mail: nhk488@yahoo.com

No potential conflict of interest relevant to this article was reported.

Received: 5 Dec 2015 • Revised: 28 Dec 2015 • Accepted: 28 Dec 2015
pISSN: 2234-6163 • eISSN: 2234-6171
<http://dx.doi.org/10.5999/aps.2016.43.1.38> • *Arch Plast Surg* 2016;43:38-39

