

IMAGES

Forehead Inclination in the Lateral Profile in Koreans

Min Joon Oh, Seok Joo Kang, Seong Pin Jeon, Hook Sun

Department of Plastic and Reconstructive Surgery, Busan Paik Hospital, Inje University College of Medicine, Busan, Korea

Correspondence: Hook Sun
 Department of Plastic and Reconstructive Surgery, Busan Paik Hospital, Inje University College of Medicine, 75 Bokji-ro, Busanjin-gu, Busan 47392, Korea
 Tel: +82-51-890-6136, Fax: +82-51-894-7976
 E-mail: sun443@naver.com

No potential conflict of interest relevant to this article was reported.

Received: 10 Jun 2015 • Revised: 22 Jan 2016 • Accepted: 7 Feb 2016
 pISSN: 2234-6163 • eISSN: 2234-6171
<http://dx.doi.org/10.5999/aps.2016.43.3.293>
 Arch Plast Surg 2016;43:293-295



Copyright © 2016 The Korean Society of Plastic and Reconstructive Surgeons
 This is an Open Access article distributed under the terms of the Creative Commons Attribution Non-Commercial License (<http://creativecommons.org/licenses/by-nc/4.0/>) which permits unrestricted non-commercial use, distribution, and reproduction in any medium, provided the original work is properly cited.

The forehead is the part of the face extending from the line of the hair border to the temples and the eyebrows [1]. It occupies one third of the upper part of the face and plays an important role in facial expressions. The outcome of forehead reconstruction surgery is a significant contributing factor to facial expressions and the quality of life in patients with excavation of the forehead due to an injury or a congenital deformity.

The present study aimed to establish the average value of forehead inclination in the modern Korean population, according to sex and age, as a reference for deciding the scope of surgery affecting the contour of the forehead and for evaluating the outcomes of plastic and reconstructive surgery.

We selected 200 Koreans, comprising 100 men and 100 women, ranging in age from 20 years, when craniofacial growth is completed, to 50 years. Patients in whom the border line between the hairline and the forehead was behind the vertex were excluded.

Table 1. Forehead inclination values in the lateral profile in Koreans (n=200)

	Mean	95% Confidence interval	P-value ^{a)}
Male (n = 100)	-15.90	(-16.81 to -14.92)	<0.001
Female (n = 100)	-12.47	(-13.34 to -11.63)	

^{a)}Calculated using the t-test.

The reference point for measuring inclination was based on the report of Andrews [2]. The trichion is the point where the center line of the forehead meets the hairline and the uppermost extent of the relatively flat parts of the forehead. The glabella is the lowest part of the forehead and is the point exhibiting the most protrusion between both eyebrows [2,3].

Inclination was measured using a goniometer with the face placed on the Frankfurt horizontal line. The Frankfurt horizontal line is an extension of the imaginary line between the tragus at the height of the external auditory meatus and the lower orbital bone, which is the continuation of the lower lid into the face [4]. When measuring the lateral contour of the forehead, the inclination was measured as the angle between the line from the trichion to the glabella and the line perpendicular to the Frankfurt horizontal line. The line perpendicular to the Frankfurt horizontal line was defined as 0°. Protrusion anterior to the line was considered positive inclination, whereas protrusion posterior to the line was considered negative inclination (Fig. 1).

The mean values and 95% confidence intervals (CIs) were calculated for men and women. Comparisons of the forehead inclination by gender were made using the independent t-test. Comparisons of forehead inclination according to age groups after stratification by gender were calculated using analysis of variance. All statistical analyses were carried out using SPSS ver. 21.0 (IBM Co., Armonk, NY, USA). The statistical significance level was set at P < 0.05.

The mean values (95% CI) of forehead inclination were -15.90° (-16.81° to -14.92°) for men and -12.47° (-13.34° to -11.63°) for women (Fig. 1B, C). Forehead inclination was found to differ significantly according to gender (P < 0.001) (Table 1).

Table 2. Forehead inclination values in the lateral profile in Koreans according to age and gender

	Mean	95% Confidence interval	P-value ^{a)}
Males			<0.001
Twenties	-13.01	(-14.98 to -11.12)	
Thirties	-15.10	(-16.69 to -13.54)	
Forties	-18.50	(-20.02 to -16.82)	
Fifties	-17.00	(-18.63 to -15.41)	
Females			0.026
Twenties	-11.02	(-12.95 to -9.22)	
Thirties	-11.51	(-13.14 to -9.74)	
Forties	-13.00	(-14.50 to -11.51)	
Fifties	-14.38	(-15.87 to -12.72)	

^{a)}Calculated by analysis of variance.

In addition, the mean values (95% CI) of forehead inclination values by age group in men were -13.01° (-14.98° to -11.12°), -15.10° (-16.69° to -13.54°), -18.50° (-20.02° to -16.82°), and -17.00° (-18.63° to -15.41°) for participants in their twenties, thirties, forties, and fifties, respectively. For women, the corresponding mean values (95% CI) were -11.02° (-12.95° to -9.22°), -11.51° (-13.14° to -9.74°), -13.00° (-14.50° to -11.51°), and -14.38° (-15.87° to -12.72°) for participants in their twenties, thirties, forties, and fifties, respectively (Table 2). Forehead inclination according to age group after stratification by gender showed a significant difference both in men ($P < 0.001$) and women ($P = 0.026$).

Previous studies were published on forehead inclination in Koreans by Lee et al. [4] in 1989 and Hwang et al. [3] in 2002. Lee's photogrammetric analysis was limited to a study of young women [4], while our research analyzed both men and women of different age groups using direct anthropometric measurements. Hwang's cephalometric analysis defined the forehead angle (FHA) as the angle between the nasion perpendicular line (NP) and the line connecting the intersection of the NP with the forehead and the soft tissue of the glabella [3]. However, the FHA has limitations as a metric for analyzing the slope of the forehead because it is highly affected by the shape of the nasal bone. Our method was different from Hwang's in that we measured the angle between the line extending from the trichion to the glabella and the line perpendicular to the Frankfurt horizontal line using lateral-view photographs.

Farkas et al. [5] observed that the average forehead inclination in Caucasians was -5.5° using portraits from the past. Our research showed that the average forehead inclination in Korean men was -15.9° and

-12.47° for women, indicating forehead inclination in the posterior direction. In 2008, Andrews [2] measured forehead inclinations in adult Caucasian women using the superior, not the trichion, as the reference point. Comparing our findings with Andrews' research is difficult since his research did not take into account several standard points and the Frankfurt horizontal line.

We obtained the mean values of forehead inclination for various age groups and observed that older people had more posteriorly inclined foreheads than younger people. Both men and women exhibited the largest difference between their thirties and forties. We hypothesize that the resorption of bone or soft tissue is one of the reasons that forehead inclination was found to become more posterior with age.

With changes in beauty standards over time, trends in the facial contour, which is the frame that defines facial expressions, have likewise changed. However, few studies have been conducted regarding the appearance of Koreans in the lateral view. Our results can be used as a reference point for deciding the scope of surgery and to evaluate the outcomes of forehead reconstructions and plastic surgery in Koreans.

Our method, which involved measuring the degree of inclination either anteriorly or posteriorly to the line between the trichion and the glabella, is limited regarding the expressions of the fine contours of the forehead, which involve curves. This suggests that additional studies are needed, with consideration of the maximum points of protrusion and excavation and the curved pattern of the forehead. Moreover, further evaluation of the correlation between forehead height and inclination is required.

In conclusion, our study analyzing forehead contours will prove helpful to plastic surgeons by

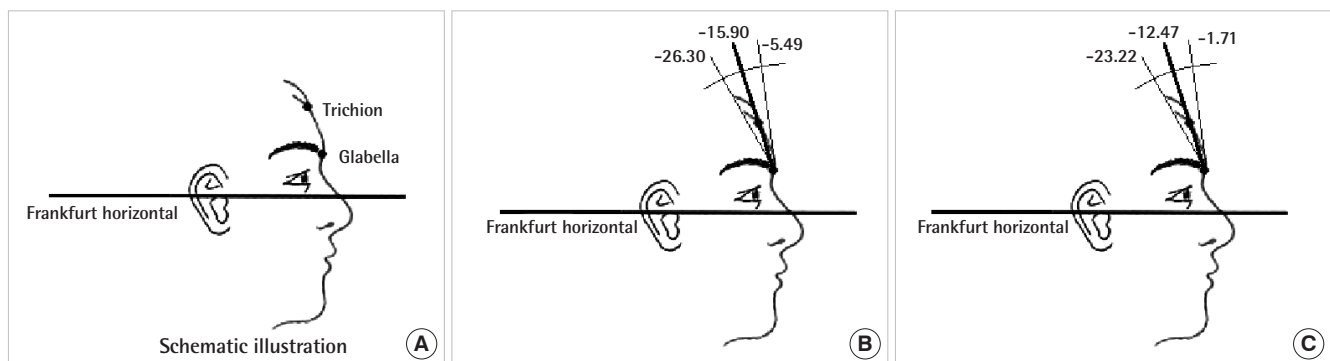


Fig. 1.

(A) Schematic illustration of forehead landmarks and the Frankfurt horizontal line. (B, C) Measurements of forehead inclination in the lateral profile in Koreans. (B) Men. (C) Women.

providing reference values of forehead inclination in Koreans.

References

1. Stedman TL. Stedman's medical dictionary. Philadelphia: Lippincott Williams & Wilkins; 2006.
2. Andrews WA. AP relationship of the maxillary central incisors to the forehead in adult white females. *Angle Orthod* 2008;78:662-9.
3. Hwang HS, Kim WS, McNamara JA Jr. Ethnic differences in the soft tissue profile of Korean and European-American adults with normal occlusions and well-balanced faces. *Angle Orthod* 2002;72:72-80.
4. Lee D, Kim W, Chung C, et al. Photogrammetric study on the face of adult Korean female. *J Korean Soc Plast Reconstr Surg* 1989;16:423-32.
5. Farkas LG, Sohm P, Kolar JC, et al. Inclinations of the facial profile: art versus reality. *Plast Reconstr Surg* 1985;75:509-19.

Sepsis Leading to Mortality after Augmentation Rhinoplasty with a Septal Extension Graft and Fat Grafting

Moo Hyun Kim, Bong Soo Baik, Wan Suk Yang, Won Ha, So Young Ji

Department of Plastic and Reconstructive Surgery, Dong Kang General Hospital, Ulsan, Korea

Correspondence: Bong Soo Baik
Department of Plastic and Reconstructive Surgery, Dong Kang General Hospital, 239 Taehwa-ro, Jung-gu, Ulsan 44455, Korea
Tel: +82-52-241-1738, Fax: +82-52-241-1738, E-mail: bsbaiky@naver.com

This article was presented at the Fifth Research and Reconstructive Forum on May 14–15, 2015 in Pyeongchang, Korea.

No potential conflict of interest relevant to this article was reported.

Received: 13 Jul 2015 • Revised: 29 Dec 2015 • Accepted: 4 Jan 2016
pISSN: 2234-6163 • eISSN: 2234-6171
<http://dx.doi.org/10.5999/aps.2016.43.3.295>
Arch Plast Surg 2016;43:295-296



Copyright © 2016 The Korean Society of Plastic and Reconstructive Surgeons
This is an Open Access article distributed under the terms of the Creative Commons Attribution Non-Commercial License (<http://creativecommons.org/licenses/by-nc/4.0/>) which permits unrestricted non-commercial use, distribution, and reproduction in any medium, provided the original work is properly cited.

Infection is the most serious complication after rhinoplasty, with rates reported to range from 2.6% to 5.3% [1]. In that study, most infections were found to

be localized and improved after removal of the implant and appropriate antibiotic therapy. Although a case report has described staphylococcal spinal osteomyelitis after septoplasty as a consequence of bacteremia [2], no case of sepsis resulting in death after rhinoplasty has been reported. We report the case of a male patient who expired due to infection after rhinoplasty with a septal extension graft, silicone implant, and fat grafting, and then review and discuss the relevant literature.

A 27-year-old previously healthy male patient underwent blepharoplasty, augmentation rhinoplasty with a silicone implant, a septal extension graft with a strut graft, and the grafting of retroseptal fat that was harvested during blepharoplasty at the local hospital onto the nasal tip for tip projection. Erythema occurred in the nasal tip and columella on the first postoperative day, and ceftriaxone was therefore prescribed. On the second postoperative day, the patient complained of a general itching sensation caused by an allergic reaction, and the antibiotic regimen was then changed to a combination of ciprofloxacin and amikacin. Nevertheless, the erythema of the nasal tip worsened and wound disruption occurred (Fig. 1). On the tenth postoperative day, the silicone implant and septal extension graft were removed in our hospital (Fig. 2). Intraoperatively, extensive tissue necrosis and signs of infection were observed in the septal mucosa (Fig. 3).

For infection control, 400 mg of ciprofloxacin was administered twice a day and massive irrigation was performed. However, fever occurred and symptoms related to sepsis appeared on the third day (Table 1). Therefore, 1,500 mg of amoxicillin was prescribed as a broad-spectrum antibiotic pending the results of the susceptibility test. Five days after the

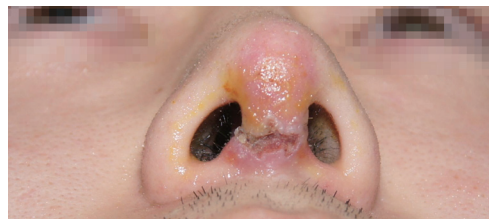

Fig. 1. Preoperative view. Erythema on the nasal tip and columella is shown. The incision wound was disrupted.

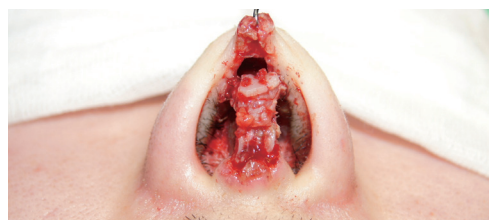

Fig. 2. Intraoperative view. The silicone implant was removed. The only graft and columellar strut graft are shown.