

providing reference values of forehead inclination in Koreans.

References

1. Stedman TL. Stedman's medical dictionary. Philadelphia: Lippincott Williams & Wilkins; 2006.
2. Andrews WA. AP relationship of the maxillary central incisors to the forehead in adult white females. *Angle Orthod* 2008;78:662-9.
3. Hwang HS, Kim WS, McNamara JA Jr. Ethnic differences in the soft tissue profile of Korean and European-American adults with normal occlusions and well-balanced faces. *Angle Orthod* 2002;72:72-80.
4. Lee D, Kim W, Chung C, et al. Photogrammetric study on the face of adult Korean female. *J Korean Soc Plast Reconstr Surg* 1989;16:423-32.
5. Farkas LG, Sohm P, Kolar JC, et al. Inclinations of the facial profile: art versus reality. *Plast Reconstr Surg* 1985;75:509-19.

Sepsis Leading to Mortality after Augmentation Rhinoplasty with a Septal Extension Graft and Fat Grafting

Moo Hyun Kim, Bong Soo Baik, Wan Suk Yang, Won Ha, So Young Ji

Department of Plastic and Reconstructive Surgery, Dong Kang General Hospital, Ulsan, Korea

Correspondence: Bong Soo Baik
Department of Plastic and Reconstructive Surgery, Dong Kang General Hospital, 239 Taehwa-ro, Jung-gu, Ulsan 44455, Korea
Tel: +82-52-241-1738, Fax: +82-52-241-1738, E-mail: bsbaiksy@naver.com

This article was presented at the Fifth Research and Reconstructive Forum on May 14–15, 2015 in Pyeongchang, Korea.

No potential conflict of interest relevant to this article was reported.

Received: 13 Jul 2015 • Revised: 29 Dec 2015 • Accepted: 4 Jan 2016
pISSN: 2234-6163 • eISSN: 2234-6171
<http://dx.doi.org/10.5999/aps.2016.43.3.295>
Arch Plast Surg 2016;43:295-296



Copyright © 2016 The Korean Society of Plastic and Reconstructive Surgeons
This is an Open Access article distributed under the terms of the Creative Commons Attribution Non-Commercial License (<http://creativecommons.org/licenses/by-nc/4.0/>) which permits unrestricted non-commercial use, distribution, and reproduction in any medium, provided the original work is properly cited.

Infection is the most serious complication after rhinoplasty, with rates reported to range from 2.6% to 5.3% [1]. In that study, most infections were found to

be localized and improved after removal of the implant and appropriate antibiotic therapy. Although a case report has described staphylococcal spinal osteomyelitis after septoplasty as a consequence of bacteremia [2], no case of sepsis resulting in death after rhinoplasty has been reported. We report the case of a male patient who expired due to infection after rhinoplasty with a septal extension graft, silicone implant, and fat grafting, and then review and discuss the relevant literature.

A 27-year-old previously healthy male patient underwent blepharoplasty, augmentation rhinoplasty with a silicone implant, a septal extension graft with a strut graft, and the grafting of retroseptal fat that was harvested during blepharoplasty at the local hospital onto the nasal tip for tip projection. Erythema occurred in the nasal tip and columella on the first postoperative day, and ceftriaxone was therefore prescribed. On the second postoperative day, the patient complained of a general itching sensation caused by an allergic reaction, and the antibiotic regimen was then changed to a combination of ciprofloxacin and amikacin. Nevertheless, the erythema of the nasal tip worsened and wound disruption occurred (Fig. 1). On the tenth postoperative day, the silicone implant and septal extension graft were removed in our hospital (Fig. 2). Intraoperatively, extensive tissue necrosis and signs of infection were observed in the septal mucosa (Fig. 3).

For infection control, 400 mg of ciprofloxacin was administered twice a day and massive irrigation was performed. However, fever occurred and symptoms related to sepsis appeared on the third day (Table 1). Therefore, 1,500 mg of amoxicillin was prescribed as a broad-spectrum antibiotic pending the results of the susceptibility test. Five days after the

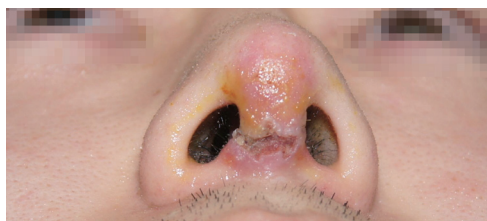

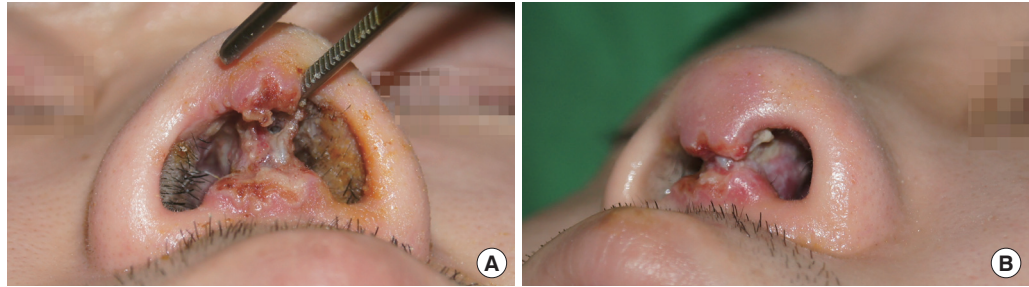
Fig. 1. Preoperative view. Erythema on the nasal tip and columella is shown. The incision wound was disrupted.

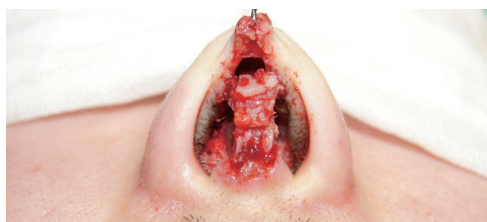

Fig. 2. Intraoperative view. The silicone implant was removed. The only graft and columellar strut graft are shown.

Fig. 3.

Intraoperative view. (A, B) The septal extension graft was removed. Extensive tissue necrosis and signs of infection were observed in the septal mucosa. This picture was taken on the day of the operation in our hospital and ten days after surgery at a local clinic.

**Table 1. Changes in the laboratory results of the patient over the course of the infection**

Variable	Day of the exploratory operation	Third postoperative day	Fourth postoperative day	Fifth postoperative day
Fever (°C)	36.8	38.5	38.6	38.0
Aspartate aminotransferase (μ/L)	34	251	463	2,123
Alanine transaminase (μ/L)	37	247	482	1,445
White blood cell count (/μL)	5,200	10,100	7,400	1,500
C-reactive protein (mg/L)	0.1	13.93	11.83	11.98

debridement, the wound culture from the grafted fat was identified as methicillin-resistant *Staphylococcus epidermidis*. We changed the antibiotic prescription to 1 g of vancomycin twice a day based on the results of the susceptibility test. Nonetheless, the patient's general condition worsened. We transferred the patient to a tertiary care university hospital, but he eventually expired three days later.

The nasal septum adjoins the brain, and a case of *S. pneumoniae* meningitis after septoplasty as a result of this anatomical feature has been reported [3]. However, our patient's cerebrospinal fluid was normal and no signs of meningitis, such as nuchal rigidity or mental status change, were noted.

In the present case, the cultured organism was methicillin-resistant *S. epidermidis*, a type of so-called superbug. However, the patient showed no response to antibiotics, making it difficult to ascertain that *S. epidermidis* was the primary cause of sepsis. Administering broad-spectrum antibiotic therapy within one hour after the diagnosis of severe sepsis is recommended, and the antibiotic regimen should be reassessed every 24 hours for de-escalation. Reassessment of the antibiotic therapy needs to continue after the susceptibility test results are reported, and the antibiotic therapy must be changed when septic conditions are escalated. The choice of antibiotics depends on the suspected site of the infection, the setting in which the infection developed, the patient's medical history, and local microbial-susceptibility patterns [4]. The blood culture, the results of which were only available after

the patient expired, showed no growth. This may have been a false negative due to antibiotic coverage. The exact cause of sepsis was not determined by autopsy, which found no evidence of underlying disease related to impaired immunity, including leukemia and lymphoma.

This was a rare case in a young man, although infections can easily spread from the septal mucosa, which has a rich blood supply, to the brain and to the entire body. Therefore, aggressive treatment of the affected area is the best strategy to prevent sepsis and meningitis and to save the patient in such cases.

References

- Joo JO, Lee SJ, Hong SH, et al. The infection after augmentation rhinoplasty using silicone implant. *J Korean Soc Aesthetic Plast Surg* 2007;13:133-8.
- Cohen BJ, Johnson JD, Raff MJ. Septoplasty complicated by staphylococcal spinal osteomyelitis. *Arch Intern Med* 1985;145:556-7.
- Bae SY, Park MS. Bacterial meningitis and cerebrospinal fluid rhinorrhea related to rhinoplasty. *J Korean Neurol Assoc* 2012;30:232-4.
- Angus DC, van der Poll T. Severe sepsis and septic shock. *N Engl J Med* 2013;369:840-51.