

- in nevus sebaceus: a study of 596 cases. *J Am Acad Dermatol* 2000;42:263-8.
2. Laffay L, Depaep L, d'Hombres A, et al. Histological features and treatment approach of trichoblastic carcinomas: from a case report to a review of the literature. *Tumori* 2012;98:46e-49e.
  3. Ayhan M, Gorgu M, Aytug Z, et al. Trichoblastic carcinoma of the alar region: a case report. *Dermatol Surg* 2006;32:976-9.
  4. Cowen EW, Helm KF, Billingsley EM. An unusually aggressive trichoblastoma. *J Am Acad Dermatol* 2000;42:374-7.
  5. Harari PM, Shimm DS, Bangert JL, et al. The role of radiotherapy in the treatment of malignant sweat gland neoplasms. *Cancer* 1990;65:1737-40.

## Bilateral Atypical Ductal Hyperplasia with Microcalcifications in a Patient with Gynecomastia

Pedro Vidal<sup>1</sup>, Juan Enrique Berner<sup>1</sup>, Alejandra Klenner<sup>1</sup>, Óscar Tapia<sup>2,3</sup>

<sup>1</sup>Clinica La Parva, Instituto Clínico White, Santiago; <sup>2</sup>Citolab Laboratory, Santiago; <sup>3</sup>Universidad de La Frontera, Temuco, Chile

**Correspondence:** Pedro Vidal  
Clínica La Parva, Instituto Clínico White, Av. Las Condes 13.305, Santiago, Chile  
Tel: +56-2-2207-1125, E-mail: pvidalg@mac.com

This study was presented at the 12th Chilean Congress of Breast Surgery on September 27th–29th, 2015, in Pucon, Chile.

No potential conflict of interest relevant to this article was reported.

Received: 1 Dec 2015 • Revised: 20 Jan 2016 • Accepted: 7 Feb 2016  
pISSN: 2234-6163 • eISSN: 2234-6171  
<http://dx.doi.org/10.5999/aps.2016.43.3.299>  
*Arch Plast Surg* 2016;43:299-301



Copyright © 2016 The Korean Society of Plastic and Reconstructive Surgeons  
This is an Open Access article distributed under the terms of the Creative Commons Attribution Non-Commercial License (<http://creativecommons.org/licenses/by-nc/4.0/>) which permits unrestricted non-commercial use, distribution, and reproduction in any medium, provided the original work is properly cited.

The incidence of male breast cancer is far lower than that of breast cancer in female patients, and usually has a worse prognosis. The incidental discovery of breast cancer in patients undergoing surgery for gynecomastia is rare, but has previously been reported by several authors [1]. However, bilateral atypical ductal hyperplasia in men is far less frequent, and this is the first report to describe the occurrence of this finding with associated microcalcifications in

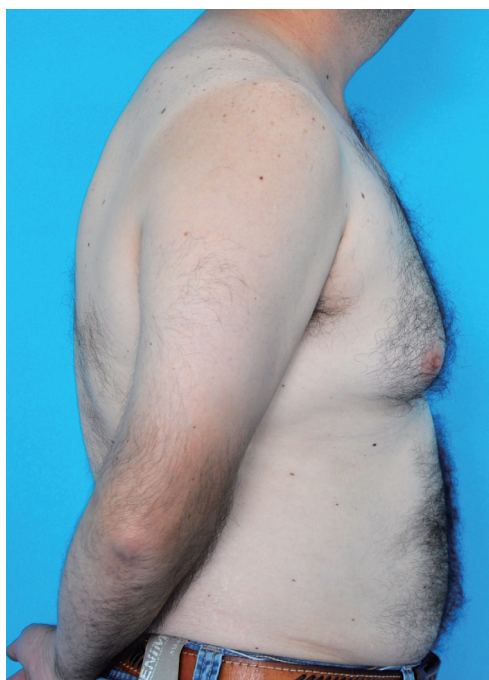the histopathological analysis.

We present the case of a 39-year-old male patient who attended a plastic surgery consultation complaining of long standing bilateral gynecomastia (Fig. 1). He had no personal history of any significant medical conditions or family history of breast cancer. He also denied the use of medication and recreational drugs. Physical examination revealed bilateral breast enlargement with palpable glandular tissue below and surrounding the nipple-areolar complex, with adjacent fat tissue. A testicular examination was normal.

Routine preoperative laboratory tests did not show any alterations in transaminase, plasma creatinine, or thyroid hormone levels. The presence of bilateral glandular breast tissue was confirmed using ultrasound imaging.

A combined technique was used to correct this patient's gynecomastia by performing tumescent liposuction of the thorax followed by transareolar resection of the breast tissue. The operation was uneventful, with 45 g of glandular tissue on the left side and 23 g on the right side. The surgical outcome and the patient's postoperative course were satisfactory, and he was discharged the following day without further complications (Fig. 2).

The histopathological analysis reported several samples in which stromal fibrosis with hyaline parts was found. Irregular ductal structures were identified, inlaid with hyperplastic epithelium following a



**Fig. 1.**  
Preoperative photograph with evident breast enlargement.

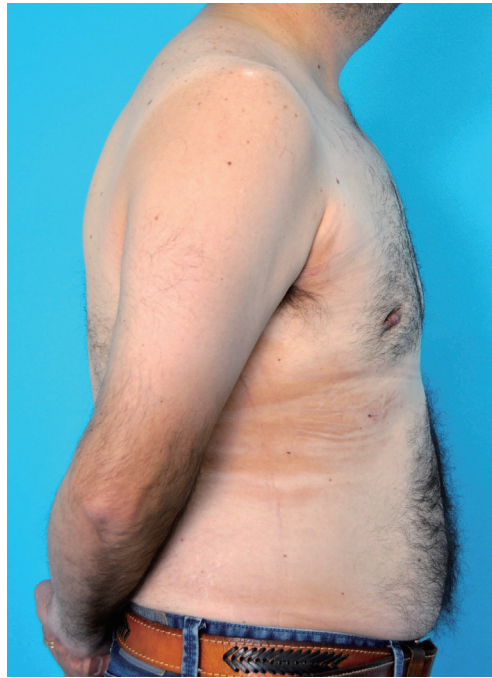cribriform pattern. The cells contained hyperchromatic, pleomorphic, and enlarged nuclei with minimal overlying and well-defined cytoplasmic borders. Some calcium carbonate microcalcifications were also identified in both samples. No evidence of intraductal or invasive neoplasia was found (Fig. 3).

Male breast cancer accounts for 1% of all cases of breast cancer. Although no causal relationship between gynecomastia and male breast cancer has been shown, it is a common association. Up to 40% of patients with male breast cancer present with gynecomastia, most likely because elevated estrogen levels are present in both conditions [1]. Due to its lower prevalence, screening for male breast cancer in

the general population it is not advised. However, imaging tests are an important part of the preoperative evaluation of patients with gynecomastia, not just for screening purposes but also to differentiate between true gynecomastia and pseudogynecomastia. Although mammography is widely available and has a specificity and sensibility of greater than 90% for finding malignancies in the male breast, it is usually uncomfortable and poorly tolerated by men with mild breast enlargement. Ultrasound is a reliable alternative that does not involve those disadvantages of mammograms, and has the advantage of allowing ultrasound-guided biopsies if needed [2].

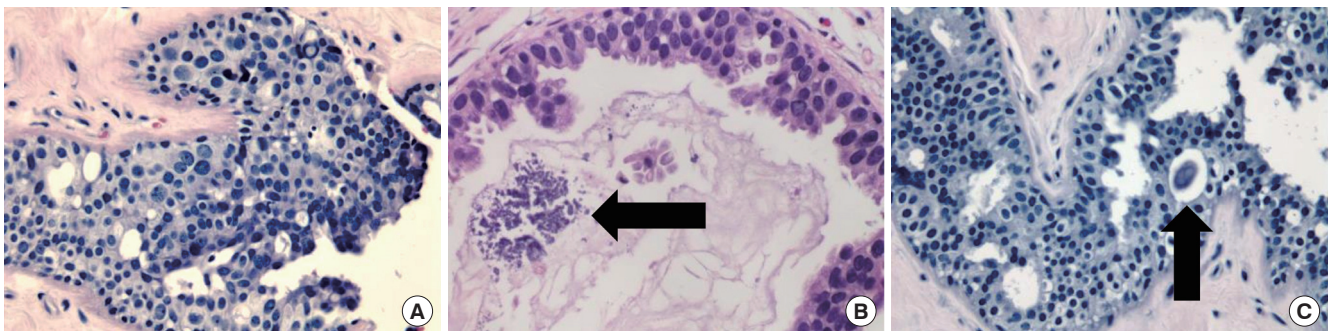
Atypical ductal hyperplasia is a disorder that increases the risk of suffering from both ipsilateral and contralateral breast cancer by up to five times in female patients. It is usually found incidentally in biopsies of suspicious mammographic abnormalities. The current recommendations are to provide advice about cancer risk reduction strategies to female patients suffering from this condition. Breast examinations every six months and yearly mammography are indicated, along with the avoidance of oral contraceptives and hormone replacement therapy.

Microcalcifications are not a rare phenomenon, as they are associated with a wide range of breast conditions, such as benign, precancerous, and cancerous lesions. The presence of microcalcifications aids in the histopathological diagnosis of female breast biopsies because they are associated with comedonecrosis in intraductal neoplasms [3]. Furthermore, core biopsies with microcalcifications are more likely to be reported as cancer than are samples without microcalcifications.



**Fig. 2.**

Postoperative photographs six weeks after surgery. Although the swelling had not completely resolved at this stage, the satisfactory nature of the results can be appreciated.



**Fig. 3.**

(A) Hematoxylin and eosin (H&E)-stained section in which ductal structures can be identified following a cribriform pattern, with cells showing varied degrees of atypia ( $\times 100$ ). (B, C) Microcalcifications (black arrows) can be seen as groups of granular basophilic material inside the lumen of the previously described mammary ductal structures (B,  $\times 400$ ; C,  $\times 100$ , respectively).

To our knowledge, this is the first report of atypical ductal hyperplasia with microcalcifications in a male patient [4]. Consequently, insufficient evidence exists to support the hypothesis that this condition is a risk factor for male breast cancer, as it is for females. This explains why no current recommendations exist for the care of these patients. In the case presented in this article, the patient was referred to a breast cancer specialist for annual follow-ups with ultrasound imaging.

Without the routine histopathological analysis of the resected specimens from gynecomastia surgery, it would have been impossible to detect this premalignant condition. This standard of practice is of the foremost importance not just for this reason, but also in order to accurately diagnose male breast cancer as early as possible in a larger number of patients.

## References

1. Mathew J, Perkins GH, Stephens T, et al. Primary breast cancer in men: clinical, imaging, and pathologic findings in 57 patients. *AJR Am J Roentgenol* 2008;191:1631-9.
2. Draghi F, Tarantino CC, Madonia L, et al. Ultrasonography of the male breast. *J Ultrasound* 2011;14:122-9.
3. Cheung YC, Juan YH, Ueng SH, et al. Assessment of breast specimens with or without calcifications in diagnosing malignant and atypia for mammographic breast microcalcifications without mass: a STARD-compliant diagnostic accuracy article. *Medicine (Baltimore)* 2015;94:e1832.
4. Wells JM, Liu Y, Ginter PS, et al. Elucidating encounters of atypical ductal hyperplasia arising in gynaecomastia. *Histopathology* 2015;66:398-408.

## Acute Calcific Tendinitis in the Distal Interphalangeal Joint

Jong Ho Kim<sup>1</sup>, Jong Ho Lee<sup>1</sup>, Ji Ung Park<sup>2</sup>, Sung Tack Kwon<sup>1</sup>

<sup>1</sup>Department of Plastic and Reconstructive Surgery, Seoul National University College of Medicine, Seoul; <sup>2</sup>Department of Plastic and Reconstructive Surgery, Seoul National University Boramae Medical Center, Seoul, Korea

**Correspondence:** Ji Ung Park  
Department of Plastic and Reconstructive Surgery, Seoul National University Boramae Medical Center, Seoul National University College of Medicine, 20 Boramae-ro 5-gil, Dongjak-gu, Seoul 07061, Korea  
Tel: +82-2-870-2332 Fax: +82-2-831-2826  
E-mail: alfbskan@gmail.com

This material was presented at the 71st International Congress of the Korean Society of Plastic and Reconstructive Surgeons on November 1, 2013 in Seoul, Korea.

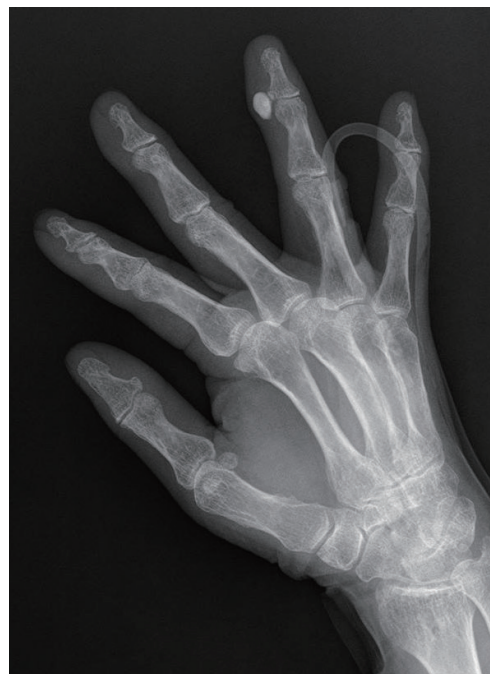No potential conflict of interest relevant to this article was reported.

Received: 9 Jun 2015 • Revised: 7 Jul 2015 • Accepted: 14 Jul 2015  
pISSN: 2234-6163 • eISSN: 2234-6171  
<http://dx.doi.org/10.5999/aps.2016.43.3.301>  
*Arch Plast Surg* 2016;43:301-303



Copyright © 2016 The Korean Society of Plastic and Reconstructive Surgeons  
This is an Open Access article distributed under the terms of the Creative Commons Attribution Non-Commercial License (<http://creativecommons.org/licenses/by-nc/4.0/>) which permits unrestricted non-commercial use, distribution, and reproduction in any medium, provided the original work is properly cited.

Acute calcific tendinitis is a form of acute inflammation of the tendon, causing severe pain, swelling, and limited joint motion, and is characterized by radiologic evidence of periarticular calcification. The pathogenesis is not clear, but some



**Fig. 1.** The initial radiographs showed an ovoid calcification on the radial collateral ligament of the distal interphalangeal joint of the left fourth finger.