

The Oncological Safety of Nipple-Sparing Mastectomy: A Systematic Review of the Literature with a Pooled Analysis of 12,358 Procedures

Hannah Louise Headon¹, Abdul Kasem², Kefah Mokbel¹

¹Department of Oncoplastic Breast Surgery, London Breast Institute, Princess Grace Hospital, London; ²Department of Oncoplastic Breast Surgery, Medway NHS Trust, Medway, UK

Nipple-sparing mastectomy (NSM) is increasingly popular as a procedure for the treatment of breast cancer and as a prophylactic procedure for those at high risk of developing the disease. However, it remains a controversial option due to questions regarding its oncological safety and concerns regarding locoregional recurrence. This systematic review with a pooled analysis examines the current literature regarding NSM, including locoregional recurrence and complication rates. Systematic electronic searches were conducted using the PubMed database and the Ovid database for studies reporting the indications for NSM and the subsequent outcomes. Studies between January 1970 and January 2015 (inclusive) were analysed if they met the inclusion criteria. Pooled descriptive statistics were performed. Seventy-three studies that met the inclusion criteria were included in the analysis, yielding 12,358 procedures. After a mean follow up of 38 months (range, 7.4–156 months), the overall pooled locoregional recurrence rate was 2.38%, the overall complication rate was 22.3%, and the overall incidence of nipple necrosis, either partial or total, was 5.9%. Significant heterogeneity was found among the published studies and patient selection was affected by tumour characteristics. We concluded that NSM appears to be an oncologically safe option for appropriately selected patients, with low rates of locoregional recurrence. For NSM to be performed, tumours should be peripherally located, smaller than 5 cm in diameter, located more than 2 cm away from the nipple margin, and human epidermal growth factor 2-negative. A separate histopathological examination of the subareolar tissue and exclusion of malignancy at this site is essential for safe oncological practice. Long-term follow-up studies and prospective cohort studies are required in order to determine the best reconstructive methods.

Keywords Mastectomy / Breast neoplasm / Recurrence

Correspondence: Kefah Mokbel
Department of Oncoplastic Breast
Surgery, The London Breast Institute,
Princess Grace Hospital, 42-52
Nottingham Place, London, UK
Tel: +44-207-908-2040
Fax: +44-207-908-2275
E-mail: kefahmokbel@hotmail.com

No potential conflict of interest relevant to this article was reported.

Received: 26 May 2015 • Revised: 18 May 2016 • Accepted: 24 May 2016
pISSN: 2234-6163 • eISSN: 2234-6171 • <http://dx.doi.org/10.5999/aps.2016.43.4.328> • Arch Plast Surg 2016;43:328-338

INTRODUCTION

In recent decades, advances in breast surgery and reconstruction have led to significant improvements in the quality of life for many patients who have undergone surgery for breast cancer.

Although breast-conserving surgery has remained the treatment of choice for many, up to a third of patients still require, or request, a mastectomy in order to achieve local disease control. Currently, the indications for mastectomy include cases of invasive breast cancer (IBC) or ductal carcinoma *in situ* (DCIS) that

are not amenable to breast-conserving surgery for a number of reasons, such as the size or distribution of disease, the possibility of a poor cosmetic outcome, local recurrence, contraindications to radiotherapy, or patient preference.

The primary aim of surgical intervention in breast cancer is to achieve optimal local disease control, although secondary aims have emerged, such as good cosmetic outcomes and high patient satisfaction. Mastectomy techniques have evolved from radical and modified mastectomy towards surgical methods that facilitate reconstruction and tend to lead to good cosmetic outcomes: the standard skin-sparing mastectomy (SSM) and, more recently, the nipple-sparing mastectomy (NSM).

Despite its advantages in terms of aesthetic outcomes, the use of NSM is controversial due to concerns regarding its oncological safety based on early reports of high rates of nipple malignancy, potentially leading to increased recurrence rates. However, more recent reports have suggested that the earlier studies may have exaggerated the risk [1]. Although patient satisfaction with the aesthetic outcome and oncological safety have historically been regarded as competing interests, more recently these two aims have evolved to become common goals and are no longer considered mutually exclusive outcomes, given appropriate patient selection. NSM is one such surgical option, designed to allow the local control of disease whilst optimising the cosmetic outcome. In NSM, the mammary tissue is removed, whilst the skin envelope and nipple-areola complex (NAC) are preserved. Preserving the NAC has been reported to be associated with multiple benefits, including better aesthetic outcomes, improved patient satisfaction, and psychosexual benefits, and its removal may, in selected cases, be an instance of overtreatment [2]. Additionally, leaving the NAC *in situ* can facilitate immediate breast reconstruction [3].

Currently, no universally agreed-upon criteria are used for patient selection for NSM. The suggested parameters include early-stage IBC (stage I to stage II) or DCIS where the tumour has a diameter smaller than 5 cm, is peripherally placed more than 2 cm from the areola, is oestrogen- and progesterone-positive and human epidermal growth factor-2 (HER2)-negative, with no evidence of multifocal or multicentric disease and no lymphovascular invasion [4]. The purpose of this study was to systematically review the literature in order to determine the rate of locoregional recurrence (LR) [5] following NSM as well as to determine the rates of overall complications and nipple necrosis in order to update standards of clinical practice when considering NSM.

METHODS

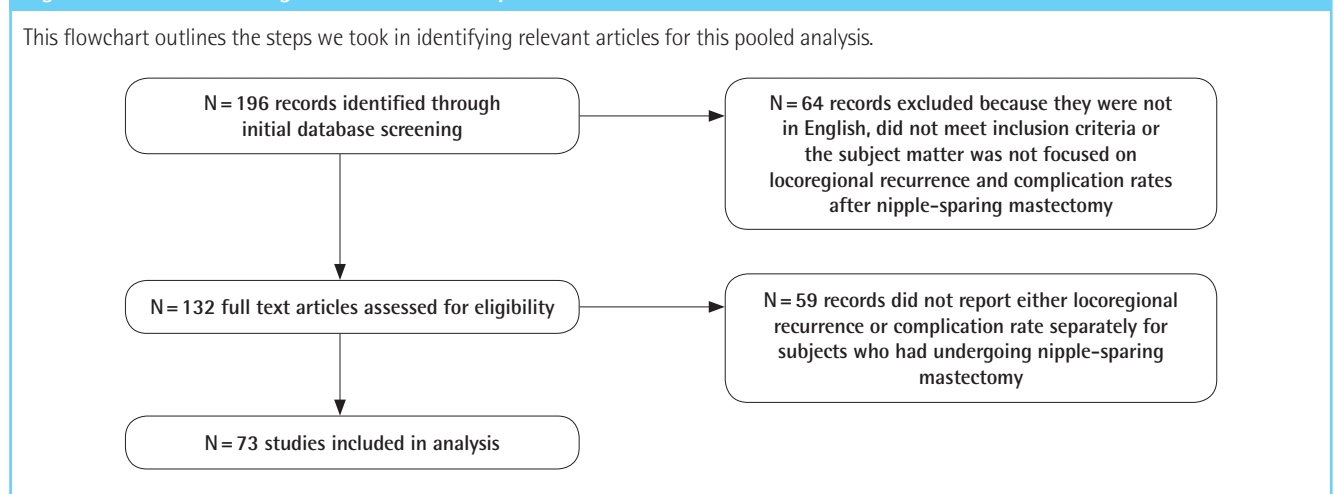
Search methodology

Electronic searches were performed using the PubMed and Ovid databases for studies evaluating NSM. The search terms that were used included 'nipple sparing mastectomy' and 'total skin sparing mastectomy' along with 'locoregional recurrence' and 'outcomes.' All studies published from January 1970 to January 2015 were reviewed and the references of appropriate articles were also evaluated for further relevant studies.

Selection criteria

The inclusion and exclusion criteria were defined before data collection was initiated. Studies that evaluated outcomes following NSM were included. All forms of reconstruction were included. All studies must have clearly defined whether patients underwent NSM or SSM; if this was unclear, the article was not included. In articles where both SSM and NSM were reviewed, the article was required to clearly state the outcomes of the NSM

Fig. 1. Flowchart outlining literature selection process



cohort separately. Retrospective and prospective studies were included. Fig. 1 outlines the selection process. Studies were excluded if they did not report appropriate outcomes as stated, if they did not specify the number of patients and the number of procedures involved, were not printed in English, or were reports, commentaries, reviews or letters.

Data collection and analysis

The following data were collected: authors, study name, publication year, location of the study, journal of publication, type of study, number of patients, number of procedures, inclusion criteria for NSM, type of reconstruction, number of overall complications, nipple necrosis, LR, and aesthetic results. The pooled analysis of the rate of LR, the nipple necrosis rate, and the rate of overall complications was performed based on the number of patients included in each study. The primary outcome measures were the rate of overall LR recurrence, the overall complication rate, and the overall rate of nipple necrosis.

RESULTS

Seventy-three studies [5-76] reported LR rates, complication rates, and/or nipple necrosis rate following NSM. Table 1 presents the number of patients, the number of procedures, the LR rate, the complication rate, and the nipple necrosis rate. Almost all of the studies were retrospective (91%). The 73 studies yielded 12,358 procedures in 10,935 patients, and the indications included invasive breast cancer, risk-reduction surgery, and carcinoma *in situ*. The mean follow-up period was 38.3 months, with a range of 7.9–156 months. Pooled analysis demonstrated an overall LR rate of 2.38%, slightly higher than that found by Endara et al. [77] in 2013. The overall complication rate was 22% and the nipple necrosis rate was 5.9%, both lower than the rates found by Endara and colleagues. The majority of studies were published after 2011, reflecting the increasing popularity of NSM over time. A small subgroup analysis was carried out examining the average complication rates before and after 2013, and the results of this are shown in Fig. 2. A clear reduction was observed in the complication rate and the incidence of nipple necrosis after 2013.

DISCUSSION

According to our pooled analysis, NSM may be an oncologically safe surgical treatment in carefully selected patients with breast cancer, as we found a low pooled LR rate of 2.38%, which is comparable to that found for conventional mastectomy, for which the LR rates have been reported to be as high as 16% [4]. It

can also lead to improved aesthetic outcomes with minimal scarring when combined with reconstruction. The main oncological concern with NSM is the possibility of leaving residual tumour cells within the skin envelope, which may manifest later as LR.

Histological studies following conventional mastectomy have reported residual glandular tissue in 5% of all biopsies, indicating that more radical surgery may not be guarantee of complete clearance [78]. In SSM performed in patients with invasive breast cancer, the prevalence of residual breast tissue has been reported to be as high as 59.5%, with residual disease in 9.5% [79], a finding echoed by Ho et al. [80], who reported that skin flaps exhibited residual malignancy in 23% of cases, most commonly in the skin overlying the tumour. However, a large systematic review from 2012 reported that the overall incidence rate of LR was only 0.9% after a mean follow-up of 38.4 months and that the skin flap recurrence rate was 4.2% following SSM [4], which was much lower than had been reported in single-centre studies.

The concern has been raised that leaving the NAC *in situ* could provide another site for possible recurrence. We have found a low LR rate, which corresponds to the findings of long-term single-centre studies. Stanec et al. [65] found an LR rate of 3.7% in the breast and 1.2% in the NAC after a mean follow-up of 63 months. Other studies have found no cases of NAC recurrence [48,69]. Most recently, Sakurai et al. [55] followed up 788 patients who underwent NSM for an average of 78 months, and reported an NAC relapse rate of 3.7% and an LR rate of 8.2%, stating that no significant difference was found in overall survival and disease-free survival between NSM patients and conventional mastectomy patients at 21 years.

Tumour size is a parameter that has been used in the past to select suitable patients for NSM. In the studies analysed that included data on tumour size, the largest recorded was an average of 3.4 ± 2.2 cm, which showed a 10.3% LR rate over an 18-month follow up [56]. More recently, Leclere et al. [67] reported a 5.3% LR rate in 41 cases, 18 of which involved a tumour size larger than 3 cm. Moreover, it appears that as NSM becomes more popular, the number of patients with larger tumours undergoing NSM is steadily increasing, as described by Agarwal et al. [81]. They found that although 50% of patients had tumours less than 2 cm in diameter, the number of patients with tumours larger than 2 cm undergoing NSM increased over time, perhaps because as surgeons have become more familiar and confident with the technique, it has been possible to widen the clinical indications for which NSM can be considered as a management option. The currently available data therefore appear to support the use of NSM even with larger tumours, although more long-term follow-up studies with larger populations are required in order to ensure that the risk of LR is minimised.

Table 1. Characteristics of the included studies, with the locoregional recurrence rate (LRR), overall complication rate, and nipple necrosis rate

References	Study type	No. of patients	No. of procedures	Type of reconstruction	Follow-up time (mo, mean)	LRR (%)	Complications (%)	Nipple necrosis (%)
Verheyden 1998 [5]	Retrospective	20	30	Tissue expander/implant	75.5 (mean, range 3–126)	0 (0)	24 (80)	11 (36)
Mustonen et al. 2004 [6]	Retrospective	34	34	Direct to implant, tissue expander/implant, autologous tissue	45.6 (mean, range 28.8–69.6)	4 (11.8)	23 (67.6)	6 (17.6)
Dao et al. 2005 [7]	Retrospective	16	32	Autologous tissue	-	-	12 (37.5)	0 (0)
Margulies et al. 2005 [8]	Retrospective	31	50	Tissue expander/implant	7.9 (mean, range 0.2–20.2)	0 (0)	9 (18)	7 (14)
Palmeri et al. 2005 [9]	Retrospective	18	25	Direct to implant, tissue expander/implant	21 (mean, range 6–52)	0 (0)	1 (4)	1 (4)
Caruso et al. 2006 [10]	Prospective	50	51	Implant, autologous tissue	66 (mean, range 9–140)	1 (1.9)	4 (8)	2 (4)
Komorowski et al. 2006 [11]	Retrospective	38	38	Direct to implant, tissue expander/implant	-	-	-	5 (13.1)
Mosahebi et al. 2007 [12]	Retrospective	71	71	Direct to implant, autologous tissue	48 (mean, range 8–109)	0 (0)	-	-
Denerer and Farouk 2007 [13]	Retrospective	41	41	Autologous tissue	7.9 (mean, range 4–11)	0 (0)	11 (26.8)	1 (2.4)
Crowe et al. 2008 [14]	Prospective	110	149	Implant, autologous tissue	-	-	-	2 (1.5)
Benediktsson and Perbeck 2008 [15]	Prospective	272	272	-	156 (median, range 2.4–210)	52 (19.1)	-	-
Sookhan et al. 2008 [16]	Retrospective	20	20	Implant	10.8 (mean)	0 (0)	3 (15)	2 (10)
Regolo et al. 2008 [17]	Retrospective	70	102	Direct to implant, tissue expander and implant	16 (mean)	0 (0)	-	-
Voltura et al. 2008 [18]	Retrospective	36	51	Autologous tissue	18 (mean, range 2–68)	2 (3.9)	-	-
Wijayanayagam et al. 2008 [19]	Prospective	43	64	Direct to implant, tissue expander/implant, autologous tissue	-	-	23 (36)	2 (4.7)
Stoiler et al. 2008 [20]	Prospective	58	82	Direct to implant, autologous tissue	-	-	10 (7.2)	0 (0)
Paepke et al. 2009 [21]	Prospective	96	109	Autologous tissue/implant	34 (median)	1 (0.91)	-	27 (25)
Garcia-Etienne et al. 2009 [22]	Retrospective	25	42	Implant	10.5 (median, range 0.4–56.4)	0 (0)	6 (14)	3 (7.1)
Gerber et al. 2009 [23]	Retrospective	60	60	Autologous tissue	-	-	-	-
Petit et al. 2009 [24]	Prospective	1,001	1,001	Direct to implant	20 (median, range 1–69)	14 (1.4)	358 (35.8)	90 (9)
Chen et al. 2009 [25]	Retrospective	66	115	Direct to implant, tissue expander/implant	-	-	-	25 (21.7)
Yueh et al. 2009 [26]	Prospective	10	17	Direct to implant, tissue expander/implant, autologous tissue	-	-	12 (70.6)	3 (17.6)
Garwood et al. 2009 [27]	Prospective	72	106	Direct to implant, tissue expander/implant, autologous tissue	13 (median, range 1–65)	1 (0.9)	-	17 (10.4)
Sakamoto et al. 2009 [28]	Retrospective	87	89	-	52 (median)	0 (0)	-	16 (18)
Colwell et al. 2010 [29]	Retrospective	8	14	Direct to implant	-	-	1 (12.5)	0 (0)
Radovanovic et al. 2010 [30]	Prospective	205	214	Direct to implant	-	-	35 (16)	9 (4.5)
Kim et al. 2010 [31]	Prospective	152	152	Autologous tissue	60 (median)	3 (2)	40 (22.6)	40 (22.6)
Luo et al. 2010 [32]	Retrospective	52	52	-	-	-	-	-
Saigarello et al. 2010 [33]	Retrospective	33	42	Direct to implant	-	-	10 (23.8)	4 (9.5)
Mladenov et al. 2010 [34]	Retrospective	52	57	Direct to implant	2–36	0 (0)	-	13 (22.8)
Rawiani et al. 2011 [35]	Retrospective	20	37	Direct to implant	-	-	16 (43.2)	9 (24.3)
Spear et al. 2011 [36]	Retrospective	101	162	Direct to implant, autologous tissue	36.5 (mean, range 5–243)	0 (0)	46 (28.4)	7 (4.3)
Harness et al. 2011 [37]	Retrospective	43	60	Direct to implant	18.5 (mean, range 6–62)	1 (1.7)	12 (20)	5 (8.3)
de Alcantara Filho et al. 2011 [38]	Retrospective	200	353	Implant, autologous tissue	10.38 (median, range 0–109)	0 (0)	90 (25.5)	12 (3.3)
Jensen et al. 2011 [39]	Prospective	99	149	Tissue expander/implant, autologous tissue	60.2 (median, range 12–144)	3 (2.01)	9 (6)	8 (6.3)
Boneti et al. 2011 [40]	Retrospective	-	281	Direct to implant, tissue expander/implant	25.3 (mean, range 3–102)	7 (2.5)	20 (7.1)	-
Yang et al. 2012 [41]	Prospective	92	92	Autologous tissue	18.1 (mean, range 5–34 months)	0 (0)	-	12 (13)
Schneider et al. 2012 [42]	Retrospective	19	34	Autologous tissue	-	-	2 (5.8)	1 (2.9)
Spear et al. 2012 [43]	Retrospective	15	24	Direct to implant	13 (mean)	0 (0)	10 (41.6)	7 (29)
Jensen et al. 2012 [44]	Prospective	20	313	Direct to implant, tissue expander/implant, autologous tissue	-	-	-	-
Kneubil et al. 2012 [45]	Retrospective	-	948	-	64 (median, range 18–113)	10 (1.05)	-	-
Peled et al. 2012 [46]	Prospective	288	450	Tissue expander/implant	-	-	252 (56)	4 (0.9)

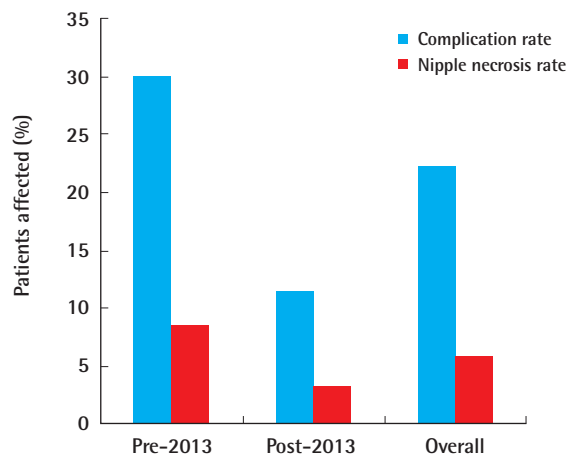
(Continued to the next page)

Table 1. Continued

References	Study type	No. of patients	No. of procedures	Type of reconstruction	Follow-up time (mo, mean)	LRR (%)	Complications (%)	Nipple necrosis (%)
Moyer et al. 2012 [47]	Retrospective	26	40	Direct to implant, tissue expander/implant, autologous tissue	-	-	16 (40)	15 (37.5)
Warren Peled et al. 2012 [48]	Prospective	428	657	Direct to implant, tissue expander/implant, autologous tissue	28 (median, range 3–116)	4 (0.6)	-	23 (3.5)
Algaithry et al. 2012 [49]	Prospective	45	50	Direct to implant, tissue expander/implant	-	-	-	13 (25)
Wagner et al. 2012 [50]	Prospective	33	54	Direct to implant, tissue expander/implant, autologous tissue	15 (median, range 1–29)	0 (0)	-	16 (29.6)
Blechman et al. 2013 [51]	Retrospective	29	55	Direct to implant	-	-	-	3 (6)
Tanna et al. 2013 [52]	Retrospective	51	85	Autologous tissue	-	-	-	11 (12.9)
Lohsirivat et al. 2013 [53]	Retrospective	934	934	Direct to implant, tissue expander/implant, autologous tissue	64 (median, range 18–113)	0 (0)	-	40 (4.3)
Sahin et al. 2013 [54]	Retrospective	21	41	Direct to implant	-	-	8 (19)	0 (0)
Sakurai et al. 2013 [55]	Retrospective	788	788	-	78 (median)	65 (8.2)	-	0 (0)
Fortunato et al. 2013 [56]	Retrospective	121	138	Immediate, expanders, prostheses, autologous flaps	28 (median)	1 (0.72)	-	25 (18.1)
Burdge et al. 2013 [57]	Retrospective	527	558	Immediate with prostheses or delayed two stage	18 (median)	4 of 39 (10.3)	93 (16.7)	-
Rulli et al. 2013 [58]	Retrospective	77	87	-	50.3 (mean)	3 (3.3)	-	4 (4.6)
Romics et al. 2013 [59]	Retrospective	253	253	Immediate reconstruction	112 (median)	21 (8.2)	-	-
Munhoz et al. 2013 [60]	Retrospective	158	158	-	65.6 (mean)	6 (3.7)	-	-
Coopey et al. 2013 [61]	Retrospective	370	645	-	22 (mean)	4 of 156 therapeutic cases (2.6)	-	11 (1.7)
Tancredi et al. 2013 [62]	Retrospective	55	55	Immediate reconstruction	21.7 (mean, range 3–55)	2 (3.6)	8 (14.5)	2 (3.6)
Chen et al. 2013 [63]	Retrospective	56	56	Both immediate and delayed	40 (median, range 14–88)	0 (0)	5 (8.9)	0 (0)
Colwell et al. 2014 [64]	Retrospective	285	500	Direct to implant, tissue expander/implant, autologous tissue	2.17 yr (mean)	-	62 (12.4)	22 (4.4)
Stanev et al. 2014 [65]	Retrospective	252	252	Varied	63 (median, range 1–180)	6 (5.5)	-	29 (10.1)
Chattopadhyay et al. 2014 [66]	Prospective	34	34	Immediate, autologous tissue, silicone implants	28.5 (median, range 18–38)	0 (0)	3 (8.8)	1 (2.9)
Leclere et al. 2014 [67]	Retrospective	41	41	Immediate, prostheses, tissue expander or autologous tissue	7.1 ± 2.9 yr (mean, range 2–13 yr)	1 (5.3)	-	9 (22)
Eisenberg et al. 2014 [68]	Retrospective	215	325	-	33 (median)	1 (0.31)	-	-
Wang et al. 2014 [69]	Retrospective	633	981	Immediate reconstruction	29 (median)	19 (3)	113 (11.6)	10 (1)
Kim et al. 2016 [70]	Retrospective	19	19	-	22.4 (mean)	1 (5.3)	-	-
Adam et al. 2014 [71]	Retrospective	67	69	Immediate implant based reconstruction	36 (median, range 4–162)	0 (0)	-	-
Huston et al. 2014 [72]	Retrospective	318	318	Implant based reconstruction	505 day (mean, range 7–1,504 day)	3 (2.5)	-	10 (8.2)
Sood et al. 2014 [73]	Retrospective	87	118	-	30 (median)	4 (3.4)	-	-
Peled et al. 2014 [74]	Retrospective	106	212	-	37 (mean)	1/27 therapeutic cases (3.7)	-	-
Poruk et al. 2015 [75]	Retrospective	130	205	-	25.08+18 (mean)	2 (0.1)	-	-
Yao et al. 2015 [76]	Retrospective	201	397	-	32.6 (mean)	4 (1)	10 (2.5)	7 (1.8)
Totals		10,935	12,358	-	-	254/10676 (2.38)	1,357/6,091 (22.3)	602/10,143 (5.9)

Fig. 2. Average rates of complications and nipple necrosis

This bar chart shows the difference in average complication rates and the incidence of nipple necrosis in studies published before 2013 and in those published in 2013 and after. The blue bars indicate the complication rate as a percentage, whereas the red bars indicate the nipple necrosis rate as a percentage. A clear reduction in both the complication rate and the incidence of nipple necrosis is present when comparing studies published before 2013 and those published after 2013. The mean complication rate in articles published before 2013 was 29.98%, whereas in those published in 2013 and after, it was 11.5%. The mean nipple necrosis rate in articles published before 2013 was 8.7%, compared to 3.4% in those published in 2013 and after. This may reflect the increased confidence of surgeons and improved surgical technique as this procedure has become more widely accepted.



Another selection parameter that has been suggested is a tumour-to-nipple distance no smaller than 2 cm. Currently, when performing an NSM, a frozen section of the retroareolar tissue is required for intraoperative histological analysis in order to verify that the borders of the NAC are clear of disease. A recent study by Chattopadhyay et al. [66] found a 0% LR rate after 28.5 months in patients with a median tumour-to-nipple distance of 3.8 cm. This low LR rate is echoed by Fortunato et al. [56], who found an LR rate of less than 1% after 26 months, despite a tumour-to-nipple distance of just 1 cm in 65% of cases suggesting that previous guidelines requiring a minimum distance of 2 cm may be outdated for carefully selected patients. In order to preoperatively evaluate the tumour-to-nipple distance, it has been suggested that patients undergo magnetic resonance imaging (MRI) before surgery as a way of predicting who would be suitable for NSM. Moon et al. [82] found a significant correlation between NAC enhancement on MRI and malignant invasion of the NAC, reporting a sensitivity of 93.8% and a specificity of 85.7%, indicating that presurgical MRI may be useful in selecting appropriate patients. However, not all authors agree on the use of MRI, meaning that a combined approach, utilising both clinical evaluation and imaging techniques, may be best when determining

patient suitability for NSM.

The tumour location within the breast is also considered an important parameter when assessing suitability for NSM, as centrally located tumours have been reported to be significantly associated with nipple margin involvement: one study found that centrally located tumours were associated with residual malignancy of the NAC in 40% of cases [68]. Most studies reporting on tumour location support this proposal [4,83]. Mallon et al. [4], in their large systematic review, stated that a retroareolar or central location was a factor influencing occult nipple malignancy, with an overall incidence of 35.2%, compared to only 9.7% for peripherally located tumours. One study suggested that tumour location was the most important parameter in predicting NAC involvement, as only centrally located tumours showed a significant association with nipple involvement [83]. A retrospective study of 219 mastectomies demonstrated that peripheral tumours were found to involve the NAC in only 2.5% of cases, whereas for centrally located lesions the incidence was 68% [84]. In contrast, a recent small study of 28 patients concluded that NSM was an oncologically safe procedure regardless of tumour location [85]. More research is required in larger cohorts before central tumours can be deemed safe for NSM.

The histological subtype of the breast cancer may also have an impact on the LR rate after NSM. A systematic review suggested that the overall LR rate for invasive ductal carcinoma was 14.9%, whilst for DCIS it was 15.3%. The highest LR rate was for invasive lobular carcinoma, with an LR rate of 17.2% [4]. Recently, a study of 934 patients also investigated the LR rate of different histological types with a mean follow-up of 50 months, and found a 3.6% LR rate in the breast and a 0.8% recurrence rate in the NAC in patients who had had invasive carcinoma compared to a 4.9% LR rate in the breast and a 2.9% recurrence rate in the NAC in those who had had intraepithelial neoplasia, supporting the proposal that histological subtype may be an important factor when considering the suitability of NSM [86]. However, Kneubil et al. [45] found that having DCIS as a primary tumour was a significant predictor of NAC recurrence, although the LR rate was still acceptably low at 8.7%. Overall, the evidence regarding the impact of histological type on LR rate is scarce, and currently no adequate study has evaluated the differences in LR between all the different histological subtypes.

A further parameter that has been highlighted is the tumour receptor status, with tumours that are HER2-negative and oestrogen receptor-(ER) and progesterone receptor (PR)-positive having the best outcomes following NSM. Mallon et al. [4] found a significant increase in the LR rate in HER2-positive patients, with an overall incidence of 19.7%, compared to 10.1% in HER2-negative patients. Additionally, ER positivity was found to be

protective, with an overall LR rate of 10.8%, compared to 14% in ER-negative patients, a trend also echoed by PR positivity. More recent studies have found similar results. A positive HER2 status has been consistently found to influence LR rates, and most authors agree that HER2 positivity should rule out NSM as an option for surgical management [86]. Petit et al. [86] found in their study that out of 11 patients that had LR, 9 exhibited HER2 overexpression, indicating a strong correlation between HER2 and LR in NSM. The evidence linking ER and PR status and NSM outcomes is currently scant, although a number of studies have examined the risk of LR in patients undergoing conventional mastectomy. One such study found that, with the addition of post-mastectomy radiation, the cumulative incidence of LR was 8.6% vs. 4.4% for ER-negative tumours and ER-positive tumours, respectively, and 8.5% vs. 3.4% for PR-negative and PR-positive tumours respectively [87]. Consequently, it can be concluded that a HER2-negative status coupled with a positive ER and PR status confers the best protection against LR and therefore would be suitable for NSM, providing the patient fits the other criteria discussed above.

Necrotic complications associated with NSM

The overall complication rate and the incidence of nipple necrosis were included as secondary outcomes of the pooled analysis. The overall complication rate was 22.3% and the nipple necrosis rate was 5.9%. Due to the extensive undermining of the NAC during NSM, it is thought that NSM may lead to an increased incidence of necrotic complications. A number of studies have reported data on nipple necrosis, with incidence rates ranging from 3.5% for total nipple necrosis to 12.1% for partial nipple necrosis [30,60,64,88]. Necrosis can occur as a quite early complication, with Radovanovic et al. [30] finding a major skin ne-

crosis rate of 3% after just 6 weeks. The concern with nipple necrosis is that it can lead to loss of the NAC at a later date [67].

Some studies have assessed whether any risk factors may be associated with an increased risk of nipple necrosis following NSM, because the identification of such risk factors could help clarify patient selection criteria. Some studies have linked a higher nipple necrosis rate with obesity [64], which may be due to the larger breast volume. Another factor that has been found to increase the risk is a positive retroareolar margin [53]; therefore, if possible, it is important to perform frozen section analysis intraoperatively in order to minimise this risk.

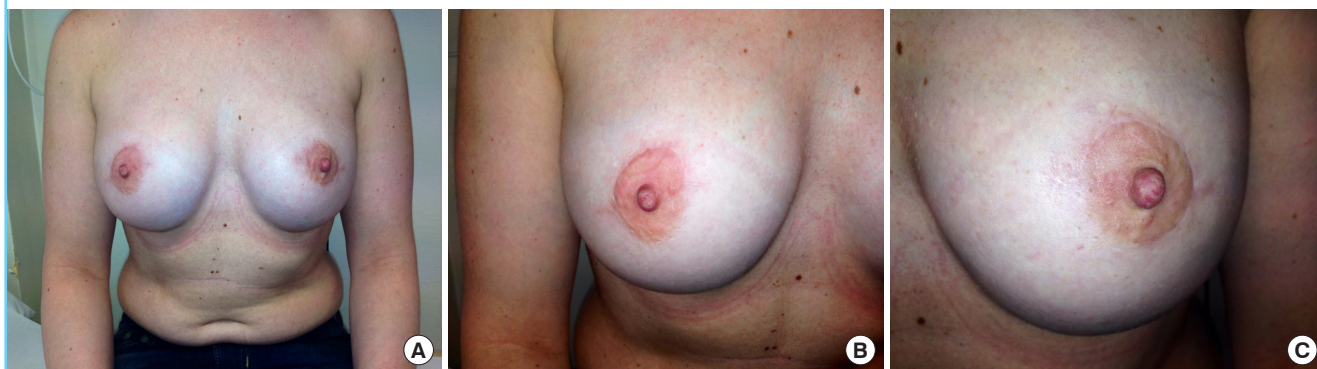Consequently, it would appear that despite the risk of necrotic complications, the actual incidence of necrosis remains low, meaning that NSM may still be a viable option. Those at a higher risk, such as those with a higher body mass index or large breast volume, should be individually assessed for suitability with the options of an autologous tissue flap or two-stage reconstruction discussed in order to minimise the possibility of revisional surgery.

Radiotherapy and NSM

Radiotherapy is an important treatment option in the management of breast cancer, as it has been found to reduce the LR rate, with one study finding that patients who underwent radiotherapy had a LR rate of 8.5% compared to 28.4% in those that did not undergo radiotherapy over a 13-year follow-up period [15]. The use of radiotherapy in NSM has been a major topic of discussion, as it has been associated with an increase in long-term complications; if radiotherapy needs to be administered after a mastectomy, the reconstructed breast can also complicate the planning and delivery of the radiotherapy [89]. Radiotherapy is also associated with complications in the reconstructed breast,

Fig. 3. Example of bilateral NSM and immediate reconstruction

A 40-year-old woman underwent bilateral NSM and immediate implant-based reconstruction with an acellular dermal matrix. On the right, mastectomy was performed for therapeutic purposes, whilst on the left it was carried out for prophylactic purposes. The aesthetic outcome was comparable for both indications. (A) Shows a bilateral view of both breast, (B) shows the right breast and nipple, and (C) shows the left breast and nipple. Due to the periareolar incision, the scarring was minimal. NSM, nipple-sparing mastectomy.



such as fat necrosis and volume loss in reconstructions using autologous tissue [90] and capsular contracture in those using implants [91]. In terms of nipple necrosis, however, it appears that including radiotherapy in the treatment of the patient does not increase the risk of NAC necrosis [92].

Preventing complications in NSM

One way in which the complication risk could be reduced is through the use of an acellular dermal matrix (ADM) in the reconstruction process. Small trials examining the use of ADMs with NSM have found that immediate breast reconstruction can be achieved with minimal complications [93]. One advantage is that use of an ADM allows the surgeon to use prepectoral placement, which has been reported to be associated with good patient satisfaction and excellent cosmetic results [94]. An example of NSM with immediate ADM-assisted implant based reconstruction can be seen in Fig. 3. No evidence is yet available on the effect of ADM use on necrotic complication rates.

The use of an ADM should therefore be considered when planning an NSM and immediate reconstruction procedure with the goal of reducing complications.

CONCLUSIONS AND RECOMMENDATIONS FOR PRACTICE

A growing body of evidence suggests that NSM is oncologically adequate for early-stage IBC and DCIS in carefully selected patients. Patients with a peripherally located tumour less than 5 cm in diameter, located more than 2 cm from the NAC, not showing HER2 overexpression, and exhibiting a positive ER and PR status may be considered for NSM with or without adjuvant radiotherapy. NSM can facilitate immediate breast reconstruction, providing an aesthetically superior treatment option for women who are not suitable for breast-conserving surgery. The optimal integration of NSM and radiotherapy has yet to be established, but radiotherapy is not associated with an increased risk of post-mastectomy nipple necrosis. Dual procedures combining NSM and immediate breast reconstruction afford many advantages, including fewer hospital admissions and a reduced need for contralateral breast adjustment in order to achieve symmetry. In order to ensure the best outcomes, it is important to highlight appropriate patient selection in order to minimise the risk of LR, as well as requiring coordination between oncological and reconstructive surgeons and an effective multidisciplinary team. In the future, a meta-analysis investigating all of the factors that affect LR recurrence after NSM should be carried out in order to facilitate optimal long-term outcomes.

REFERENCES

1. Simmons RM, Brennan M, Christos P, et al. Analysis of nipple/areolar involvement with mastectomy: can the areola be preserved? *Ann Surg Oncol* 2002;9:165-8.
2. Laronga C, Kemp B, Johnston D, et al. The incidence of occult nipple-areola complex involvement in breast cancer patients receiving a skin-sparing mastectomy. *Ann Surg Oncol* 1999;6:609-13.
3. Simmons RM, Adamovich TL. Skin-sparing mastectomy. *Surg Clin North Am* 2003;83:885-99.
4. Mallon P, Feron JG, Couturaud B, et al. The role of nipple-sparing mastectomy in breast cancer: a comprehensive review of the literature. *Plast Reconstr Surg* 2013;131:969-84.
5. Verheyden CN. Nipple-sparing total mastectomy of large breasts: the role of tissue expansion. *Plast Reconstr Surg* 1998;101:1494-500.
6. Mustonen P, Lepisto J, Papp A, et al. The surgical and oncological safety of immediate breast reconstruction. *Eur J Surg Oncol* 2004;30:817-23.
7. Dao TN, Verheyden CN. TRAM flaps: a reconstructive option after bilateral nipple-sparing total mastectomy. *Plast Reconstr Surg* 2005;116:986-92.
8. Margulies AG, Hochberg J, Kepple J, et al. Total skin-sparing mastectomy without preservation of the nipple-areola complex. *Am J Surg* 2005;190:907-12.
9. Palmieri B, Baitchev G, Grappolini S, et al. Delayed nipple-sparing modified subcutaneous mastectomy: rationale and technique. *Breast J* 2005;11:173-8.
10. Caruso F, Ferrara M, Castiglione G, et al. Nipple sparing subcutaneous mastectomy: sixty-six months follow-up. *Eur J Surg Oncol* 2006;32:937-40.
11. Komorowski AL, Zanini V, Regolo L, et al. Necrotic complications after nipple- and areola-sparing mastectomy. *World J Surg* 2006;30:1410-3.
12. Mosahebi A, Ramakrishnan V, Gittos M, et al. Aesthetic outcome of different techniques of reconstruction following nipple-areola-preserving envelope mastectomy with immediate reconstruction. *Plast Reconstr Surg* 2007;119:796-803.
13. Denewer A, Farouk O. Can nipple-sparing mastectomy and immediate breast reconstruction with modified extended latissimus dorsi muscular flap improve the cosmetic and functional outcome among patients with breast carcinoma? *World J Surg* 2007;31:1169-77.
14. Crowe JP, Patrick RJ, Yetman RJ, et al. Nipple-sparing mastectomy update: one hundred forty-nine procedures and clinical outcomes. *Arch Surg* 2008;143:1106-10.
15. Benediktsson KP, Perbeck L. Survival in breast cancer after

- nipple-sparing subcutaneous mastectomy and immediate reconstruction with implants: a prospective trial with 13 years median follow-up in 216 patients. *Eur J Surg Oncol* 2008;34:143-8.
16. Sookhan N, Boughey JC, Walsh MF, et al. Nipple-sparing mastectomy: initial experience at a tertiary center. *Am J Surg* 2008;196:575-7.
 17. Regolo L, Ballardini B, Gallarotti E, et al. Nipple sparing mastectomy: an innovative skin incision for an alternative approach. *Breast* 2008;17:8-11.
 18. Voltura AM, Tsangaris TN, Rosson GD, et al. Nipple-sparing mastectomy: critical assessment of 51 procedures and implications for selection criteria. *Ann Surg Oncol* 2008;15:3396-401.
 19. Wijayanayagam A, Kumar AS, Foster RD, et al. Optimizing the total skin-sparing mastectomy. *Arch Surg* 2008;143:38-45.
 20. Stolier A, Stone JC, Moroz K, et al. A comparison of clinical and pathologic assessments for the prediction of occult nipple involvement in nipple-sparing mastectomies. *Ann Surg Oncol* 2013;20:128-32.
 21. Paepke S, Schmid R, Fleckner S, et al. Subcutaneous mastectomy with conservation of the nipple-areola skin: broadening the indications. *Ann Surg* 2009;250:288-92.
 22. Garcia-Etienne CA, Cody III HS 3rd, Disa JJ, et al. Nipple-sparing mastectomy: initial experience at the Memorial Sloan-Kettering Cancer Center and a comprehensive review of literature. *Breast J* 2009;15:440-9.
 23. Gerber B, Krause A, Dieterich M, et al. The oncological safety of skin sparing mastectomy with conservation of the nipple-areola complex and autologous reconstruction: an extended follow-up study. *Ann Surg* 2009;249:461-8.
 24. Petit JY, Veronesi U, Orecchia R, et al. Nipple sparing mastectomy with nipple areola intraoperative radiotherapy: one thousand and one cases of a five years experience at the European institute of oncology of Milan (EIO). *Breast Cancer Res Treat* 2009;117:333-8.
 25. Chen CM, Disa JJ, Sacchini V, et al. Nipple-sparing mastectomy and immediate tissue expander/implant breast reconstruction. *Plast Reconstr Surg* 2009;124:1772-80.
 26. Yueh JH, Houlihan MJ, Slavin SA, et al. Nipple-sparing mastectomy: evaluation of patient satisfaction, aesthetic results, and sensation. *Ann Plast Surg* 2009;62:586-90.
 27. Garwood ER, Moore D, Ewing C, et al. Total skin-sparing mastectomy: complications and local recurrence rates in 2 cohorts of patients. *Ann Surg* 2009;249:26-32.
 28. Sakamoto N, Fukuma E, Higa K, et al. Early results of an endoscopic nipple-sparing mastectomy for breast cancer. *Ann Surg Oncol* 2009;16:3406-13.
 29. Colwell AS, Gadd M, Smith BL, et al. An inferolateral approach to nipple-sparing mastectomy: optimizing mastectomy and reconstruction. *Ann Plast Surg* 2010;65:140-3.
 30. Radovanovic Z, Radovanovic D, Golubovic A, et al. Early complications after nipple-sparing mastectomy and immediate breast reconstruction with silicone prosthesis: results of 214 procedures. *Scand J Surg* 2010;99:115-8.
 31. Kim HJ, Park EH, Lim WS, et al. Nipple areola skin-sparing mastectomy with immediate transverse rectus abdominis musculocutaneous flap reconstruction is an oncologically safe procedure: a single center study. *Ann Surg* 2010;251:493-8.
 32. Luo D, Ha J, Latham B, et al. The accuracy of intraoperative subareolar frozen section in nipple-sparing mastectomies. *Ochsner J* 2010;10:188-92.
 33. Salgarello M, Visconti G, Farallo E. Autologous fat graft in irradiated tissue prior to alloplastic reconstruction of the breast: report of two cases. *Aesthetic Plast Surg* 2010;34:5-10.
 34. Mladenov M, Cherveniyakov P, Daskalova I. Nipple-sparing mastectomy (subcutaneous mastectomy with preserving of the areolomammilar complex) like alternative of the modify radical mastectomy in selected cases. *Khirurgiia (Sofia)* 2010;(6):23-7.
 35. Rawlani V, Fiuk J, Johnson SA, et al. The effect of incision choice on outcomes of nipple-sparing mastectomy reconstruction. *Can J Plast Surg* 2011;19:129-33.
 36. Spear SL, Willey SC, Feldman ED, et al. Nipple-sparing mastectomy for prophylactic and therapeutic indications. *Plast Reconstr Surg* 2011;128:1005-14.
 37. Harness JK, Vetter TS, Salibian AH. Areola and nipple-areola-sparing mastectomy for breast cancer treatment and risk reduction: report of an initial experience in a community hospital setting. *Ann Surg Oncol* 2011;18:917-22.
 38. de Alcantara Filho P, Capko D, Barry JM, et al. Nipple-sparing mastectomy for breast cancer and risk-reducing surgery: the Memorial Sloan-Kettering Cancer Center experience. *Ann Surg Oncol* 2011;18:3117-22.
 39. Jensen JA, Orringer JS, Giuliano AE. Nipple-sparing mastectomy in 99 patients with a mean follow-up of 5 years. *Ann Surg Oncol* 2011;18:1665-70.
 40. Boneti C, Yuen J, Santiago C, et al. Oncologic safety of nipple skin-sparing or total skin-sparing mastectomies with immediate reconstruction. *J Am Coll Surg* 2011;212:686-93.
 41. Yang SJ, Eom JS, Lee TJ, et al. Recipient vessel selection in immediate breast reconstruction with free abdominal tissue transfer after nipple-sparing mastectomy. *Arch Plast Surg* 2012;39:216-21.

42. Schneider LF, Chen CM, Stolier AJ, et al. Nipple-sparing mastectomy and immediate free-flap reconstruction in the large ptotic breast. *Ann Plast Surg* 2012;69:425-8.
43. Spear SL, Rottman SJ, Seiboth LA, et al. Breast reconstruction using a staged nipple-sparing mastectomy following mastopexy or reduction. *Plast Reconstr Surg* 2012;129:572-81.
44. Jensen JA, Lin JH, Kapoor N, et al. Surgical delay of the nipple-areolar complex: a powerful technique to maximize nipple viability following nipple-sparing mastectomy. *Ann Surg Oncol* 2012;19:3171-6.
45. Kneubil MC, Lohsiriwat V, Curigliano G, et al. Risk of locoregional recurrence in patients with false-negative frozen section or close margins of retroareolar specimen in nipple-sparing mastectomy. *Ann Surg Oncol* 2012;19:4117-23.
46. Peled AW, Foster RD, Garwood ER, et al. The effects of acellular dermal matrix in expander-implant breast reconstruction after total skin-sparing mastectomy: results of a prospective practice improvement study. *Plast Reconstr Surg* 2012;129:901e-908e.
47. Moyer HR, Ghazi B, Daniel JR, et al. Nipple-sparing mastectomy: technical aspects and aesthetic outcomes. *Ann Plast Surg* 2012;68:446-50.
48. Warren Peled A, Foster RD, Stover AC, et al. Outcomes after total skin-sparing mastectomy and immediate reconstruction in 657 breasts. *Ann Surg Oncol* 2012;19:3402-9.
49. Algaithy ZK, Petit JY, Lohsiriwat V, et al. Nipple sparing mastectomy: can we predict the factors predisposing to necrosis? *Eur J Surg Oncol* 2012;38:125-9.
50. Wagner JL, Fearmonti R, Hunt KK, et al. Prospective evaluation of the nipple-areola complex sparing mastectomy for risk reduction and for early-stage breast cancer. *Ann Surg Oncol* 2012;19:1137-44.
51. Blechman KM, Karp NS, Levovitz C, et al. The lateral inframammary fold incision for nipple-sparing mastectomy: outcomes from over 50 immediate implant-based breast reconstructions. *Breast J* 2013;19:31-40.
52. Tanna N, Broer PN, Weichman KE, et al. Microsurgical breast reconstruction for nipple-sparing mastectomy. *Plast Reconstr Surg* 2013;131:139e-147e.
53. Lohsiriwat V, Rotmensz N, Botteri E, et al. Do clinicopathological features of the cancer patient relate with nipple areolar complex necrosis in nipple-sparing mastectomy? *Ann Surg Oncol* 2013;20:990-6.
54. Sahin I, Isik S, Alhan D, et al. One-staged silicone implant breast reconstruction following bilateral nipple-sparing prophylactic mastectomy in patients at high-risk for breast cancer. *Aesthetic Plast Surg* 2013;37:303-11.
55. Sakurai T, Zhang N, Suzuma T, et al. Long-term follow-up of nipple-sparing mastectomy without radiotherapy: a single center study at a Japanese institution. *Med Oncol* 2013;30:481.
56. Fortunato L, Loreti A, Andrich R, et al. When mastectomy is needed: is the nipple-sparing procedure a new standard with very few contraindications? *J Surg Oncol* 2013;108:207-12.
57. Burdge EC, Yuen J, Hardee M, et al. Nipple skin-sparing mastectomy is feasible for advanced disease. *Ann Surg Oncol* 2013;20:3294-302.
58. Rulli A, Caracappa D, Barberini F, et al. Oncologic reliability of nipple-sparing mastectomy for selected patients with breast cancer. *In Vivo* 2013;27:387-94.
59. Romics L Jr, Stallard S, Weiler-Mithoff E. Oncologic safety of skin-sparing mastectomy followed by immediate breast reconstruction: rate and localization of recurrences, and impact of reconstruction techniques. *Orv Hetil* 2013;154:163-71.
60. Munhoz AM, Aldrighi CM, Montag E, et al. Clinical outcomes following nipple-areola-sparing mastectomy with immediate implant-based breast reconstruction: a 12-year experience with an analysis of patient and breast-related factors for complications. *Breast Cancer Res Treat* 2013;140:545-55.
61. Coopey SB, Tang R, Lei L, et al. Increasing eligibility for nipple-sparing mastectomy. *Ann Surg Oncol* 2013;20:3218-22.
62. Tancredi A, Ciuffreda L, Petito L, et al. Nipple-areola-complex sparing mastectomy: five years of experience in a single centre. *Updates Surg* 2013;65:289-94.
63. Chen J, Lu Q, Wang X, et al. Breast reconstruction after skin-sparing mastectomy or nipple-sparing mastectomy for breast cancer. *Zhongguo Xiu Fu Chong Jian Wai Ke Za Zhi* 2013;27:872-5.
64. Colwell AS, Tessler O, Lin AM, et al. Breast reconstruction following nipple-sparing mastectomy: predictors of complications, reconstruction outcomes, and 5-year trends. *Plast Reconstr Surg* 2014;133:496-506.
65. Stanec Z, Zic R, Budi S, et al. Skin and nipple-areola complex sparing mastectomy in breast cancer patients: 15-year experience. *Ann Plast Surg* 2014;73:485-91.
66. Chattopadhyay D, Gupta S, Jash PK, et al. Skin sparing mastectomy with preservation of nipple areola complex and immediate breast reconstruction in patients with breast cancer: a single centre prospective study. *Plast Surg Int* 2014;2014:589068.
67. Leclere FM, Panet-Spallina J, Kolb F, et al. Nipple-sparing mastectomy and immediate reconstruction in ductal carcinoma

- noma in situ: a critical assessment with 41 patients. *Aesthetic Plast Surg* 2014;38:338-43.
68. Eisenberg RE, Chan JS, Swistel AJ, et al. Pathological evaluation of nipple-sparing mastectomies with emphasis on occult nipple involvement: the Weill-Cornell experience with 325 cases. *Breast J* 2014;20:15-21.
 69. Wang F, Peled AW, Garwood E, et al. Total skin-sparing mastectomy and immediate breast reconstruction: an evolution of technique and assessment of outcomes. *Ann Surg Oncol* 2014;21:3223-30.
 70. Kim SW, Lee HK, Kang SM, et al. Short-term outcomes of immediate breast reconstruction using an implant or tissue expander after mastectomy in breast cancer patients. *Breast Cancer* 2016;23:279-85.
 71. Adam H, Bygdson M, de Boniface J. The oncological safety of nipple-sparing mastectomy - a Swedish matched cohort study. *Eur J Surg Oncol* 2014;40:1209-15.
 72. Huston TL, Small K, Swistel AJ, et al. Nipple-sparing mastectomy via an inframammary fold incision for patients with scarring from prior lumpectomy. *Ann Plast Surg* 2015;74:652-7.
 73. Sood S, Elder E, French J. Nipple-sparing mastectomy with implant reconstruction: the Westmead experience. *ANZ J Surg* 2015;85:363-7.
 74. Peled AW, Irwin CS, Hwang ES, et al. Total skin-sparing mastectomy in BRCA mutation carriers. *Ann Surg Oncol* 2014;21:37-41.
 75. Poruk KE, Ying J, Chidester JR, et al. Breast cancer recurrence after nipple-sparing mastectomy: one institution's experience. *Am J Surg* 2015;209:212-7.
 76. Yao K, Liederbach E, Tang R, et al. Nipple-sparing mastectomy in BRCA1/2 mutation carriers: an interim analysis and review of the literature. *Ann Surg Oncol* 2015;22:370-6.
 77. Endara M, Chen D, Verma K, et al. Breast reconstruction following nipple-sparing mastectomy: a systematic review of the literature with pooled analysis. *Plast Reconstr Surg* 2013;132:1043-54.
 78. Barton FE Jr, English JM, Kingsley WB, et al. Glandular excision in total glandular mastectomy and modified radical mastectomy: a comparison. *Plast Reconstr Surg* 1991;88:389-92.
 79. Torresan RZ, dos Santos CC, Okamura H, et al. Evaluation of residual glandular tissue after skin-sparing mastectomies. *Ann Surg Oncol* 2005;12:1037-44.
 80. Ho CM, Mak CK, Lau Y, et al. Skin involvement in invasive breast carcinoma: safety of skin-sparing mastectomy. *Ann Surg Oncol* 2003;10:102-7.
 81. Agarwal S, Agarwal S, Neumayer L, et al. Therapeutic nipple-sparing mastectomy: trends based on a national cancer database. *Am J Surg* 2014;208:93-8.
 82. Moon JY, Chang YW, Lee EH, et al. Malignant invasion of the nipple-areolar complex of the breast: usefulness of breast MRI. *AJR Am J Roentgenol* 2013;201:448-55.
 83. Byon W, Kim E, Kwon J, et al. Magnetic resonance imaging and clinicopathological factors for the detection of occult nipple involvement in breast cancer patients. *J Breast Cancer* 2014;17:386-92.
 84. Banerjee A, Gupta S, Bhattacharya N. Preservation of nipple-areola complex in breast cancer: a clinicopathological assessment. *J Plast Reconstr Aesthet Surg* 2008;61:1195-8.
 85. Atiyeh B, Dibo S, Zgheib E, et al. Skin sparing/skin reducing mastectomy (SSM/SRM) and the concept of oncoplastic breast surgery. *Int J Surg* 2014;12:1115-22.
 86. Petit JY, Veronesi U, Orecchia R, et al. Risk factors associated with recurrence after nipple-sparing mastectomy for invasive and intraepithelial neoplasia. *Ann Oncol* 2012;23:2053-8.
 87. Panoff JE, Hurley J, Takita C, et al. Risk of locoregional recurrence by receptor status in breast cancer patients receiving modern systemic therapy and post-mastectomy radiation. *Breast Cancer Res Treat* 2011;128:899-906.
 88. Chirappapha P, Petit JY, Rietjens M, et al. Nipple sparing mastectomy: does breast morphological factor related to necrotic complications? *Plast Reconstr Surg Glob Open* 2014;2:e99.
 89. Buchholz TA, Kronowitz SJ, Kuerer HM. Immediate breast reconstruction after skin-sparing mastectomy for the treatment of advanced breast cancer: radiation oncology considerations. *Ann Surg Oncol* 2002;9:820-1.
 90. Singletary SE, Robb GL. Oncologic safety of skin-sparing mastectomy. *Ann Surg Oncol* 2003;10:95-7.
 91. Evans GR, Schusterman MA, Kroll SS, et al. Reconstruction and the radiated breast: is there a role for implants? *Plast Reconstr Surg* 1995;96:1111-5.
 92. Alperovich M, Choi M, Frey JD, et al. Nipple-sparing mastectomy in patients with prior breast irradiation: are patients at higher risk for reconstructive complications? *Plast Reconstr Surg* 2014;134:202e-206e.
 93. Gunnarsson GL, Borsen-Koch M, Wamberg P, et al. How to perform a NAC sparing mastectomy using an ADM and an implant. *Gland Surg* 2014;3:252-7.
 94. Reitsamer R, Peintinger F. Prepectoral implant placement and complete coverage with porcine acellular dermal matrix: a new technique for direct-to-implant breast reconstruction after nipple-sparing mastectomy. *J Plast Reconstr Aesthet Surg* 2015;68:162-7.