

the recipient area. The main advantage of this procedure was minimizing the operation time under general anesthesia in a patient with a poor cardiac condition. Using two free flaps simultaneously would have required two donor sites and a longer period of general anesthesia, while using two free flaps sequentially would have required general anesthesia to be performed twice. Although these decisions must always depend on the individual case, prolonged surgery and multiple operations under general anesthesia should generally be avoided in patients with severe atherosclerosis due to associations with higher morbidity and mortality [5].

## References

1. Chen H, El-Gammal TA, Wei F, et al. Cross-leg free flaps for difficult cases of leg defects: indications, pitfalls, and long-term results. *J Trauma* 1997;43:486-91.
2. Yu L, Tan J, Cai L, et al. Repair of severe composite tissue defects in the lower leg using two different cross-leg free composite tissue flaps. *Ann Plast Surg* 2012;68:83-7.
3. Serel S, Kaya B, Demiralp O, et al. Cross-leg free anterolateral thigh perforator flap: a case report. *Microsurgery* 2006;26:190-2.
4. Huang CC, Chang CH, Hsu H, et al. Endovascular revascularization and free tissue transfer for lower limb salvage. *J Plast Reconstr Aesthet Surg* 2014;67:1407-14.
5. Hong JP. Reconstruction of the diabetic foot using the anterolateral thigh perforator flap. *Plast Reconstr Surg* 2006;117:1599-608.

## A Rare Case of Bilateral Upper Extremity Hypercalcinosis in Systemic Sclerosis Requiring Multiple Radical Debridements

Jordan D. Frey<sup>1</sup>, Benjamin Wadowski<sup>2</sup>, Sheel Sharma<sup>1</sup>

<sup>1</sup>Department of Plastic Surgery, NYU Langone Medical Center, New York, NY; <sup>2</sup>NYU Langone Medical Center, NYU School of Medicine, New York, NY, USA

**Correspondence:** Jordan D. Frey  
Department of Plastic Surgery, NYU Langone Medical Center, 550 1st Avenue  
New York, NY 10016, USA  
Tel: +1-212-263-5834, Fax: +1-212-263-5400  
E-mail: Jordan.Frey@nyumc.org

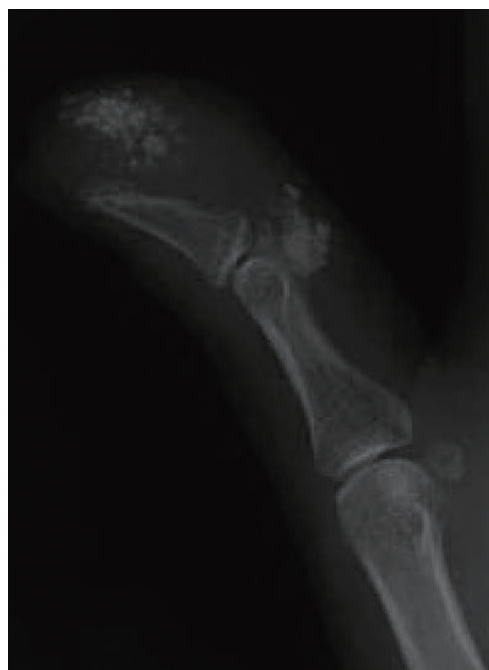No potential conflict of interest relevant to this article was reported.

Received: 23 Sep 2015 • Revised: 21 Dec 2015 • Accepted: 21 Dec 2015

pISSN: 2234-6163 • eISSN: 2234-6171  
<http://dx.doi.org/10.5999/aps.2016.43.4.387>  
*Arch Plast Surg* 2016;43:387-389

Copyright © 2016 The Korean Society of Plastic and Reconstructive Surgeons  
This is an Open Access article distributed under the terms of the Creative Commons Attribution Non-Commercial License (<http://creativecommons.org/licenses/by-nc/4.0/>) which permits unrestricted non-commercial use, distribution, and reproduction in any medium, provided the original work is properly cited.

Systemic sclerosis is an autoimmune connective tissue disease that may affect the hands [1]. Hypercalcinosis in systemic sclerosis is a rare and poorly defined entity characterized by widely metastatic benign calcific deposits [2]. We describe a case of bilateral upper extremity hypercalcinosis requiring multiple radical debridements, in which



**Fig. 1.** Plain radiograph demonstrating soft tissue calcification in the volar aspect of the distal thumb at the level of the distal phalanx and at the head of the proximal phalanx with acro-osteolysis of the distal phalanx.

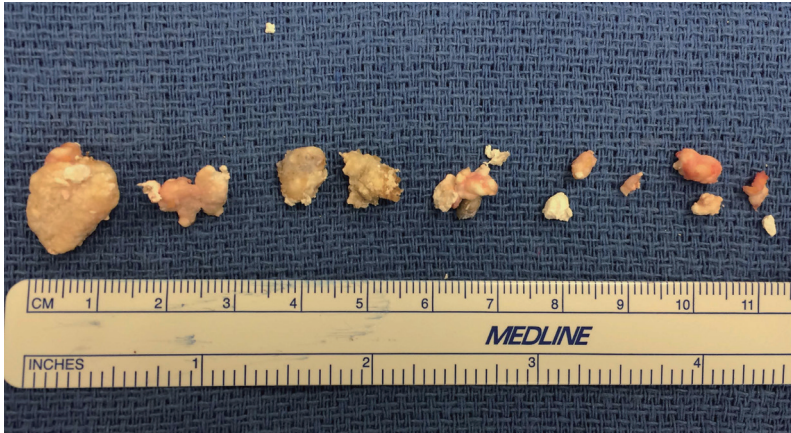


Fig. 2.

Calcific deposits after radical debridement of the left thumb and right index and ring fingers; the patient's fourth such radical debridement.

local tissue rearrangement was used for sequential successful reconstructions.

The patient was a 56-year-old woman with a history of systemic sclerosis. She presented to a hand surgeon with two severely painful calcific lesions of her left thumb pulp and a large area of calcinosis on the extensor surface of the right elbow after failed medical treatment. She subsequently underwent excision and curettage of the left thumb and right elbow lesions with local tissue rearrangement of all defects.

The patient remained pain-free for 26 months and then presented with painful calcific lesions of the right posterior forearm and right index finger. She underwent radical excision of a 3 cm × 15 cm lesion of the forearm with local tissue rearrangement and excision of a 1-cm right index finger lesion.

Three months after the second operation, the patient experienced recurrent painful calcinosis of the right index finger and left thumb along with new calcinosis of the right thumb (Fig. 1). These lesions were excised and, 20 months later, she returned with recurrent painful lesions of the left thumb and right index finger and new lesions of the right ring finger. She underwent radical debridement of all lesions (Fig. 2). Overall, her postoperative courses were uncomplicated, requiring only local wound care for poor wound healing. At 8.5 months of follow-up, she again developed recurrence of painful calcific deposits (Fig. 3).

Hypercalcinosis is a severe and proliferative form of calcinosis seen in systemic sclerosis and calcinosis, Raynaud phenomenon, esophageal dysmobility, sclerodactyly, and telangiectasia syndrome, resulting

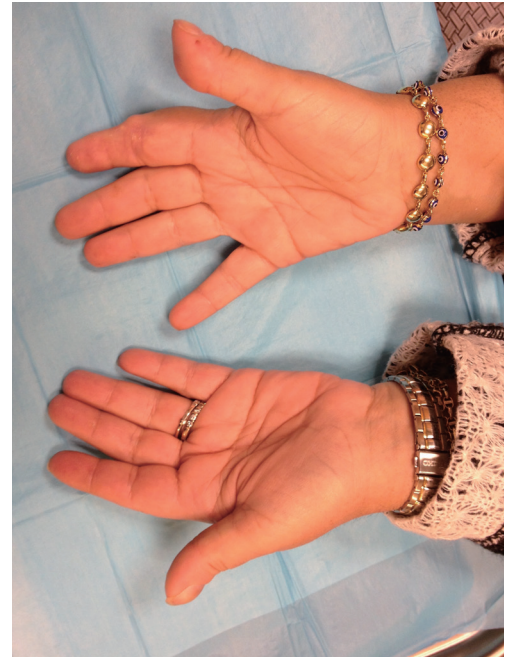


Fig. 3.

Postoperative photographs of the right and left hands 8.5 months after the radical debridement of calcific deposits in the left thumb and right index and ring finger, with evidence of recurrence.

in widely metastatic deposits that may become painful, ulcerated, or infected [2]. Hand involvement in this disease process is common and is frequently the first manifestation of disease [1]. We present a patient with bilateral upper extremity hypercalcinosis diagnosed both clinically and radiographically. The major indication for surgery in this case was severe pain, which we hypothesize was due to a compartment syndrome-like effect of the calcium within the small areas of the digit.

Various options have been described for the treatment of hand lesions, but radical debridement was performed in each operation in this patient [3,4]. The time to recurrence ranged from three to 26 months in this case, highlighting the aggressive nature of this case of hypercalcinosis. While the full armamentarium of local and distant hand flaps is available for reconstruction, we recommend local tissue rearrangement allowing for the possibility of re-advancement, similar to the principle of pressure sore reconstruction, due to the high likelihood of lesion recurrence.

## References

1. Arslan Tas D, Erken E, Sakalli H, et al. Evaluating hand

- in systemic sclerosis. *Rheumatol Int* 2012;32:3581-6.
- Eckardt J, Towfigh H. Hypercalcinosis of the hands in scleroderma: 2 case reports. *Handchir Mikrochir Plast Chir* 1994;26:330-4.
  - Merlino G, Germano S, Carlucci S. Surgical management of digital calcinosis in CREST syndrome. *Aesthetic Plast Surg* 2013;37:1214-9.
  - Lapner MA, Goetz TJ. High-speed burr debulking of digital calcinosis cutis in scleroderma patients. *J Hand Surg Am* 2014;39:503-10.

## Wrist Pain due to Abnormal Extensor Carpi Ulnaris Tendon

SuRak Eo<sup>1</sup>, Sujin Bahk<sup>1</sup>, Neil F. Jones<sup>2</sup>

<sup>1</sup>Department of Plastic and Reconstructive Surgery, Dongguk University Graduate School of Medicine, Seoul, Korea; <sup>2</sup>Center for Hand and Upper Extremity Surgery, University of California Irvine, Irvine, CA, USA

**Correspondence:** Neil F. Jones

Center for Hand and Upper Extremity Surgery, University of California Irvine, 101 The City Drive South, Pavilion III, Building 29A, Orange, California 92868, USA  
Tel: +1-714-456-5759, Fax: +1-714-456-7547, E-mail: nfonjes@uci.edu

No potential conflict of interest relevant to this article was reported.

Received: 27 Jul 2015 • Revised: 11 Nov 2015 • Accepted: 28 Dec 2015  
pISSN: 2234-6163 • eISSN: 2234-6171  
<http://dx.doi.org/10.5999/aps.2016.43.4.389>  
Arch Plast Surg 2016;43:389-390



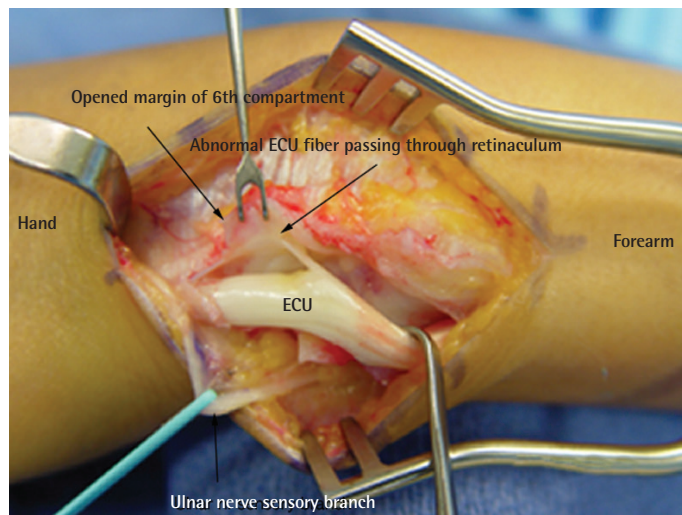
Copyright © 2016 The Korean Society of Plastic and Reconstructive Surgeons  
This is an Open Access article distributed under the terms of the Creative Commons Attribution Non-Commercial License (<http://creativecommons.org/licenses/by-nc/4.0/>) which permits unrestricted non-commercial use, distribution, and reproduction in any medium, provided the original work is properly cited.

Pain arising from lesions in the extensor carpi ulnaris (ECU) is known to occur mainly due to tenosynovitis, tendon rupture, and subluxation or dislocation of the ECU tendon [1,2]. However, anomalies of the ECU tendon itself and the surrounding extensor retinaculum are also possible factors contributing to the impairment of function at the dorso-ulnar aspect of the wrist and little finger [2,3]. We report a case in which an abnormal ECU tendon slip was revealed during exploration of the wrist.

A 28-year-old right-handed female neurosurgeon visited our clinic due to dorso-ulnar wrist pain in her dominant hand for six months. The pain was exacerbated during wrist motion, especially during forearm supination for handling the needle holders in

the operating field. A physical examination revealed no sensory changes and no specific signs, including the Phalen and Finkelstein tests. Radiographic studies also showed no problems such as joint subluxation. The hand showed a slight tender swelling of the ECU tendon around the wrist. With the suspicion of tenosynovitis, steroid injection into the sixth compartment was performed. However, the pain did not respond to medical treatment. Electrodiagnostic studies revealed no abnormalities. On exploration, we found the abnormal insertion of an additional ECU tendon slip into the radial inner side of the sixth compartment (Fig. 1). After simple excision of the entire abnormal ECU tendon slip, her symptoms improved.

The ECU tendon is enclosed in the sixth compartment of the extensor retinaculum and various anomalies of the ECU tendon have been reported [2,3]. The prevalence of an accessory tendinous slip arising from the ECU tendon has been reported to be 10% to 34% [2,4], and Barfred and Adamsen [3] noted that the accessory tendinous slip of the ECU was sometimes connected with the extensor digiti minimi. Nakashima classified accessory slips into three types according to the insertion point of the main tendon to the fifth metacarpal bone: type A, on the base along with the main tendon; type B, on the midsection; and type C, on the head [2]. The case presented here belonged to type A. The average width of the slips has been reported to range from 1–1.53 mm [2,3], while the



**Fig. 1.**

The abnormal insertion of an additional extensor carpi ulnaris (ECU) tendon slip into the radial inner side of the sixth compartment.