

skin lesions did not have the classic findings of edema, warmth, pain, purulent drainage, or response to antibiotic therapy. The abdominal donor site was closed without tension or ischemic signs like the mastectomy flaps; therefore, the development of identical lesions on the breast caused suspicion of a non-infectious etiology.

A high index of suspicion for skin pathergies (pyoderma gangrenosum, AFND, etc.) is necessary for prompt diagnosis. Early diagnosis can lead to faster treatment and help avoid potential morbidities of surgical debridement and skin trauma. However, it is critical to avoid immunosuppressive therapy before infection is ruled out because the early phases of AFND are similar in presentation to cellulitis and necrotizing fasciitis. We recommend prompt skin biopsy for tissue diagnosis, and we recommend non-adherent dressings and infrequent changes to minimize skin trauma. A multidisciplinary team approach including dermatology, hematology, and internal medicine is recommended to expedite diagnosis and treatment of the underlying disease.

We report the first case of AFND in a DIEP free flap for breast reconstruction that was successfully treated with corticosteroids and non-surgical management. Further research and long-term follow-up is warranted to develop consensus recommendations and treatment protocols for skin pathology and wound breakdown in breast reconstruction.

## ORCID

Julia A. Cook <http://orcid.org/0000-0003-0212-937X>

## References

1. Cohen PR, Kurzrock R. Sweet's syndrome revisited: a review of disease concepts. *Int J Dermatol* 2003;42:761-78.
2. Cohen PR. Pregnancy-associated Sweet's syndrome: world literature review. *Obstet Gynecol Surv* 1993;48:584-7.
3. Cook E, Epstein R, Miller R. A rare case of idiopathic neutrophilic dermatosis of the hands. *Dermatol Online J* 2011;17:11.
4. Sweet RD. An acute febrile neutrophilic dermatosis. *Br J Dermatol* 1964;76:349-56.
5. Bourke JF, Keohane S, Long CC, et al. Sweet's syndrome and malignancy in the U.K. *Br J Dermatol* 1997;137:609-13.

## Calcifications on the Entire Legs of a Systemic Lupus Erythematosus Patient

Seungki Youn, Ki Ho Kim, Soo Yeon Lim, Jeong Tae Kim, Youn Hwan Kim

*Department of Plastic and Reconstructive Surgery, Hanyang University College of Medicine, Seoul, Korea*

**Correspondence:** Youn Hwan Kim  
Department of Plastic and Reconstructive Surgery, Hanyang University School of Medicine, 222-1 Wangsimni-ro, Seongdong-gu, Seoul 04763, Korea  
Tel: +82-2-2290-8560, Fax: +82-2-2295-7671  
E-mail: younhwan@daum.net

No potential conflict of interest relevant to this article was reported.

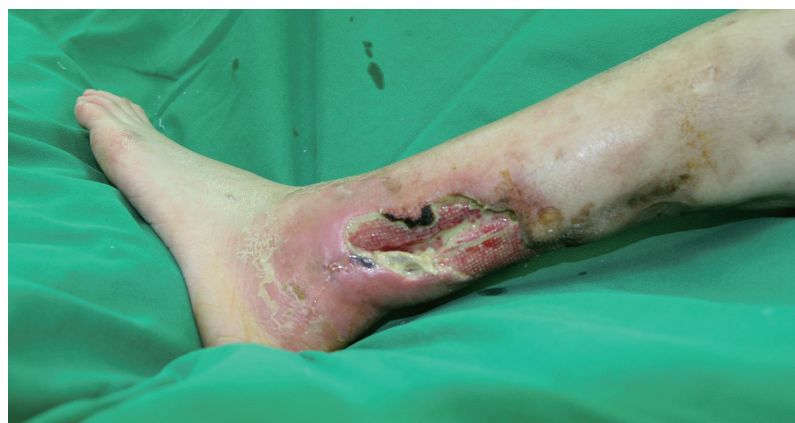Received: 10 May 2016 • Revised: 18 Aug 2016 • Accepted: 23 Aug 2016  
pISSN: 2234-6163 • eISSN: 2234-6171  
<http://dx.doi.org/10.5999/aps.2016.43.5.481>  
*Arch Plast Surg* 2016;43:481-482



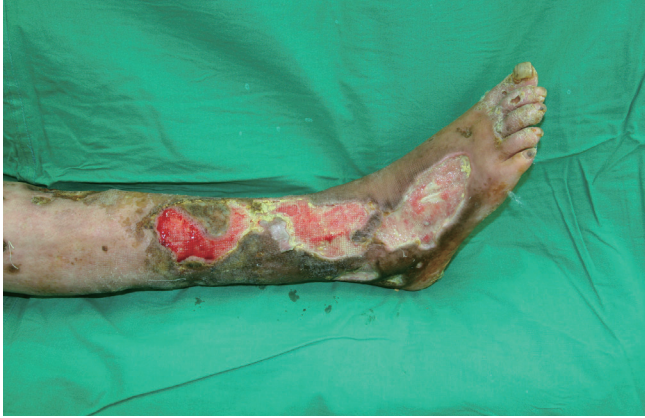Copyright © 2016 The Korean Society of Plastic and Reconstructive Surgeons  
This is an Open Access article distributed under the terms of the Creative Commons Attribution Non-Commercial License (<http://creativecommons.org/licenses/by-nc/4.0/>) which permits unrestricted non-commercial use, distribution, and reproduction in any medium, provided the original work is properly cited.

Systemic lupus erythematosus (SLE) is a relatively common entity in rheumatology. Skin involvements such as nodules, vasculitis, and calcifications are commonly reported in patients with SLE [1,2]. In our center, we encounter many rheumatoid patients referred from our rheumatology clinic. However, the case shown here was very unusual even to our experienced eyes.

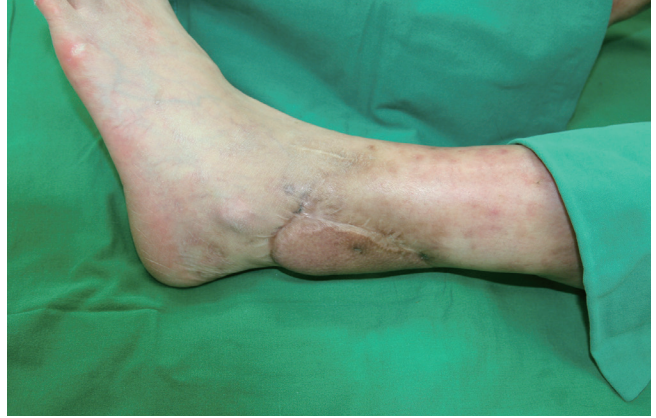A 37-year-old female patient, who had suffered from SLE for 16 years, had acquired progressive calcifications on the entirety of both of her legs. The calcification lesions were initially not severe and were



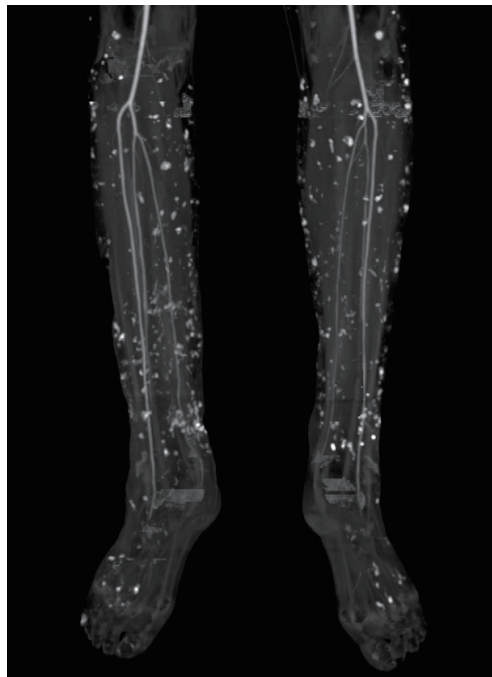
**Fig. 1.** Multiple left leg defects. The left leg defects shown here are arose from calcinosis, which occurred in both legs.



**Fig. 2.** Multiple right leg defects. The right leg defects shown here are arose from calcinosis, which occurred in both legs.



**Fig. 4.** Postoperative view of the left leg. The left leg is shown after coverage of the defect with a thoracodorsal perforator free flap.



**Fig. 3.** Computed tomography (CT) angiography of the legs. CT angiography clearly demonstrated the extent of the calcifications.

limited to the lower leg area. However, the progression accelerated into groups of calcifications on both legs, which resulted in multiple leg defects (Figs. 1, 2). Her computed tomography (CT) angiography clearly showed the extent of the disease (Fig. 3). To help heal the wounds, immune suppressive drugs were administered, but the patient's condition was serious. Though administration of intravenous immunoglobulin was temporary effective to control the SLE, the wounds worsened, which led to sepsis. The wounds progressed despite our efforts. We serially debrided the infected defects and covered the defects with free flaps and 0.010-inch split-

thickness skin grafts from the thighs (Fig. 4). Up to the present, a total of 18 surgical procedures have been performed. The wounds are now stable with conservative treatment.

Calcifications with this extent of progression in a SLE patient are extremely rare [3]. Nevertheless, this case reminds us that we should not overlook skin involvements associated with SLE, especially progressive calcifications, which can lead to serious morbidities.

## References

1. Rothfield N, Sontheimer RD, Bernstein M. Lupus erythematosus: systemic and cutaneous manifestations. *Clin Dermatol* 2006;24:348-62.
2. Gutierrez A Jr, Wetter DA. Calcinosis cutis in autoimmune connective tissue diseases. *Dermatol Ther* 2012;25:195-206.
3. Tristano AG, Villarroel JL, Rodriguez MA, et al. Calcinosis cutis universalis in a patient with systemic lupus erythematosus. *Clin Rheumatol* 2006;25:70-4.