

Microsurgical Training using Reusable Human Vessels from Discarded Tissues in Lymph Node Dissection

Naohiro Ishii¹, Tomoki Kiuchi², Tomito Oji², Kazuo Kishi²

¹Department of Plastic and Reconstructive Surgery, Tochigi Cancer Center, Tochigi; ²Department of Plastic and Reconstructive Surgery, Keio University, Tokyo, Japan

The use of human vessels at the beginning of microsurgery training is highly recommended. But vessels with the appropriate length for training are not often obtained. Whether these vessels may be reused for training has not been reported. Accordingly, we harvested vessels from discarded tissues in lymph node dissection and demonstrated that vascular anastomosis training using the same human vessels several times is possible by placing the vessels in a freezer and defrosting them with hot water. Vascular walls can be stored for microsurgical training until about 4 years after harvest, as shown in the gross appearance and histologic findings of our preserved vessels. We recommend the technique presented here for the long-term reuse of human vessels for microsurgery training that closely resembles real procedures.

Keywords Microsurgery / Training / Human vessels / Reusable / Lymph node dissection

Correspondence: Naohiro Ishii
Department of Plastic and Reconstructive Surgery, Tochigi Cancer Center, 4-9-13, Yohnan, Utsunomiya City, Tochigi 320-0834, Japan
Tel: +81-28-658-5151
Fax: +81-28-658-5669
E-mail: ishinao0916@gmail.com

The authors would like to acknowledge Nobuo Hoshi, M.D., of the Department of Pathology, Tochigi Cancer Center for his pathological contribution to our study.

No potential conflict of interest relevant to this article was reported.

Received: 7 Jul 2016 • Revised: 9 Sep 2016 • Accepted: 20 Sep 2016

pISSN: 2234-6163 • eISSN: 2234-6171 • <https://doi.org/10.5999/aps.2016.43.6.595> • Arch Plast Surg 2016;43:595-598

INTRODUCTION

Vascular anastomosis is an important technique in microsurgery, and it requires the acquisition of specific skills through fundamental training. Numerous models for microsurgical training in vascular anastomosis [1-5], including biological and nonbiological models with viable and nonviable tissues, have been reported. An ideal model for trainee microsurgeons who do not have easy access to animal experimentation facilities needs to take into account the following criteria: availability and cost-effectiveness, and similarity of training materials to human vessels. Training with human vessels if viable tissue models are not available is ideal. However, whether human vessels may be

reused in training has not been reported. Accordingly, we have demonstrated that training vascular anastomosis using the same human vessels several times is possible by placing the vessels in a freezer and defrosting them with hot water.

IDEA

Vascular anastomosis was conducted as follows. We harvested and trimmed vessels that are suitable for microsurgical training. The vessels were obtained from postoperative discarded tissues, namely, resected tissues except examined lymph nodes in the neck or axilla, or inguinal lymph node dissection (Fig. 1A). Subsequently, we placed the vessels in a small specimen container

Fig. 1. Vessels preserved over the short term

(A) Artery and vein harvested and trimmed from resected tissues except examined lymph nodes in lymph node dissection. Red and blue arrows indicate the artery and vein, respectively. (B) Vessels shown in Fig. 1A placed in a small specimen container with sterile saline and stored in a freezer. (C) Vessels shown in Fig. 1A defrosted with hot water after 3 days. Red and blue arrows indicate the artery and vein, respectively.

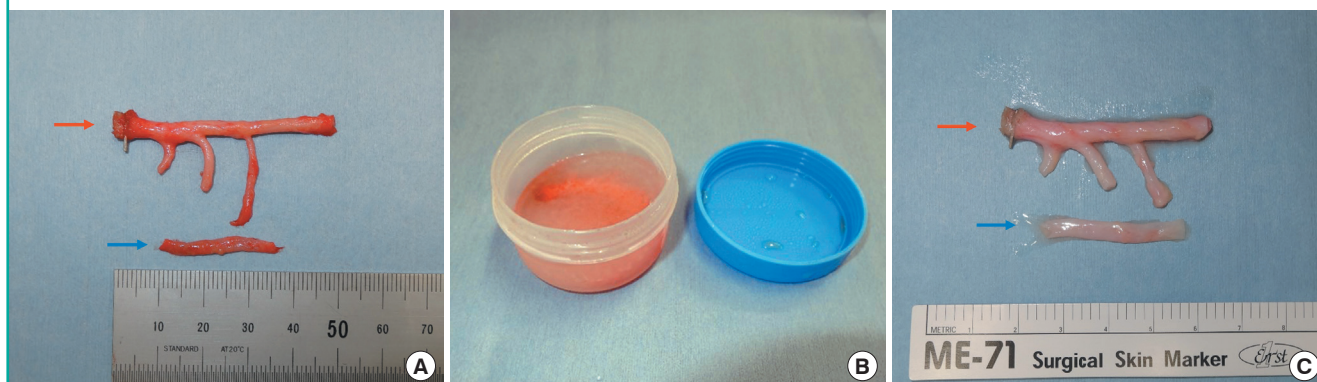

Table 1. Preserved vessels for microsurgical training

Variable	Artery (n = 7)	Vein (n = 23)
Vessel diameter (mm)	2.3 (2.0–3.0)	3.0 (1.8–4.0)
Vessel length (cm)	3.5 (2.0–5.0)	5.2 (2.0–12.0)
Preservation period (yr)	3.0 (0.3–5.0)	

Values are presented as mean (range).

Table 2. State of vascular wall according to preservation period

State of vascular wall	Preservation period		
	≤ 1 yr and 6 mo	> 1 yr and 6 mo, ≤ 3 yr	> 3 yr
White, good elasticity	5	10	0
White and yellowish, moderate elasticity	0	0	3
White and yellowish, poor elasticity	0	4	4
Grey, poor elasticity	0	0	4

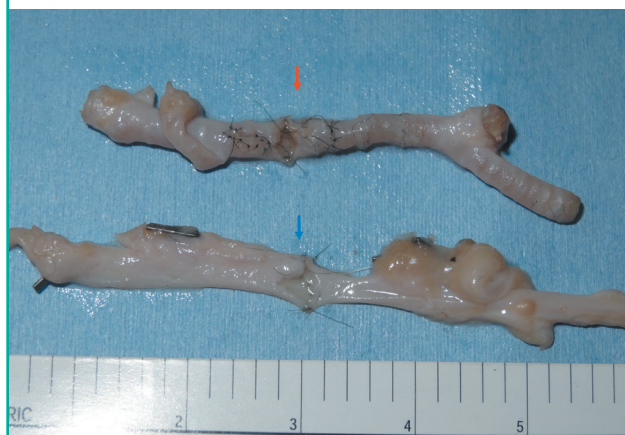Values are presented as the number of vessels used for microsurgical training.

with sterile saline (regardless of the presence of blood) and stored them in a freezer (Fig. 1B). The container was defrosted for about 10 minutes with hot water, and the vessels were removed and used for microsurgical training (Fig. 1C). After the training, we returned the vessels to the container and stored them in the freezer again. Our preserved vessels for microsurgical training in July 2016 are shown in Table 1.

Based on our experience, the same long vessels can be used numerous times for about 4 years in microsurgical training (Fig. 2). The state of the vascular wall according to the preservation period is shown in Table 2. Over the short to medium term (≤ 1 year and 6 months), the vascular wall was white and exhibited good elasticity in all vessels. Over the long term (> 1 year and 6 months and ≤ 3 years), the vascular wall appeared white and

Fig. 2. Vessels preserved over the long term

Artery and vein used for microsurgical training numerous times, for 4 years. The vessel walls were excised longitudinally and exhibited good inner membrane. Red and blue arrows indicate the artery and vein, respectively.



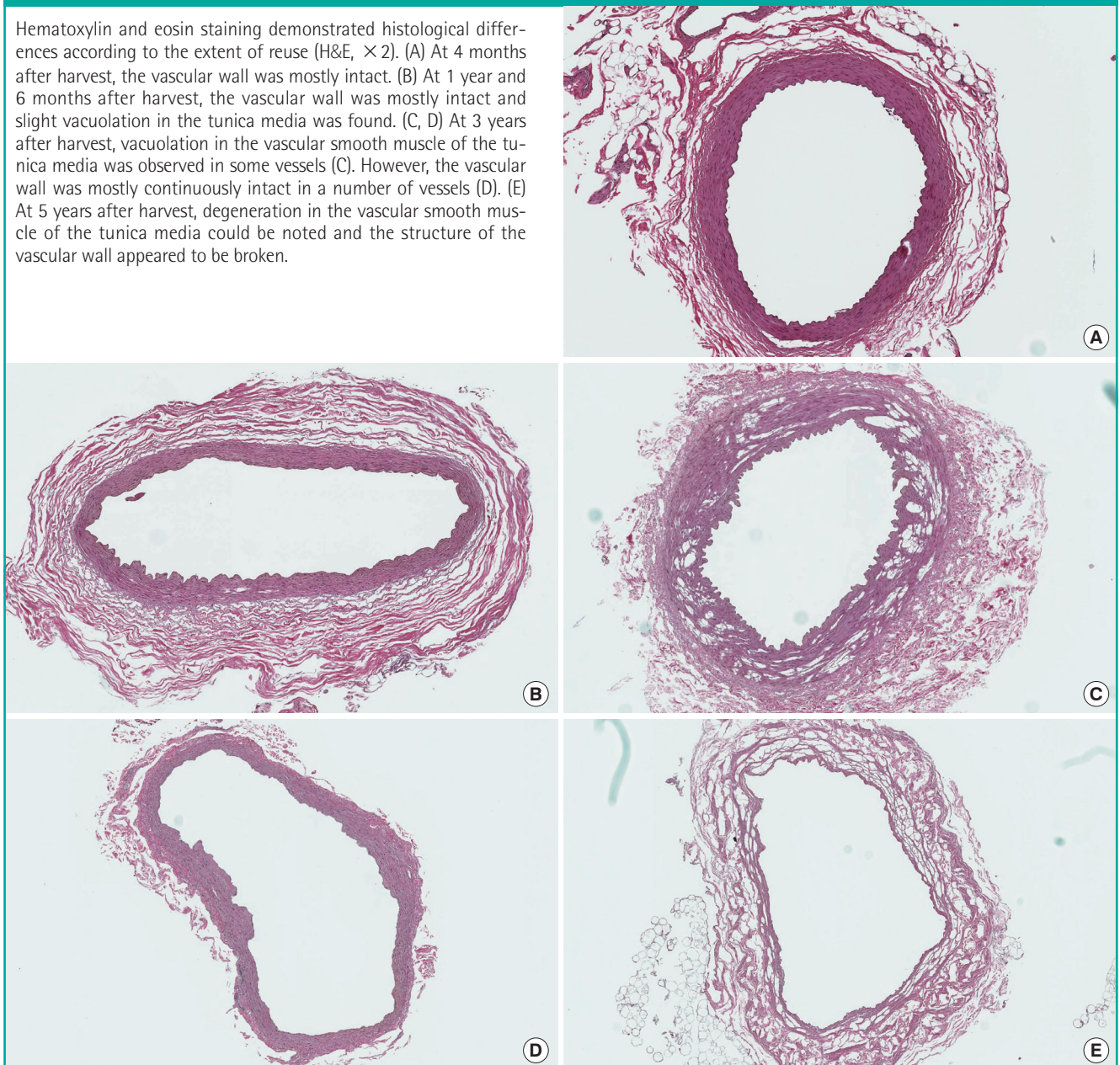
showed good elasticity in many vessels, whereas in some vessels, the wall was white and yellowish, and exhibited poor elasticity. Over the very long term (> 3 years), the vascular wall showed poor elasticity in many vessels, whereas in some vessels, it was white and yellowish, and moderate elasticity was observed.

In histologic findings, the vascular wall was mostly intact at 4 months and 1 year and 6 months after harvest. Vacuolation in the vascular smooth muscle of the tunica media was found in some vessels. However, the vascular wall was mostly intact in a number of vessels, 3 years after harvest, and degeneration in the vascular smooth muscle of the tunica media was very noticeable at 5 years after harvest (Fig. 3).

Precautionary measures should be followed in the storage and retrieval of human vessels: the container should not be heated rapidly, as with, for example, a microwave oven, and the vessel

Fig. 3. Histological difference by extent of reuse

Hematoxylin and eosin staining demonstrated histological differences according to the extent of reuse (H&E, $\times 2$). (A) At 4 months after harvest, the vascular wall was mostly intact. (B) At 1 year and 6 months after harvest, the vascular wall was mostly intact and slight vacuolation in the tunica media was found. (C, D) At 3 years after harvest, vacuolation in the vascular smooth muscle of the tunica media was observed in some vessels (C). However, the vascular wall was mostly continuously intact in a number of vessels (D). (E) At 5 years after harvest, degeneration in the vascular smooth muscle of the tunica media could be noted and the structure of the vascular wall appeared to be broken.



should not be placed with tap water, in order to avoid bacterial vessel corrosion.

All patients provided informed consent for the use of resected tissues, except the examined lymph nodes in the lymph node dissection, which were discarded after clinical research including microsurgical training.

DISCUSSION

Nonbiological models for microsurgery training, such as silicon tubes, are easy to obtain and reuse [1]. Delayed tests can be performed on successful vascular anastomosis in viable biological

models, such as rats [2]. Nonviable biological models, such as chicken thigh vessels that have been widely used in previous reports, are easy to obtain and are structurally similar to human vessels [3]. However, the texture and hardness of nonbiological models are quite different from those of human vessels; they are used as models for students acquiring a basic set of microsurgery skills. Having access to a laboratory animal facility is sometimes difficult because of the expense and limited availability of viable biological models from a breeder. Ideally, trainees should familiarize themselves with the use of human vessels instead of chicken thigh vessels as early as possible.

Various models that use human vessels in microsurgical train-

ing have been reported [4,5]. However, the use of discarded tissues in lymph node dissection has not been investigated. Furthermore, the possibility of reusing human vessels in microsurgical training over the long term has not been clearly elucidated. Resected tissues, except the examined lymph nodes in lymph node dissection, are often discarded. These tissues include several vessels with a diameter of approximately 2–3 mm, and therefore, they are useful models for microsurgical training similar to actual vascular anastomosis. Vessels are often obtained mainly in lymph node dissections of malignant skin tumors in departments of plastic surgery, and sometimes in lymph node dissections of malignant tumors during joint surgery in other departments. However, the availability of these vessels is limited, particularly in general hospitals, where these surgeries are not usually performed. Furthermore, the long vessels of the vascular wall that are suitable for training are not often obtained. Therefore, vessels, particularly long ones, should be effectively preserved and used for as long as possible in microsurgical training.

With our technique, the vessels were harvested and stored in a freezer. Trainees defrosted these vessels with hot water, and could easily and repeatedly use them in microsurgical training over the long term, as needed. Gross appearance and histologic findings in our preserved vessels showed that the vascular wall could be optimally stored for microsurgical training for about 3–4 years after harvest. The medical residents in our department underwent microsurgical training once or twice a week

and could perform well in actual vascular anastomosis procedures.

We recommend the use of discarded tissues in lymph node dissection as a source of reusable human vessels for microsurgery training models. The use of these vessels is cost-effective and can provide long-term models for microsurgical training that closely resembles real procedures.

REFERENCES

1. Meier SA, Lang A, Beer GM. Polyurethane vessels for microvascular surgical training to reduce animal use. *ALTEX* 2004; 21:135-8.
2. Shurey S, Akelina Y, Legagneux J, et al. The rat model in microsurgery education: classical exercises and new horizons. *Arch Plast Surg* 2014;41:201-8.
3. Krishnan KG, Dramm P, Schackert G. Simple and viable in vitro perfusion model for training microvascular anastomoses. *Microsurgery* 2004;24:335-8.
4. Allouni A, Amer T, Ismail M, et al. The human umbilical cord: a model for microsurgical training. *J Hand Microsurg* 2014;6:110-2.
5. Seyhan T, Ozerdem OR. Microsurgery training on discarded abdominoplasty material. *Plast Reconstr Surg* 2006;117: 2536-7.