

## Notes

### Conflict of interest

No potential conflict of interest relevant to this article was reported.

### Ethical approval

The study was performed in accordance with the principles of the Declaration of Helsinki. Written informed consent was obtained.

### Patient consent

The patients provided written informed consent for the publication and the use of their images.

## References

1. Malik S, Afzal M. Ulnar aplasia, dysplastic radius and paraxial oligodactyly: rare longitudinal limb defect in a sporadic male child. *J Res Med Sci* 2013;18:818-21.
2. Christopher CS, Neufeld SK. Ulnar ray deficiency. *Hand Clinics* 1998;14:65-75.
3. Broudy AS, Smith RJ. Deformities of the hand and wrist with ulna deficiency. *J Hand Surg Am* 1979;4:304-15.

## Early definitive treatment of partial-thickness alkali burns with tangential excision and biobrane

Yee Onn Kok<sup>1</sup>, Si Jack Chong<sup>1</sup>, Adi Basuki<sup>2</sup>,  
Bien Keem Tan<sup>1</sup>

<sup>1</sup>Department of Plastics, Reconstructive and Aesthetic Surgery, Singapore General Hospital, Singapore; <sup>2</sup>Faculty of Medicine, Universitas Indonesia, Jakarta, Indonesia

**Correspondence:** Yee Onn Kok  
Department of Plastics, Reconstructive and Aesthetic Surgery, Singapore General Hospital, Outram road, Singapore  
Tel: +6590065798, Fax: +62740094  
E-mail: kokyeonn@gmail.com

Received: 14 Mar 2017 • Revised: 17 Jul 2017 • Accepted: 5 Sep 2017  
pISSN: 2234-6163 • eISSN: 2234-6171  
<https://doi.org/10.5999/aps.2017.00507>  
*Arch Plast Surg* 2018;45:193-195



Copyright © 2018 The Korean Society of Plastic and Reconstructive Surgeons  
This is an Open Access article distributed under the terms of the Creative Commons Attribution Non-Commercial License (<http://creativecommons.org/licenses/by-nc/4.0/>) which permits unrestricted non-commercial use, distribution, and reproduction in any medium, provided the original work is properly cited.

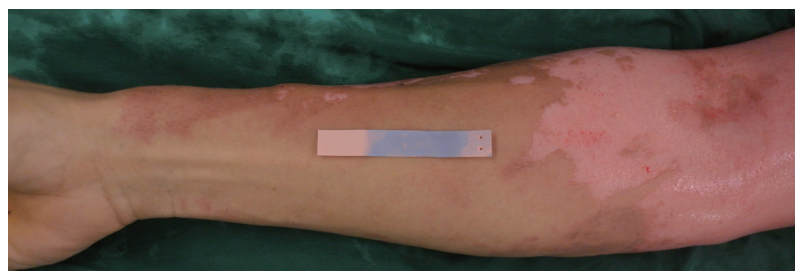
Copious irrigation, early tangential excision, and dressing are standard treatments for alkali burns [1]. Biobrane is a biosynthetic dressing widely used for partial-thickness burns. However, its use to treat alkali burns has rarely been discussed in the literature.

A 34-year-old male suffered a partial-thickness alkali burn caused by accidental paint solvent spillage (Taxite 4000, pH 10) over his face, neck, chest, and hand (11% of total body surface area). Immediate hourly copious irrigation was commenced before a same-day operative scrubdown.

After intraoperative irrigation and scrubbing with neutralizing chlorhexidine gluconate 4% liquid soap (pH 5.0–6.5), only the upper limbs were still alkaline (Fig. 1). Hence, we proceeded with ultra-thin tangential excision and debridement over the right upper limb until a litmus test indicated a neutral pH.

Biobrane was applied onto the dry clot-free wound bed with sterile Hypafix (Fig. 2). The Biobrane adhered well, was sequentially trimmed, and the wound was exposed by postoperative day 12. The right arm healed by 1 month postoperatively (Fig. 3). Minimal scars were present, only on the medial portion of the right hand, at a 1-year follow-up (Fig. 4).

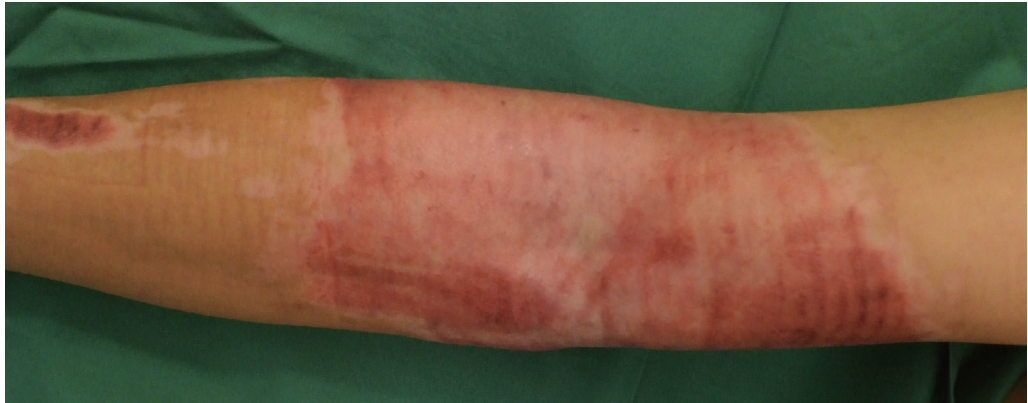After continuous irrigation, debridement via the



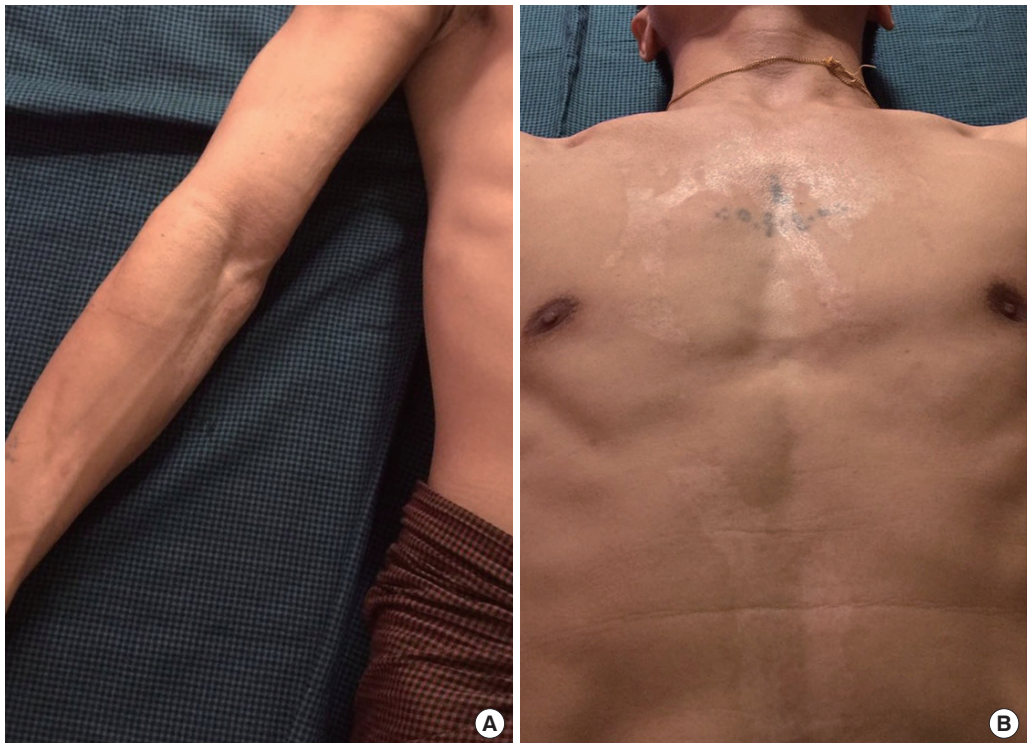**Fig. 1.** Superficial alkali burns of the upper extremity. The litmus test was mildly alkaline after irrigation and a surgical scrubdown.



**Fig. 2.** The burnt area was tangentially excised with a Zimmer air dermatome set to 18/1,000 cm. Punctate bleeding was observed, and the litmus test showed a neutral pH. Biobrane was applied in the standard fashion.



**Fig. 3.** Four-week postoperative image, showing complete healing without re-excision or skin grafting.



**Fig. 4.** (A) Right hand. (B) Thorax. The 1-year follow-up revealed a similar color to that of the surrounding skin, smooth surface, no contracture, good elasticity, and full range of movement with minimal scars.

tangential excision of alkali-devitalized tissue is necessary. The wound bed must be clean and neutralized, and a layer of dermis must be preserved for fibrin to bind to the applied Biobrane [2].

Biobrane is detached when it is dry and non-adherent to the wound. The advantages of tangential excision and Biobrane are that this strategy achieves coverage whilst avoiding skin graft donor site morbidity and the need for frequent dressing changes [2,3]. The patient had a shorter length of stay, better pain management, satisfactory aesthetic results, and less morbidity than would otherwise have been expected. Early irrigation with immediate Biobrane application and ultra-thin tangential excision is effective for partial-thickness alkali burns.

## Notes

### Conflict of interest

No potential conflict of interest relevant to this article was reported.

### Ethical approval

The study was performed in accordance with the principles of the Declaration of Helsinki. Written informed consents were obtained.

### Patient consent

The patients provided written informed consent for the publication and the use of their images.

ORCID

Adi Basuki <https://orcid.org/0000-0003-1778-9573>

References

1. Palao R, Monge I, Ruiz M, et al. Chemical burns: pathophysiology and treatment. *Burns* 2010;36:295-304.
2. Greenwood JE, Clausen J, Kavanagh S. Experience with biobrane: uses and caveats for success. *Eplasty* 2009;9:e25.
3. Wasiak J, Cleland H, Campbell F, et al. Dressings for superficial and partial thickness burns. *Cochrane Database Syst Rev* 2013;(3):CD002106.