



Two sequential free flaps for coverage of a total knee implant

Siew Weng Ng¹, Hui Chai Fong², Bien-Keem Tan²

¹Sweng Plastic Aesthetic and Reconstructive and Surgery, Singapore; ²Department of Plastic, Reconstructive and Aesthetic Surgery, Singapore General Hospital, Singapore

Knee revision arthroplasty following peri-prosthetic joint infections is a formidable challenge. Patients are at a high risk of recurrent infection, and the soft tissue over the revised implant is often of questionable quality. Flap reconstruction has improved the salvage rates of infected arthroplasties, and should be considered in all cases of revision arthroplasty. We present a challenging case requiring staged reconstruction with two free latissimus dorsi flaps after the initial use of a medial gastrocnemius flap.

Keywords Knee prosthesis / Free tissue flaps / Infection / Knee salvage / Latissimus dorsi flap

Correspondence: Siew Weng Ng
Sweng Plastic Aesthetic and
Reconstructive Surgery, 1 Farrer Park
Station Road #16-08, Connexion,
Singapore 217562
Tel: +65-6600-6868
Fax: +65-6443-8068
E-mail: sweng8@gmail.com

Received: 3 May 2017 • Revised: 17 Aug 2017 • Accepted: 19 Aug 2017

pISSN: 2234-6163 • eISSN: 2234-6171 • <https://doi.org/10.5999/aps.2017.00899> • Arch Plast Surg 2018;45:280-283

INTRODUCTION

Free flaps are our reconstructive modality of choice for large, complex knee wounds. We present a challenging case requiring 2 free flaps (Fig. 1) for coverage of an exposed implant during staged revision of an infected knee arthroplasty, after initial reconstruction with a medial gastrocnemius flap.

CASE

Our patient was a 66-year-old male in whom a giant cell tumor of the right femur had been excised 20 years earlier, with intraoperative cryotherapy and adjuvant radiotherapy. He presented with a 3-year history of right knee pain due to severe tri-compartmental osteoarthritis and underwent total knee arthroplasty. However, 9 months later, the patient developed chronic osteomyelitis in the medial half of the right tibial metaphysis with fistulation to the antero-medial aspect of the lower leg.

On initial debridement, the arthroplasty components were

found to be well fixed, with no evidence of loosening. The post-debridement defect was 4×2 cm with an exposed patellar tendon. Intraoperative tissue and bone cultures grew multi-resistant *Staphylococcus aureus*. A right medial gastrocnemius flap was raised to cover the patellar tendon. However, dehiscence of the flap occurred on the fourth postoperative day due to infection.

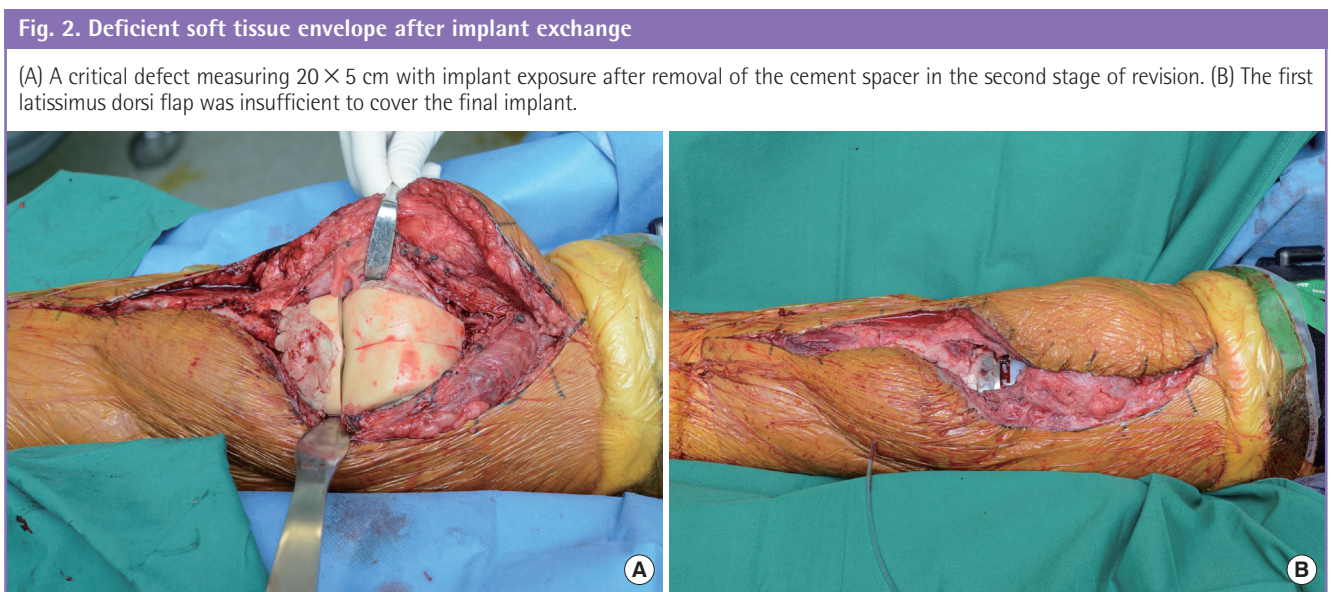
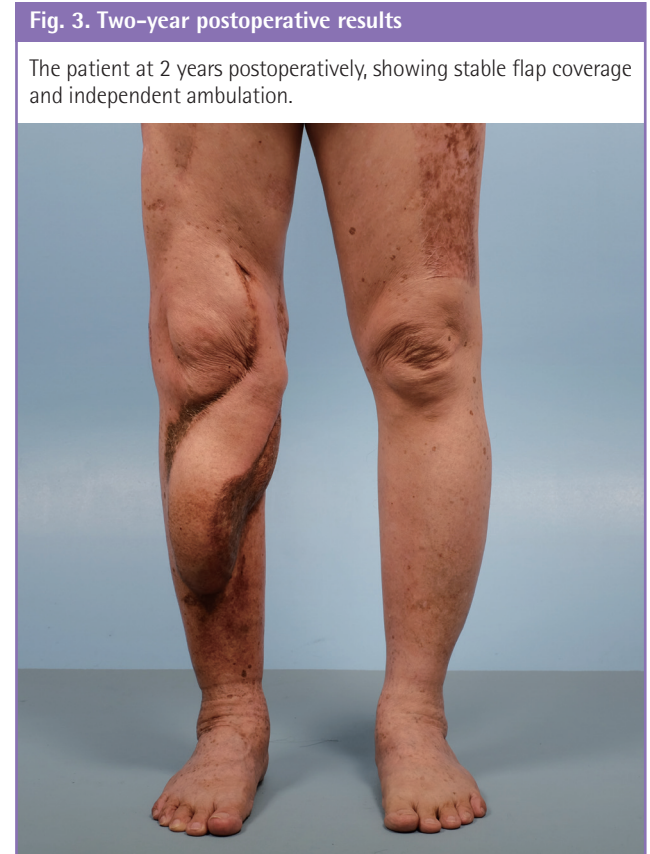
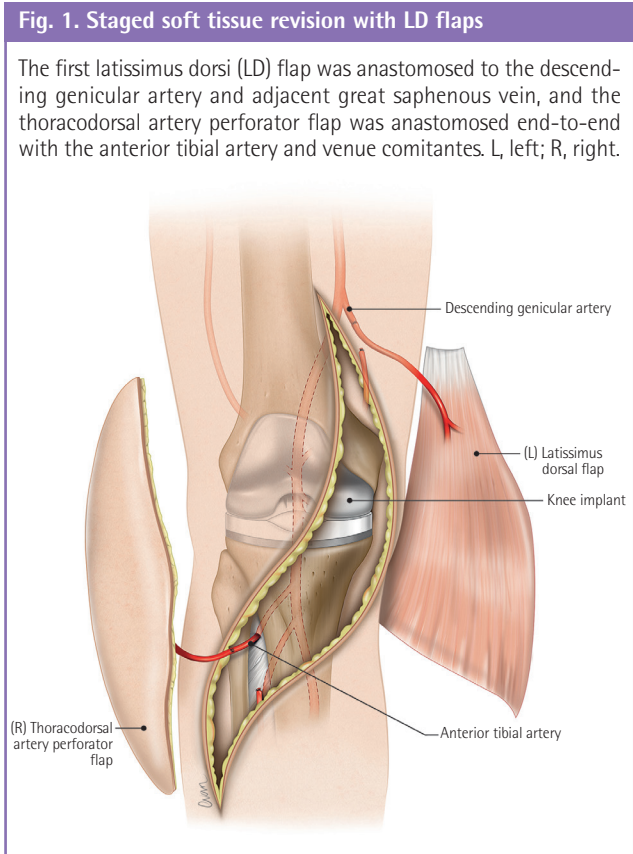
The patient then underwent staged revision with exchange to a dynamic spacer. Soft tissue reconstruction was delayed for a month due to initial patient instability resulting from sepsis, and negative-pressure dressings were applied as a temporizing measure. After final debridement, a defect of 15×5 cm over the anterior knee, with an exposed spacer, was reconstructed with a left latissimus dorsi (LD) flap. This was anastomosed end-to-end with the descending genicular artery and great saphenous vein. The patient recovered well and was discharged after 3 weeks.

Following 5 months of antibiotic therapy, the second stage of arthroplasty revision, with exchange of the spacer to a rotating hinge knee implant, was performed. Due to extensive synovectomy

tomy, scar release, and the size differential between the spacer and the implant, there was a defect measuring 20 × 5 cm (Fig. 2) with implant exposure following the exchange. With the patient supine, a right thoracodorsal artery perforator flap was raised to reconstruct the defect. Initially, the descending branch of the lateral circumflex femoral artery was explored, but the vessel calibre was inadequate. The anterior tibial vessels were then used

in an end-to-side fashion, but required revision to an end-to-end anastomosis due to vessel thrombosis. The second flap was inset adjacent to the first flap, on the antero-medial aspect of the knee.

The patient recovered uneventfully. He was started on wheelchair mobilization on postoperative day 12 and was discharged 3 weeks later. By the fourth postoperative month, the patient



had achieved a 70° arc of active flexion and was ambulant independently at home (Fig. 3). He is currently considering debulking of the distal pole of the flap.

DISCUSSION

The management of peri-prosthetic joint infection ranges from debridement with component retention to exchange arthroplasty, which may be performed as a single- or two-stage procedure. Late infection, which is considered to occur 3 weeks after arthroplasty [1], should be treated with removal of all components and staged revision, regardless of component stability [2].

Free flaps are our first choice for the reconstruction of large or complex knee wounds. They provide well-vascularized tissue from an area outside the zone of infection, and can be designed to address composite defects. It is preferable to use a thin myocutaneous flap, which allows a free range of knee flexion while providing durable coverage. Locoregional muscle flaps may not be the best option, since they undergo substantial atrophy within the first 6 months [3], and skin graft coverage may affect its pliability. However, this drawback may be mitigated if a myocutaneous free flap is planned in a subsequent stage of revision.

Finding a suitable recipient vessel in the knee can be challenging. While most knee defects occur anteriorly, the major vessels of the lower limb run posteriorly. In the setting of major trauma or infection, finding and preparing a suitable recipient vessel outside the zone of injury often requires extensive dissection.

Recipient vessels may be found proximally (descending genicular artery, superficial femoral artery, or descending branch of the lateral circumflex femoral artery), distally (anterior tibial, posterior tibial, or peroneal artery), or posterior to the knee (popliteal, medial/lateral genicular, or sural artery) [4]. In their review of 34 free flap knee reconstructions, Louer and colleagues had an 18% vessel re-exploration rate. In their comparison of recipient vessels, they did not find a statistically significant difference in the rate of thrombosis based on the choice of recipient vessel, or the region of the leg where the anastomosis was performed [5].

For anterior knee defects, our recipient vessel of choice is the descending genicular artery. Placing the vessel anastomosis proximally to the knee ensures that the pedicle retains an orthograde lie, optimising the venous drainage of the flap. The great saphenous vein, lying in close proximity, is used as the main draining vein, while the venae comitantes of the descending genicular artery are used as secondary veins.

The descending genicular artery originates from the superficial femoral artery 13–15 cm proximally to the knee joint and passes in the plane between the adductor magnus and vastus

medialis, giving rise to muscular, cutaneous, and articular branches before anastomosing with the inferior medial genicular artery. It may be exposed through an exploratory incision in the distal thigh, between the vastus medialis and sartorius. Medial retraction of the sartorius will expose the muscular branch of the artery, found immediately posterior to the vastus medialis. The vessel calibre is an excellent match for the thoracodorsal pedicle. If the descending genicular artery is not available, other options include the superficial femoral artery (used in an end-to-side fashion) or the descending branch of the lateral circumflex femoral artery.

In a situation where free tissue transfer is not feasible owing to patient co-morbidity, local muscle flaps may be considered. In their series on gastrocnemius flap reconstruction of knee and mid-tibial defects, El-Shazly and Kamal [6] described several useful modifications to increase the rotational arc and dimensions of the medial and lateral heads of the gastrocnemius for coverage of larger wounds. These included division of the muscular insertion at the femoral condyle, increasing the arc of rotation by 7 cm, longitudinal scoring of the fascia on the deep surface of the muscle to increase the breadth of the flap, and separating the medial and lateral heads for composite coverage of more extensive defects. These modifications allowed satisfactory coverage of defects of up to 216 cm² in the middle third and distal upper third of the leg.

In revision knee arthroplasty, extensive synovectomy is often required before the suprapatellar pouch, posterior femoral recess, or medial and lateral gutters can be reconstituted. Femoral and/or tibial augments are often used to balance the flexion-extension gap, resulting in a larger arthroplasty following removal of the cement spacer. This causes a relative deficiency in the soft tissue envelope, which in our case produced a defect that was long and narrow, with implant exposure above and below the knee. The prior history of radiotherapy and cryotherapy compounded the suboptimal tissue quality. This necessitated the use of a second long, narrow flap with a long pedicle, requirements well fulfilled by the thoracodorsal artery perforator flap. This flap can be harvested in a supine fashion [7], permitting concurrent debridement and flap harvest, which is not possible if flap harvest necessitates lateral positioning of the patient. Another option, the vertical rectus abdominis myocutaneous flap, also allows simultaneous harvest, but the skin paddle may be too thick, and a pure muscle flap may not be the best option, as discussed above.

Our case highlights the difficulties of free flap reconstruction during staged revision of an infected knee arthroplasty. Regional flap options may be exhausted, the soft tissue envelope may be tight, and repeat surgery limits recipient vessel options. In the

setting of severe infection, the first flap provides soft tissue coverage of the spacer and sterilizes the field, but may be insufficient following extensive synovectomy and implant exchange in the second stage. In revision arthroplasty, the reconstructive surgeon should anticipate the need for a staged soft tissue reconstruction, or risk critical exposure of the revised prosthesis.

NOTES

Conflict of interest

No potential conflict of interest relevant to this article was reported.

Patient consent

The patient provided written informed consent for the publication and the use of his images.

REFERENCES

1. Della Valle C, Parvizi J, Bauer TW, et al. American Academy of Orthopaedic Surgeons clinical practice guideline on: the diagnosis of periprosthetic joint infections of the hip and knee. *J Bone Joint Surg Am* 2011;93:1355-7.
2. Gehrke T, Alijanipour P, Parvizi J. The management of an infected total knee arthroplasty. *Bone Joint J* 2015;97-b:20-9.
3. Wettstein R, Largo RD, Raffoul W, et al. Laser scanning evaluation of atrophy after autologous free muscle transfer. *Ann Plast Surg* 2014;72:680-4.
4. Fang T, Zhang EW, Lineaweaver WC, et al. Recipient vessels in the free flap reconstruction around the knee. *Ann Plast Surg* 2013;71:429-33.
5. Louer CR, Garcia RM, Earle SA, et al. Free flap reconstruction of the knee: an outcome study of 34 cases. *Ann Plast Surg* 2015;74:57-63.
6. El-Shazly M, Kamal A. Practical guidelines for getting the most out of the gastrocnemius muscle flap units: a presented algorithm for the best flap choice. *Eur J Plast Surg* 2012;35:589-94.
7. Hwang KT, Youn S, Kim JT, et al. Use of latissimus dorsi flap pedicle as a T-junction to facilitate simultaneous free fibular flap inset in lower extremity salvage. *J Plast Reconstr Aesthet Surg* 2012;65:517-20.