

## IMAGE

## Recurrent Advanced Lower Extremity Lymphedema Following Initial Successful Vascularized Lymph Node Transfer: A Clinical and Histopathological Analysis

Pedro Ciudad<sup>1,2</sup>, Shivprasad Date<sup>1</sup>, Oscar J Manrique<sup>1</sup>, Wei-Ling Chang<sup>1</sup>, Tsung-Chun Huang<sup>1</sup>, Tsung-Wei Chen<sup>3</sup>, Fabio Nicolì<sup>1</sup>, Michelle Maruccia<sup>1</sup>, Hung-Chi Chen<sup>1</sup>

<sup>1</sup>Department of Plastic and Reconstructive Surgery, China Medical University Hospital, Taichung; <sup>2</sup>Department of Biological Science and Technology, China Medical University, Taichung; <sup>3</sup>Pathology, China Medical University Hospital, Taichung, Taiwan

**Correspondence:** Pedro Ciudad  
Department of Plastic Surgery, China Medical University Hospital, 2 Yuh-Der Road, Taichung 40447, Taiwan  
Tel: +886-92-219-0216, Fax: +886-422020038  
E-mail: pciudad@hotmail.com

No potential conflict of interest relevant to this article was reported.

Received: 27 Jun 2016 • Revised: 22 Dec 2016 • Accepted: 27 Dec 2016  
pISSN: 2234-6163 • eISSN: 2234-6171  
<https://doi.org/10.5999/aps.2017.44.1.87>



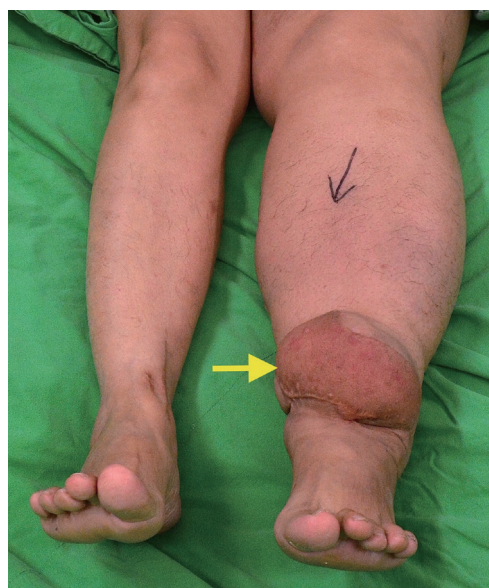Arch Plast Surg 2017;44:87-89  
Copyright © 2017 The Korean Society of Plastic and Reconstructive Surgeons  
This is an Open Access article distributed under the terms of the Creative Commons Attribution Non-Commercial License (<http://creativecommons.org/licenses/by-nc/4.0/>) which permits unrestricted non-commercial use, distribution, and reproduction in any medium, provided the original work is properly cited.

Vascularized lymph node transfer (VLNT) is a physiological approach for the treatment of lymphedema. Despite the reported clinical outcomes of VLNT [1-3], its effectiveness in advanced stages is still unpredictable, with variable outcomes seen among patients.

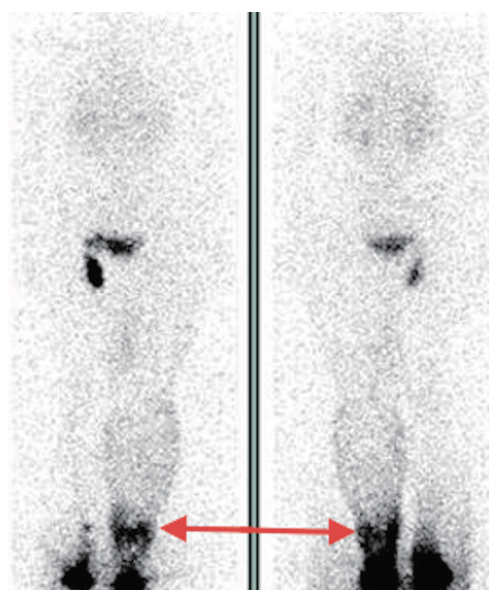
Although donor site morbidity following lymph node flap harvest has been reported [1], significant complications at the recipient site have rarely been reported. Herein, we report an unusual case of recurrent advanced lower extremity lymphedema, after initial successful surgical treatment with a free submental VLNT [3].

A 54-year-old woman underwent bilateral pelvic inguinal lymph node dissection and postoperative radiotherapy for cervical cancer. Thirty-six months later, she presented with advanced secondary lymphedema of the left lower limb and a history of repeated episodes of cellulitis. A submental VLNT to

the distal part of the affected limb was performed at another hospital. After six months, a substantial limb volume reduction was noted with no further episodes of cellulitis. Unfortunately, at a 1-year follow up, recurrent swelling of the entire affected limb was observed, which progressively increased in volume proximally to the transferred flap over the next 2 years. At this stage, the patient presented to our hospital for further assessment. Clinically, there was palpable fibrous, indurated tissue and a significant limb volume discrepancy in comparison to the contralateral limb. Surprisingly, the transferred flap demonstrated severe signs of enlargement. In addition, swelling was observed from the flap to the proximal aspect of the limb (Fig. 1).



**Fig. 1.** Advanced lymphedema recurrence after VLNT. A patient presented with features of advanced left lower extremity lymphedema recurrence after VLNT with gross enlargement of the previously transferred flap (yellow arrow).



**Fig. 2.** Lymphatic obstructions near the transferred flap. Lymphoscintigraphy revealed lymphatic obstructions at the level of the transferred flap (red arrow).

Lymphoscintigraphy revealed a lymphatic obstruction at the level of the transferred flap (Fig. 2). Following the clinical evaluation, we performed a further histopathological analysis of the transferred flap. A macroscopic examination revealed enlarged lymph nodes with a thickened capsule and fibrosis (Fig. 3). A microscopic examination with hematoxylin and eosin staining showed reactive lymphoid hyperplasia of the germinal center, focal vascular proliferation, and fibrotic changes in the lymph node (Fig. 4).

After the histopathological analysis, the patient underwent a modified Charles procedure [4] with extensive resection of the fibrotic subcutaneous tissue and the skin of the lymphedematous limb. Under the operating microscope, the transferred flap was subjected to a meticulous microsurgical debulking procedure [5]. In addition, the hypertrophic lymph nodes within the lymph node flap were identified and excised, taking care to avoid damage to the remaining normal lymph nodes and lymphatic channels. At a 9-month follow up, the patient did not report pain or any episodes of infection. She also reported a dramatic limb volume reduction and an improved ability to perform routine activities.

Physiological and excisional procedures have been

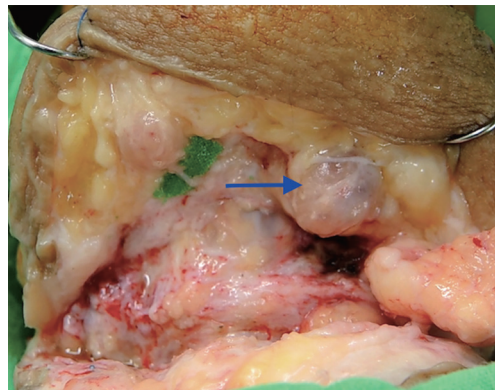
described for the surgical management of extremity lymphedema [2]. The common physiological procedures include VLNT and lymphovenous anastomosis [1,2]. Liposuction and the Charles procedure are the excisional procedures reserved mainly for advanced stages [1,2].

During the past decade, VLNT has been widely employed in the treatment of extremity lymphedema because of its promising results [1-3]. However, the isolated use of this technique for the treatment of advanced stages of lymphedema still remains controversial. In the current case, the patient initially reported improvement after VLNT. However, at a 1-year follow up, the patient developed clinical features suggestive of a lymphatic obstruction at the level of the transferred lymph node flap.

The swelling of the transferred flap and the resultant lymphatic obstruction may be attributed to several reasons, such as infection, scarring, or stenosis of the pedicle vein. However, on the basis of the histopathological and clinical results, we believe that the presence of dense fibrotic tissue on the recipient bed and proximity to the transferred flap gradually reduced the improved lymphatic drainage initiated by the VLNT, as demonstrated by lymphoscintigraphy. The resultant edema could have perpetuated the vicious cycle of lymph stagnation, fibrosis, hyperkeratosis, and infection.

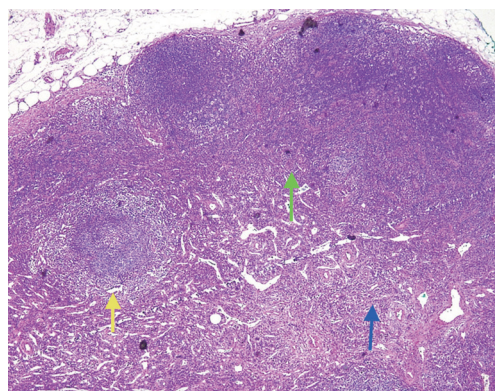
In the advanced stages of extremity lymphedema, clinical diagnosis, preoperative lymphatic imaging assessment, and selection of the surgical treatment are the cornerstones for successful outcomes. In our experience, in the cases of advanced lower extremity lymphedema, a combination of physiological and excisional procedures, such as the modified Charles procedure [4], should be considered in selected cases in order to improve the clinical outcomes and reduce the potential complications.

Although this communication discusses a single finding, to the best of our knowledge, this is thus far the first report of lymph node flap hyperplasia after VLNT. This case shows that VLNT is a good option for the microsurgical management of lymphedema of the extremities, as the patient reported volume reduction and no further episodes of cellulitis of the affected limb. However, we still need to understand more concepts regarding the physiology of VLNT in different stages of lymphedema more thoroughly, as the final results of this procedure remain unpredictable and vary among patients.



**Fig. 3.**

Enlarged lymph node. An enlarged lymph node found during an open biopsy of the transferred flap (blue arrow). A grossly thickened capsule and fibrotic septum are seen in the central part of the lymph node.



**Fig. 4.**

Histological findings. Histological findings with hematoxylin and eosin staining under low magnification showed reactive lymphoid hyperplasia of the germinal center (yellow arrow), focal vascular proliferation (green arrow), and fibrotic changes (blue arrow) in the lymph node.

## References

1. Scaglioni MF, Arvanitakis M, Chen YC, et al. Comprehensive review of vascularized lymph node transfers for lymphedema: Outcomes and complications. *Microsurgery* 2016 Jun 7 [Epub]. <http://doi.org/10.1002/micr.30079>.
2. Ciudad P, Maruccia M, Socas J, et al. The laparoscopic right gastroepiploic lymph node flap transfer for upper and lower limb lymphedema: technique and outcomes. *Microsurgery* 2015 Jul 15 [Epub]. <http://doi.org/10.1002/micr.22450>.
3. Cheng MH, Huang JJ, Nguyen DH, et al. A novel approach to the treatment of lower extremity lymphedema by transferring a vascularized submental lymph node flap to the ankle. *Gynecol Oncol* 2012;126:93-8.
4. Sapountzis S, Ciudad P, Lim SY, et al. Modified Charles procedure and lymph node flap transfer for advanced lower extremity lymphedema. *Microsurgery* 2014;34:439-47.
5. Ciudad P, Yeo MS, Sapountzis S, et al. Microsurgical debulking procedure after free lymph node flap transfer. *Microsurgery* 2014;34:670-1.