

Acellular Dermal Matrices and Paraffinoma: A Modern Tool for a Nearly Obsolete Disease

Luca Grassetto^{1*}, Matteo Torresetti^{1*}, Alessandro Scalise¹, Davide Lazzeri²,
Giovanni Di Benedetto¹

¹Department of Plastic and Reconstructive Surgery, Marche Polytechnic Medical School, Ancona; ²Plastic and Reconstructive Surgery Unit, Villa Salaria Clinic, Rome, Italy

Case Report

Paraffinoma is a destructive complication of paraffin oil injection, usually associated with massive tissue destruction, thus requiring radical surgery and subsequent complex reconstruction. Although breast and penile paraffinomas have been widely described and their management is quite standardized, paraffinomas of the knee are still rare and only few case reports or small case series are available in the current literature. We describe the case of a 77-year-old man with a large paraffinoma of the right knee that occurred after self-injection of paraffin oil, 58 years before. He underwent wide surgical resection of the soft tissues overlying the knee and subsequent two-stage reconstruction by using acellular dermal matrix and, after 20 days, split-thickness skin grafts. Follow-up after 16 months showed no signs of skin ulcerations or inflammation, with an overall improvement in function. Even though conventional flap reconstructions may be still useful, the authors believe that acellular dermal matrices represent a safe, reliable, and less invasive alternative for challenging soft tissue reconstructions even in elderly patients with multiple medical problems.

Keywords Paraffinoma / Knee / Acellular dermal

Correspondence: Matteo Torresetti
Department of Plastic and
Reconstructive Surgery, Marche
Polytechnic University Medical School,
Regional Hospital, Via Conca 1–60020
Ancona, Italy
Tel: +39-0715965226
Fax: +39-0715963453
E-mail: torresetti.matteo@gmail.com

*The first two authors contributed
equally to this work.

No potential conflict of interest relevant
to this article was reported.

Received: 27 May 2016 • Revised: 24 Aug 2016 • Accepted: 31 Aug 2016
pISSN: 2234-6163 • eISSN: 2234-6171 • <https://doi.org/10.5999/aps.2017.44.3.234> • Arch Plast Surg 2017;44:234-237

INTRODUCTION

Paraffin oil injection is an old and obsolete procedure that has been used all over the world both for therapeutic and aesthetic purposes. It was introduced into medical practice around 1900 as a filler for subcutaneous defects; since then, it was largely adopted as a useful tool for the management of rhinological deformities, palatal defects, hernia repairs, pulmonary tuberculosis (as an alternative to surgical thoracoplasty), treatment of baldness, breast, penile, and facial augmentation. Furthermore, some cases of self-injection into the upper and lower limbs to avoid compulsory military service have been reported. Unfortunately, de-

spite the initial good results, several short- and long-term destructive complications were described due to the migration and deposition of paraffin, and this procedure was therefore abandoned [1,2]. After the immediate inflammatory reaction, patients usually reported a relatively long latent phase, finally resulting in the formation of multiple foreign body granulomas known as paraffinomas, which are associated with massive tissue destruction, usually requiring radical surgery and subsequent complex reconstruction. Although breast and penile paraffinomas have been widely described and their management is quite standardized, paraffinomas of the knee are still rare, and only a few case reports or small case series are available in the

current literature (Table 1).

CASE

We describe the case of a 77-year-old Caucasian man who was referred to our clinic because of a swollen and painful right knee, skin ulcerations, fistulae, and functional limitation. He denied any history of recent trauma or infections; nonetheless, the patient admitted to the self-injection of paraffin oil 58 years before to treat a subcutaneous defect occurring after a large post-traumatic hematoma. Physical examination revealed dark and hard skin, forming firm plaques (27 × 21 cm) that involved superficial

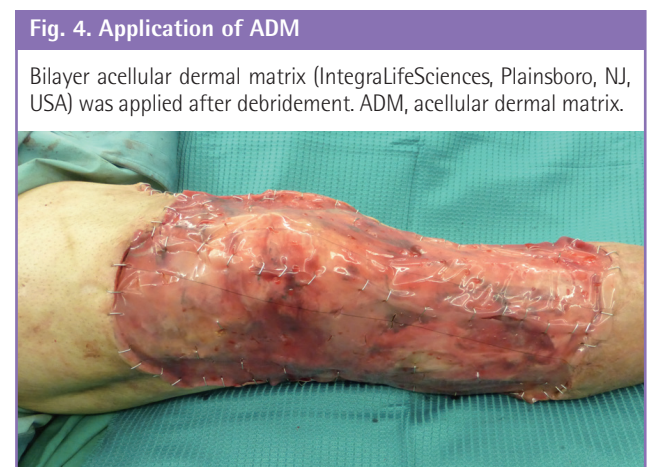
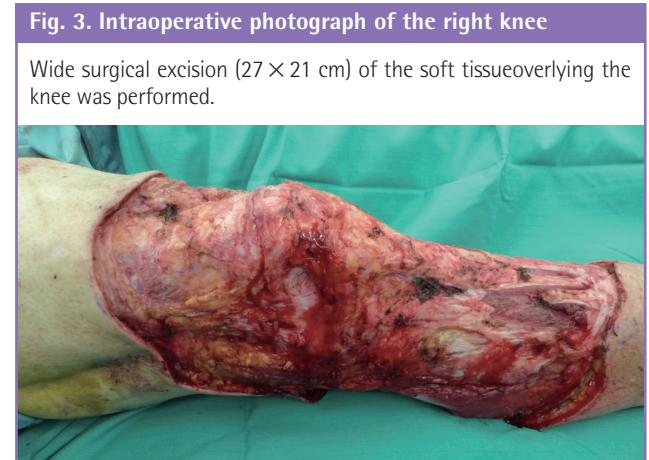
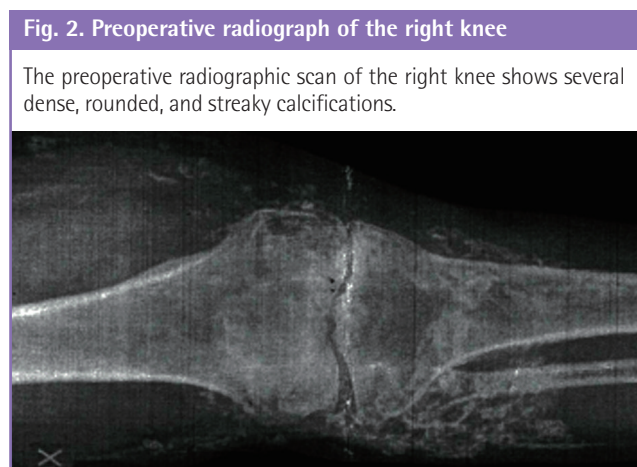
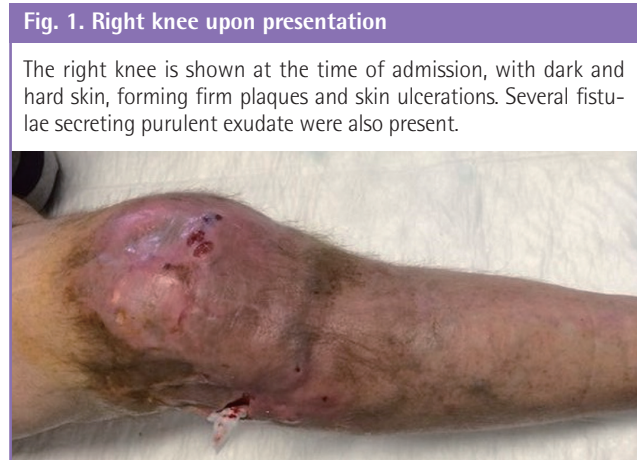layers of the anterolateral aspect of the knee; small ulcerations and fistulae secreting purulent exudate were also observed (Fig. 1). The patient reported worsening limitation of the flexion and extension of the right knee during the previous 4 months. Radiological examination revealed soft tissue swelling with several dense and streaky calcifications (Fig. 2). Blood test findings were within normal limits. The patient reported type 1 diabetes and was a heavy smoker.

The patient underwent a wide surgical resection of the skin overlying the knee, which was firmly adherent to the joint capsule, and a nearly circumferential, full-thickness excision up to the skeletal muscle in the distal third of the thigh and proximal

Table 1. A summary of the literature on paraffinoma of the knee (literature review)

Authors	Knee (case)	Mean age (yr)	Size (cm)	Reconstruction	Mean duration of latent phase (yr)	Follow-up (mo)
Kleinberg [3]	1	27	5 × 10 cm	Direct closure	8	NA
Di Benedetto et al. [2]	6	46	4 × 5 cm (5 cases, NA)	Local fasciocutaneous flap (5 cases, NA)	15	18 (5 cases, NA)
Catalano et al. [1]	1	90	NA	NA	55	NA
Grassetti et al. [4]	1	63	5.5 × 4 cm	Anterolateral thigh free flap	60	6

NA, not available.



third of the leg (Fig. 3). As the presence of risk factors such as diabetes and smoking advised against the use of microsurgical techniques, a less invasive two-stage reconstruction using bilayer acellular dermal matrix (IntegraLifeSciences, Plainsboro, NJ, USA) (Fig. 4) and subsequent split-thickness skin grafts (STSG) after 20 days was performed. Histological examination revealed no evidence of any paraffin; nonetheless, dense and fibrous connective tissue with chronic inflammatory cell infiltrate was observed. Several optically empty vacuolar structures surrounded by foreign-body-type multinucleated giant cells were also detected, suggesting an oleo granulomatous reaction to foreign material. Postoperative recovery was uneventful and the patient was discharged 4 days after the second operation. Follow-up after 16 months showed no signs of skin ulcerations or inflammation, with an overall improvement in function (Figs. 5, 6). A range of motion for the right knee from 10° to 100° during active mobilization and from 0° to 110° during passive mobiliza-

tion was measured (Fig. 7).

DISCUSSION

Although paraffin oil injection has been abandoned as of several decades ago, severe long-term complications may still be encountered in clinical practice. As spontaneous regressions of paraffinomas have not been reported, the only recommended therapy usually consists of complete removal of the affected skin and subsequent reconstruction. Breast paraffinoma is a well-described complication of paraffin oil injection for breast augmentation and its management mainly consists of subcutaneous mastectomy with implant or a myocutaneous flap reconstruction. Reconstruction after penile paraffinoma often requires

Fig. 5. Right knee 16 months postoperatively

A photograph of the right knee at 16-month follow-up showing a good anatomical contour of the knee.

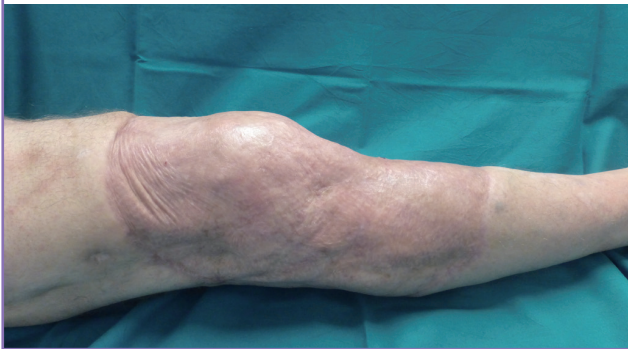

Fig. 6. Postoperative right knee in flexion

A photograph shows the overall functional improvement with the knee flexed.

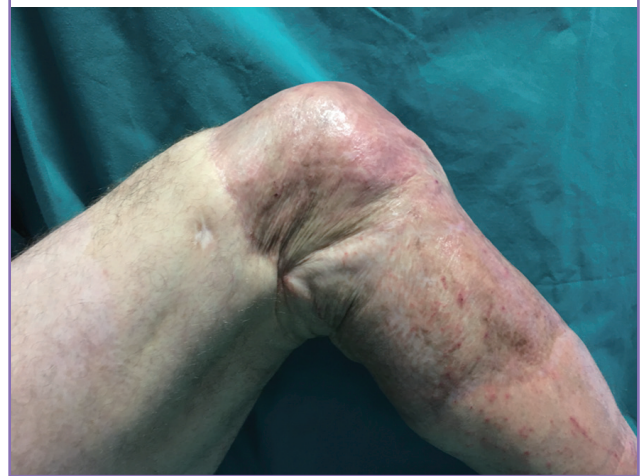
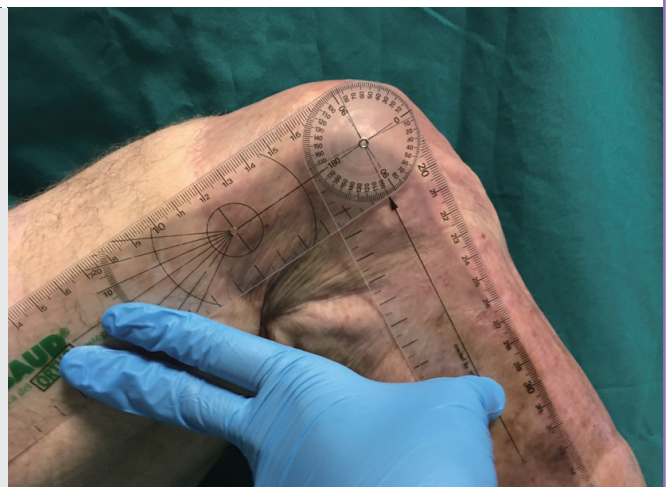
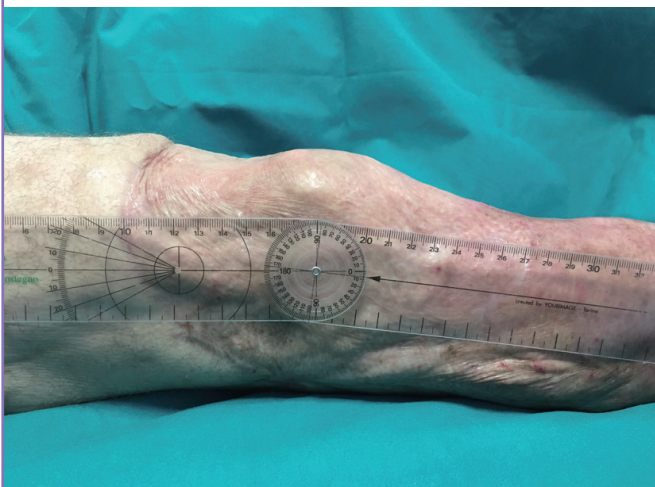
Fig. 7. Postoperative range of motion

A photograph shows the range of motion for the right knee from 10° to 100° during active mobilization.



skin grafts or bilateral scrotal flaps [2].

Paraffinoma of the knee is a still rare phenomenon and few cases are recorded in the literature (Table 1). As it usually consists of massive infiltration and destruction of the surrounding tissues, thus compromising the use of available local flaps, its treatment is often challenging. Furthermore, when joints are involved, a dissection plane between the affected tissue and peri-articular structures cannot be easily found. Up to now, soft tissue reconstructions after paraffinoma of the knee have been performed by using direct wound closure, or local or free flaps [1-4]. We propose a new alternative reconstruction using acellular dermal matrix (ADM) and STSG for a reliable and less invasive procedure. Skin grafts have not been used on joint surfaces in the past due to their high rate of contraction, with substantial morbidity such as restriction of joint mobility, often requiring multiple corrective surgical procedures. Nevertheless, in the last few years it has been demonstrated that the use of an artificial dermis that contains elastin is very effective from a functional and aesthetic standpoint for minimizing contractures and enhancing skin elasticity. Currently, ADM is a standard tool in reconstructive surgery and has been demonstrated to provide pliable and durable skin cover with minimal donor site morbidity or long-term postoperative contractures. The surgical technique and postoperative care are now simpler and the hospital stay is shorter, and indications for the use of ADM products have now widened to include joints [5]. ADM seems to be a safe and reliable alternative to free tissue transfer in elderly patients with several comorbidities, thus allowing challenging soft tissue reconstructions even in a compromised host.

Soft tissue reconstruction after paraffinoma of the knee can be very complex, due to the paucity of local available tissues and the functional relevance of this area. Furthermore, as paraffin oil injection is an obsolete procedure, these lesions are usually diagnosed as late complications in elderly patients who may present multiple medical problems; in that case, free tissue transfer can be associated with elevated rates of perioperative morbidity and mortality. Thus, ADM seems to be a safe, reliable and simple tissue-engineered alternative for challenging reconstructions that require a large amount of soft tissue.

To our knowledge, the present case is the first report of the application of ADM for the management of paraffinoma in an uncommon site such as the knee.

REFERENCES

1. Catalano OA, Dal Pozzo F, Grifi DN, et al. Paraffinoma of the knee. *Skeletal Radiol* 2003;32:485-8.
2. Di Benedetto G, Pierangeli M, Scalise A, et al. Paraffin oil injection in the body: an obsolete and destructive procedure. *Ann Plast Surg* 2002;49:391-6.
3. Kleinberg S. Paraffinoma of the knee. *Ann Surg* 1926;84:616-8.
4. Grassetti L, Lazzeri D, Torresetti M, et al. Paraffinoma of the knee 60 years after primary injection. *Arch Plast Surg* 2013;40:789-90.
5. Hur GY, Seo DK, Lee JW. Contracture of skin graft in human burns: effect of artificial dermis. *Burns* 2014;40:1497-503.