

nodules recovered completely without scarring. Therefore, physicians who perform aesthetic procedures should be aware that late-onset painful nodules are likely to be caused by a bacterial infection such as MRSA, and identification of the bacteria may be preferable to hastily pursuing other treatment possibilities.

## References

1. Alijotas-Reig J, Garcia-Gimenez V, Vilardell-Tarres M. Late-onset immune-mediated adverse effects after poly-L-lactic acid injection in non-HIV patients: clinical findings and long-term follow-up. *Dermatology* 2009;219:303-8.
2. Choi WY, Cho HW, Lee DW. Complications of injectable soft tissue filler. *Arch Aesthetic Plast Surg* 2015;21:1-6.
3. Sadashivaiah AB, Mysore V. Biofilms: their role in dermal fillers. *J Cutan Aesthet Surg* 2010;3:20-2.

## Spontaneous Pseudoaneurysm of the Proximal Occipital Artery Presenting as a Neck Mass

Tae Gon Kim<sup>1</sup>, Jin Ho Lee<sup>1</sup>, Kyu Jin Chung<sup>1</sup>, Jun-Ho Lee<sup>1</sup>, Yong-Ha Kim<sup>1</sup>, Chul Hoon Chang<sup>2</sup>

Departments of <sup>1</sup>Plastic and Reconstructive Surgery and <sup>2</sup>Neurosurgery, Yeungnam University College of Medicine, Daegu, Korea

**Correspondence:** Tae Gon Kim  
Department of Plastic and Reconstructive Surgery, Yeungnam University College of Medicine, 170 Hyeonchung-ro, Nam-gu, Daegu 42415, Korea  
Tel: +82-53-620-3483, Fax: +82-53-626-0705  
E-mail: kimtg0919@hanmail.net

No potential conflict of interest relevant to this article was reported.

Received: 23 Feb 2017 • Revised: 28 Mar 2017 • Accepted: 28 Mar 2017  
pISSN: 2234-6163 • eISSN: 2234-6171  
<https://doi.org/10.5999/aps.2017.44.3.249>  
*Arch Plast Surg* 2017;44:249-250

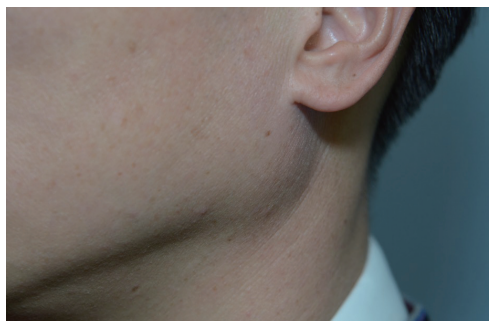Copyright © 2017 The Korean Society of Plastic and Reconstructive Surgeons  
This is an Open Access article distributed under the terms of the Creative Commons Attribution Non-Commercial License (<http://creativecommons.org/licenses/by-nc/4.0/>) which permits unrestricted non-commercial use, distribution, and reproduction in any medium, provided the original work is properly cited.

Occipital artery pseudoaneurysms are rare vascular lesions, and are most often reported as a consequence of trauma [1,2]. We report the rare case of a

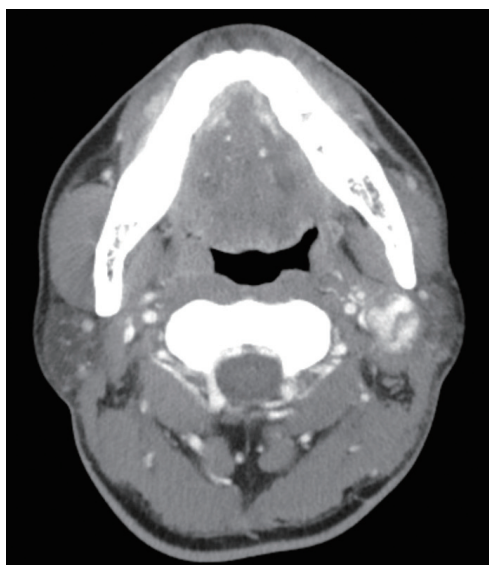
spontaneous pseudoaneurysm of the proximal occipital artery that presented as a neck mass.

A 44-year-old male patient presented with a pulsatile swelling lesion in the neck that had grown spontaneously over the course of a year (Fig. 1). The swelling had gradually progressed, and he had no previous history of head trauma, infection, or a genetic disorder. The patient was found to have a firm, non-tender, pulsating mass in the left side of the neck that measured 4 × 3 cm. Ultrasonography showed turbulent flow and dilatation of the involved vessel. Neck computed tomography showed partial opacification of the swelling and revealed a pseudoaneurysm arising from the left proximal occipital artery (Fig. 2). The decision was made to embolize the lesion via angiography (Fig. 3). The mass was treated successfully by endovascular coil embolization (Fig. 4). One year postoperatively, the swelling had improved and recurrence was not detected.

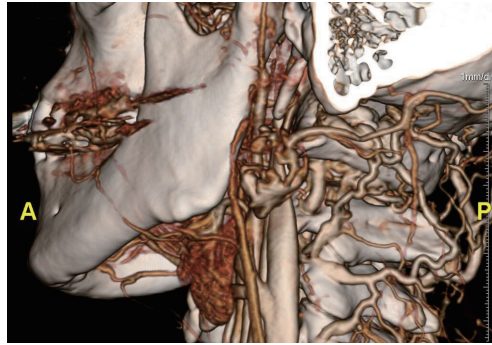
Most occipital artery pseudoaneurysms are consequences of trauma, or are secondary to



**Fig. 1.** Preoperative photograph showing a lesion on the left neck.



**Fig. 2.** Computed tomography scan (axial section) shows a left proximal occipital artery pseudoaneurysm.

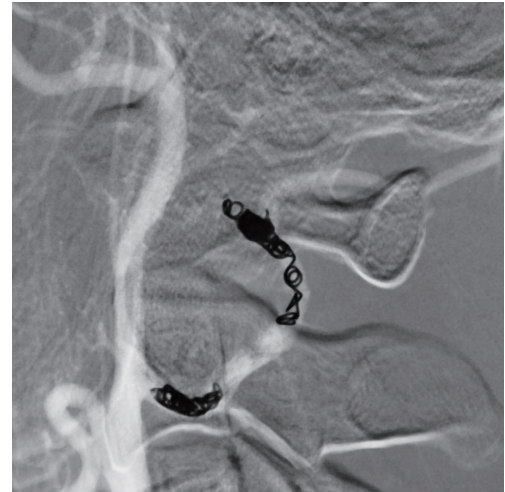

**Fig. 3.** Computed tomographic angiogram showing the pseudoaneurysm along the course of the proximal occipital artery. A, anterior; P, posterior.

infections or a genetic disorder [3]. There have been no previous reports of a spontaneous pseudoaneurysm of the occipital artery presenting as a neck mass. The diagnosis can be made based on a thorough history, the exclusion of other possibilities, and imaging studies. Currently, computed tomography angiography is regarded as the most definitive noninvasive diagnostic tool. The advantages of treatment include a reduced risk of hemorrhage, pain relief, and alleviation of cosmetic disfigurement. Treatment options include surgical excision, ligation of the feeding artery, trapping of the pseudoaneurysm, and endovascular arterial embolization and coil occlusion [3].

### ORCID

Tae Gon Kim <http://orcid.org/0000-0002-6738-4630>  
 Kyu-Jin Chung <http://orcid.org/0000-0001-6335-1818>  
 Jun Ho Lee <http://orcid.org/0000-0002-0062-6420>  
 Yong-Ha Kim <http://orcid.org/0000-0002-1804-9086>



**Fig. 4.** Angiogram showing the afferent feeding vessel and pseudoaneurysm treated with endovascular coil embolization.

### References

1. Nagpal N, Bhargava GS, Singh B. Occipital artery pseudoaneurysm: a rare scalp swelling. *Indian J Surg* 2013;75:275-6.
2. Patel M, Tchelepi H, Rice DH. Traumatic pseudoaneurysm of the occipital artery: case report and review of the literature. *Ear Nose Throat J* 2008;87:E7-12.
3. Rao VY, Hwang SW, Adesina AM, et al. Thrombosed traumatic aneurysm of the occipital artery: a case report and review of the literature. *J Med Case Rep* 2012;6:203.