



## Two-Blade Guillotine Technique for Nipple Graft Harvest

Allen Wei-Jiat Wong, Khong-Yik Chew, Bien-Keem Tan

*Department of Plastic, Reconstructive and Aesthetic Surgery, Singapore General Hospital, Singapore*

The nipple-sharing technique for nipple reconstruction offers excellent tissue matching. The method used for nipple graft harvesting determines the quality of the graft and hence, the success of nipple sharing. Here, we described a guillotine technique wherein the nipple is first transfixed with 2 straight needles to stabilise it. Two No. 11 blades are then inserted in the center and simultaneously swept outwards to amputate the distal portion of the nipple. This technique provides good control, resulting in a very evenly cut base. The recipient bed is de-epithelialized thinly, and the nipple graft is inset with interrupted 8-0 nylon sutures under magnification. Being a composite graft, it is protected with splint dressings for 6 weeks, and the dressing is regularly changed by the surgeon. The height of the nipple grafts ranges from 4 to 8 mm. This technique was performed in 9 patients with an average follow-up of 2.9 years (range, 1–4.5 years). Apposition between the nipple graft and its bed is crucial for the success of this technique. When correctly applied, we observed rapid revascularization of the graft.

**Correspondence:** Bien-Keem Tan  
Department of Plastic Reconstructive  
and Aesthetic Surgery, Singapore  
General Hospital, Outram Road,  
Singapore 169608, Singapore  
Tel: +65-6321-4686  
Fax: +65-6220-9340  
E-mail: bienkeem@gmail.com

**Keywords** Nipples / Breast neoplasm / Free flaps / Autografts

No potential conflict of interest relevant to this article was reported.

Received: 20 Oct 2016 • Revised: 13 Mar 2017 • Accepted: 28 Mar 2017

pISSN: 2234-6163 • eISSN: 2234-6171 • <https://doi.org/10.5999/aps.2017.44.5.449> • Arch Plast Surg 2017;44:449-452

### INTRODUCTION

The nipple-sharing technique for nipple reconstruction offers excellent tissue matching [1-4]. The indication of this method is the sufficiency of the contralateral nipple, and importantly, the patient must accept it since not many women are prepared to undergo scarring on their normal side [5-7]. Nipple grafts are susceptible to failure because of ischemia related to the volume of the grafted tissue [8,9]. Therefore, most surgeons recommend taking no more than 5 mm of the nipple when using the nipple-sharing method. In this paper, we describe the maximization of nipple graft take with a guillotine harvest method.

### IDEA

#### Technique

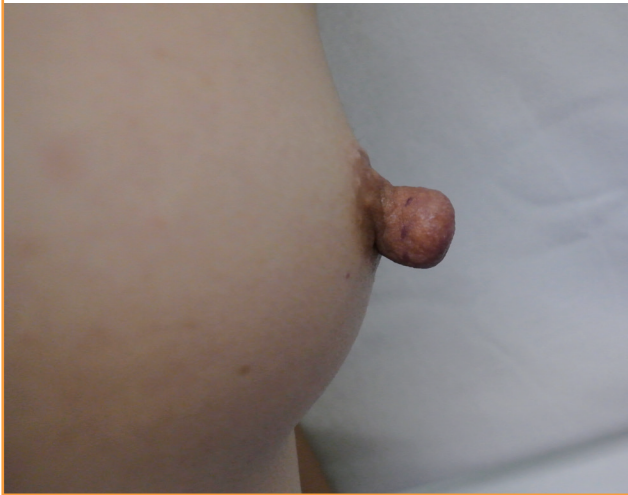A line is traced circumferentially, marking the level of amputa-

tion on the donor nipple. It is 5–7 mm from the nipple tip when the nipple is in a flaccid state (Fig. 1). Lignocaine with adrenaline is injected sparingly to control bleeding and to create tumescence. The main challenge with cutting the nipple is its flaccidity and tendency to slip, coupled with the toughness of the nipple tissue resisting the passage of the blade. The result is often a scalloped cut with an irregular base. To eliminate this problem, the nipple is transfixed with a pair of Sims straight needles and cut with a pair of No. 11 blades, sweeping simultaneously outwards from the center (Fig. 2). Thus, an even cut is achieved (Fig. 3). Low-wattage bipolar cautery is applied over the donor site, followed by a tie-over alginate dressing to prevent rebound bleeding. The donor site is left to heal by secondary intention.

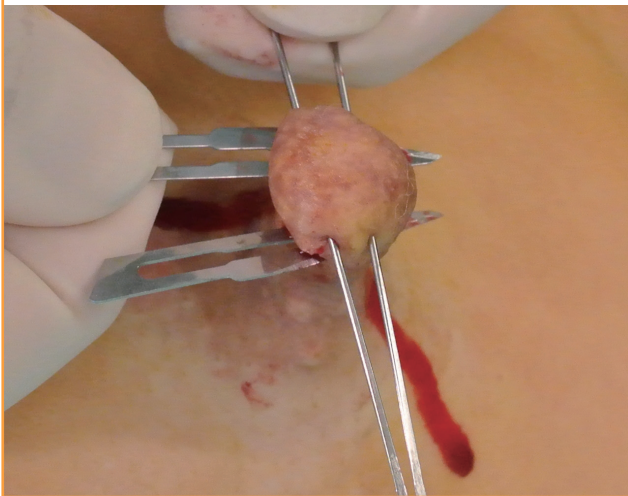
At the recipient site, which is either the skin paddle of the transverse rectus abdominis myocutaneous flap or latissimus dorsi flap, a circle with a diameter of 1–1.5 cm is drawn according to the dimensions of the graft. The skin is thinly scored with

**Fig. 1. Donor nipple markings**

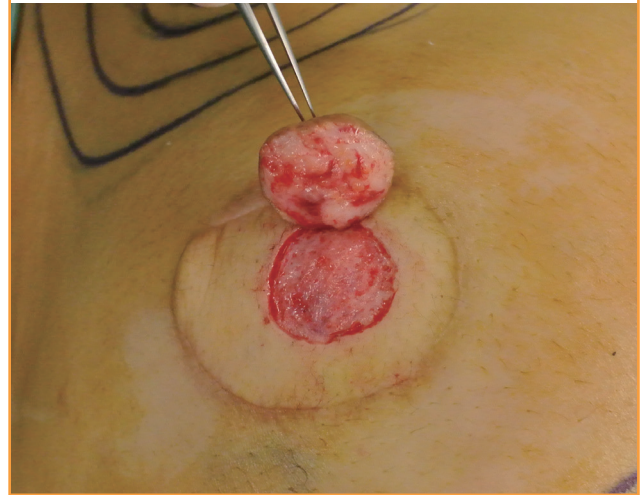
Markings are made circumferentially around the donor nipple.

**Fig. 2. Nipple guillotine technique**

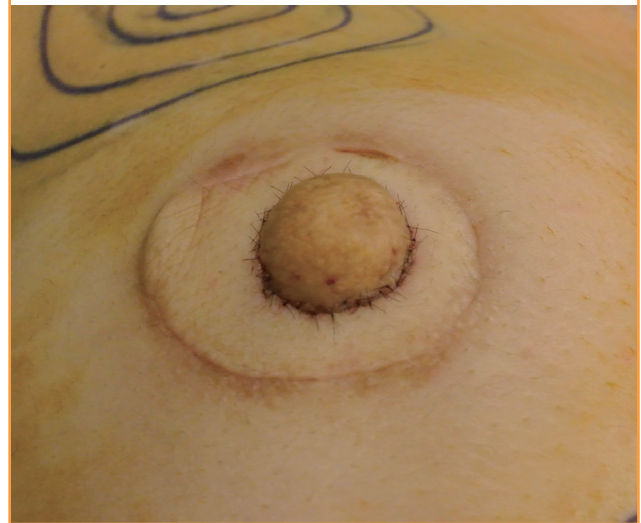
A straight Sims needle is used for transfixing the tip of the nipple, and 2 No. 11 blades are used for cutting outwards in tandem.

**Fig. 3. Nipple graft and the de-epithelialized recipient site**

Nipple graft and the de-epithelialized recipient site.

**Fig. 4. Anchoring the nipple graft**

The nipple graft is sutured in place with nylon 8-0 sutures.



a No. 15 blade and evenly de-epithelialized with a pair of Paget scissors to expose the subdermal plexus. Fat should not be exposed, as it is avascular. A well-prepared bed should have punctate bleeding. Local anesthesia is avoided at the recipient site, as it masks bleeding.

The nipple graft is then sutured to the recipient site with interrupted 8-0 nylon sutures under the operating microscope. Precise apposition of the skin edges is necessary to maximize dermal contact between the graft and its bed (Fig. 4). This step maximizes revascularization through the subdermal plexus. Stacked foam donut dressings (Allevyn, Smith & Nephew, United Kingdom) are used for protecting the nipple graft. Donut dressings are anchored with stitches to prevent displace-

ment. Then, 1% tetracycline ointment is applied over the graft and the suture line, and the entire construct is left sealed for 7 days.

The patient is prescribed oral antibiotics and counselled that the nipple will be discolored for 3 weeks before pinking up. After the first inspection on postoperative day 5, dressings are changed in an atraumatic manner every 3 days by the surgeon in charge. Sutures are left in place for 4–6 weeks. The areola is created with tattooing or skin grafting depending on the patient's preference.

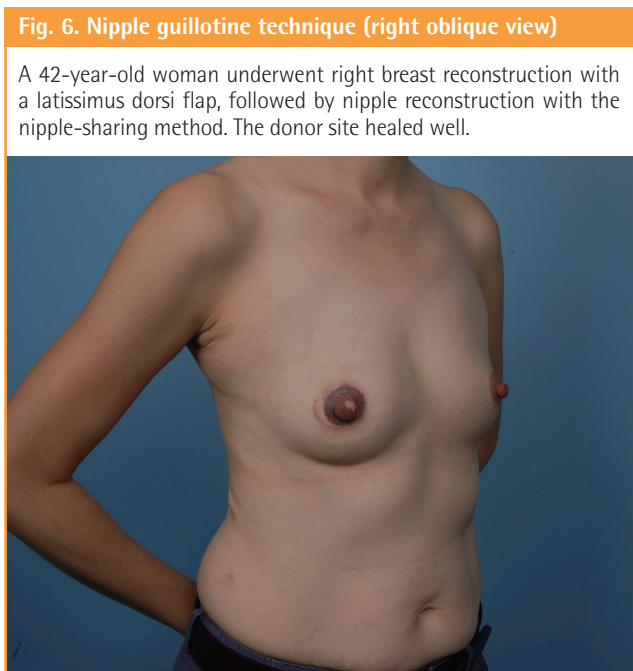
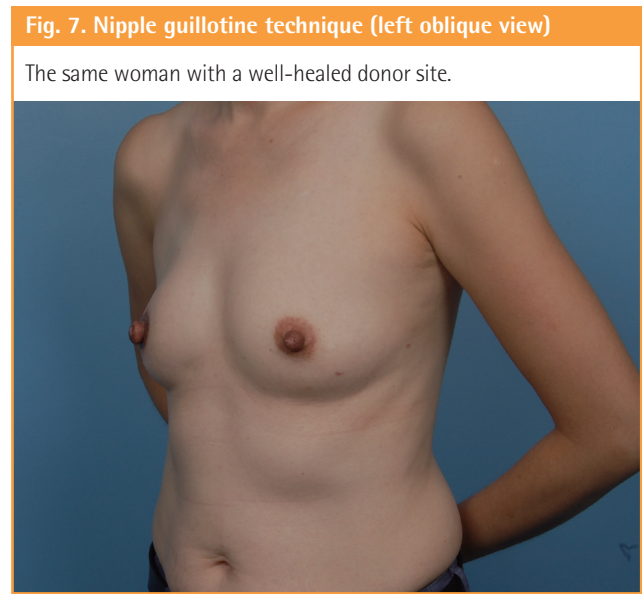
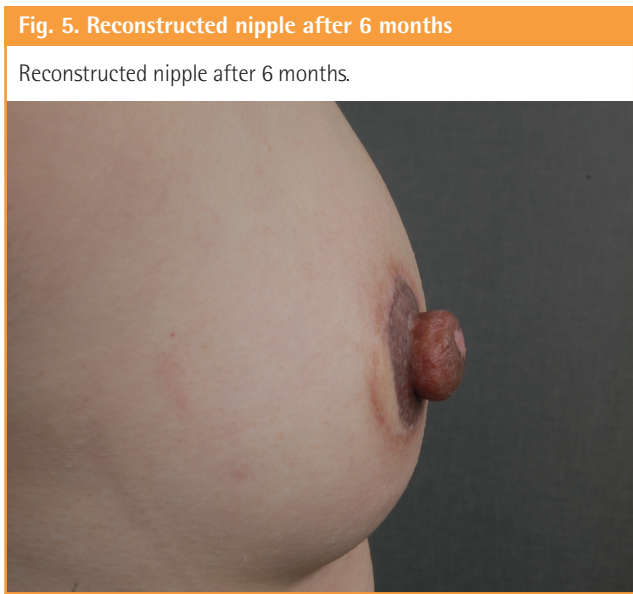## Results

This guillotine technique was performed on 9 patients, with an

**Table 1. Patient outcomes**

Patient	Age (yr)	Breast reconstruction	Graft size (mm)	Graft survival	Hyperbaric oxygen therapy	Follow-up duration (yr)
1	40	Pedicled TRAM	5	Yes	No	5
2	56	Pedicled TRAM	5	Yes	No	3.2
3	43	Pedicled TRAM	4	Yes	No	2
4	48	Pedicled TRAM	5	Yes	No	4.5
5	67	Free TRAM	5	Yes	No	3
6	69	Pedicled TRAM	5	No	No	1
7	59	Pedicled TRAM	4	Yes	No	4.1
8	60	Pedicled TRAM	4	Yes	No	1.3
9	47	Pedicled LD	8	Yes	Yes	2

TRAM, transverse rectus abdominis myocutaneous; LD, latissimus dorsi.



average follow-up of 2.9 years (range, 1–4.5 years) (Table 1). The average graft height ranged from 4 mm to 8 mm and was maintained throughout the follow-up period. Our patients wore Allevyn splints for 6 months. One failure occurred due to graft dislodgement during dressing change. The outcome of the technique is illustrated in Figs. 5–7.

**DISCUSSION**

In 1950, Kiskadden described a case in which the surgeon, while taking split-skin grafts for burn coverage, inadvertently picked up the surface of a nipple and areola in his grafts. This graft took on the burned arm, while the donor site regenerated a reasonable nipple and areola. Inspired by this, Adams [10] and Millard [11] performed the first nipple-sharing procedure for nipple reconstruction, using a No. 10 blade to harvest the dome of the donor nipple. Nipple graft harvesting has since been done in various ways. Spear used a nylon traction suture to improve



control on the nipple when cutting with a No. 11 blade [7]. Sakai and Taneda [3] harvested a rim of the nipple near its base and closed the denuded area by invaginating the nipple. The new nipple was reconstructed by spirally inseting the graft [3]. Other surgeons used a sagittally split nipple as a graft in cases where the nipple was flat [1,12].

Structurally, the nipple contains 15–20 lactiferous ducts, which are lined with luminal epithelial cells. Interspersed between these ducts is myoepithelial and stromal connective tissue, which is supported by a dense capillary network. With precise apposition, rapid revascularization can occur between the nipple base and the recipient site when their respective capillary networks link up. Plasmatic imbibition is the greatest at the base of the graft, and we believe that it progresses upward between the ducts by capillary action. As stromal vascular elements repopulate the graft, it becomes completely adherent to the bed. A meticulous microsurgical technique optimizes the conditions for the graft take because it allows healing from both the bed and the skin edges.

Detailed postoperative care was a key to the success of our two-blade guillotine technique. Initial dressing changes were performed avoiding any movement that might disrupt capillary inosculation. If the height of the graft exceeded 5 mm, hyperbaric oxygen therapy was instituted to increase local tissue oxygen tension. As for the donor site, the secondary healing involved minimal scarring, and we observed that ductal patency was maintained because the terminal openings of the ducts were not closed.

## PATIENT CONSENT

The patient provided written informed consent for the publication and the use of their images.

## REFERENCES

1. Zenn MR, Garofalo JA. Unilateral nipple reconstruction with nipple sharing: time for a second look. *Plast Reconstr Surg* 2009;123:1648-53.
2. Farhadi J, Maksvytyte GK, Schaefer DJ, et al. Reconstruction of the nipple-areola complex: an update. *J Plast Reconstr Aesthet Surg* 2006;59:40-53.
3. Sakai S, Taneda H. New nipple-sharing technique that preserves the anatomic structure of the donor nipple for breast-feeding. *Aesthetic Plast Surg* 2012;36:308-12.
4. Goh SC, Martin NA, Pandya AN, et al. Patient satisfaction following nipple-areolar complex reconstruction and tattooing. *J Plast Reconstr Aesthet Surg* 2011;64:360-3.
5. Jabor MA, Shayani P, Collins DR Jr, et al. Nipple-areola reconstruction: satisfaction and clinical determinants. *Plast Reconstr Surg* 2002;110:457-63.
6. Haslik W, Nedomansky J, Hacker S, et al. Objective and subjective evaluation of donor-site morbidity after nipple sharing for nipple areola reconstruction. *J Plast Reconstr Aesthet Surg* 2015;68:168-74.
7. Spear SL, Schaffner AD, Jespersen MR, et al. Donor-site morbidity and patient satisfaction using a composite nipple graft for unilateral nipple reconstruction in the radiated and nonradiated breast. *Plast Reconstr Surg* 2011;127:1437-46.
8. Edsander-Nord A, Wickman M, Hansson P. Threshold of tactile perception after nipple-sharing: a prospective study. *Scand J Plast Reconstr Surg Hand Surg* 2002;36:216-20.
9. Dent BL, Chao JW, Eden DJ, et al. Nipple resection and reconstruction after attempted nipple-sparing mastectomy. *Ann Plast Surg* 2017;78:28-34.
10. Adams WM. Free transplantation of the nipples and areolae. *Surgery* 1944;15:186-95.
11. Millard DR Jr. Nipple and areola reconstruction by split-skin graft from the normal side. *Plast Reconstr Surg* 1972;50:350-3.
12. Lee TJ, Noh HJ, Kim EK, et al. Reducing donor site morbidity when reconstructing the nipple using a composite nipple graft. *Arch Plast Surg* 2012;39:384-9.