Article published online: 2022-03-28

IMAGES

Synchronous reconstruction of both the upper and lower eyelids with a temporoparietal fascial flap

Ioannis G. Dalianoudis[1,2], Maria G. Kalofonou[1], Christos Farazi-Chongouki[2,3], Kyriaki Apostolidou[4], Pantelis Diamantopoulos[2,5], Nektaria Tsilimpokou[4], Dimitrios Filippou[2], Nikolaos Minogiannis[1], Panagiotis Skandalakis[2]

[1]*Department of Plastic and Reconstructive Surgery, Latsio Burn Center, General Hospital of Eleusis "Thriasio", Magoula;* [2]*Department of Anatomy and Surgical Anatomy, Medical School, National and Kapodistrian University of Athens, Athens;* [3]*Department of Surgery, General Hospital of Eleusis "Thriasio", Magoula;* [4]*Ophthalmic Surgeon, Private Practice, Athens;* [5]*Department of Plastic Surgery, Saint Savvas Anticancer Hospital, Athens, Greece*

Correspondence: Ioannis G. Dalianoudis
Department of Plastic and Reconstructive Surgery, Latsio Burn Center, G.H.E "Thriasio", Gennimata Avenue, Magoula 19018, Greece
Tel: +30-2117200331, Fax: +30-2105551526
E-mail: johndalas@gmail.com

This case was presented at the 11th National Congress of the Hellenic Society of Plastic Reconstructive and Aesthetic Surgery (HESPRAS) on November 5-7, 2015 in Thessaloniki, Greece.

Received: 21 Feb 2018 • Revised: 10 Apr 2018 • Accepted: 25 Apr 2018
pISSN: 2234-6163 • eISSN: 2234-6171
https://doi.org/10.5999/aps.2018.00178
Arch Plast Surg 2019;46:92-94

Copyright © 2019 The Korean Society of Plastic and Reconstructive Surgeons
This is an Open Access article distributed under the terms of the Creative Commons Attribution Non-Commercial License (http://creativecommons.org/licenses/by-nc/4.0/) which permits unrestricted non-commercial use, distribution, and reproduction in any medium, provided the original work is properly cited.

The simultaneous reconstruction of upper and lower eyelid defects, while preserving the seeing eye, presents a difficult task. Most cases involving such defects occur after burn injuries and tumor resections [1]. We present the case of a 55-year-old man, who provided consent and authorization for this report, with neglected basal cell carcinoma of both the upper and lower eyelids in the right eye and 10/10 visual acuity (Fig. 1). After oncological resection, defects were encountered in the total lower eyelid and half of the upper eyelid. A temporoparietal fascial flap (TPFF) was used to reconstruct both the upper and lower eyelids after an incision was made between the frontal and parietal branches of the temporal artery (Fig. 2). A composite graft from the nasal septum was sutured to the lower division of the TPFF and was used to reconstruct the posterior lamella, while the anterior lamella was reconstructed with a full-thickness skin graft (Fig. 3). During the 1-year follow-up period, no complications were encountered, except reduced upper eyelid motion, and the patient's visual acuity was similar before and after reconstructive surgery (Fig. 4). The patient was satisfied with the postoperative aesthetic results and

Fig. 1.
Planned oncological resection. A 55-year-old man with basal cell carcinoma of both the upper and lower eyelids that had been neglected for 8 years, with a functional eye and 10/10 visual acuity at presentation. The oncological resection involved the entire lower eyelid and half of the upper eyelid.

Fig. 2.
The temporoparietal fascial flap (TPFF). The TPFF after elevation and division into an upper and lower part following the course of the frontal and parietal branches. The two parts were used for the reconstruction of the upper and lower eyelids, respectively.

Images

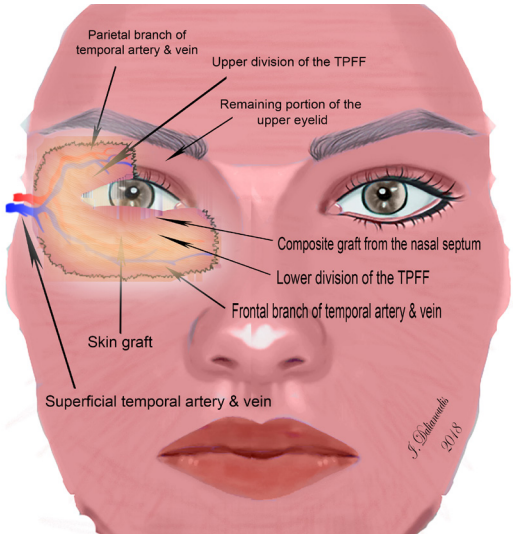

Fig. 3.
Schematic representation of the surgical procedure. In the sketch, we can see the setting of the temporoparietal fascial flap (TPFF) and the basic components of the procedure. The placement of the composite graft (cartilage+mucous) is highlighted. The course of the superficial temporal artery with its respective branches and the positioning of the two parts of the TPFF are simulated. Finally, the TPFF was covered with a full-thickness skin graft.

Fig. 4.
Presentation of the case 1 year after reconstruction. Postoperative results after 1 year of follow-up. The patient was satisfied with the postoperative aesthetic results. He experienced reduced upper eyelid motion that partially obscured his vision, but refused any further refinements.

refused any further refinements. Even though the TPFF is a well-known flap, as far as we know, such reconstructions are generally multistage [2]. To our knowledge, only one report has described functional reconstruction of both eyelids, the eyebrow, and the lacrimal drainage system in a single-stage procedure by pre-dividing a TPFF into three divisions [3]. The described method offers an efficient, effective alternative for eyelid reconstruction in a single-stage procedure.

Notes

Conflict of interest
No potential conflict of interest relevant to this article was reported.

Ethical approval
The study was performed in accordance with the principles of the Declaration of Helsinki. Written informed consent was obtained.

Patient consent
The patient provided written informed consent for the publication and the use of his images.

ORCID
Ioannis G. Dalianoudis
https://orcid.org/0000-0003-3658-205X
Maria G. Kalofonou
https://orcid.org/0000-0001-9461-8386
Christos Farazi-Chongouki
https://orcid.org/0000-0001-7646-167X
Kyriaki Apostolidou
https://orcid.org/0000-0002-4491-159X
Pantelis Diamantopoulos
https://orcid.org/0000-0003-2823-5496
Nektaria Tsilimpokou
https://orcid.org/0000-0002-4566-9133
Dimitrios Filippou
https://orcid.org/0000-0001-5410-3046
Nikolaos Minogiannis
https://orcid.org/0000-0002-7760-8044
Panagiotis Skandalakis
https://orcid.org/0000-0002-9325-5533

References

1. Bertrand B, Colson TR Jr, Baptista C, et al. Total upper and lower eyelid reconstruction: a rare procedure—a report of two cases. Plast Reconstr Surg 2015;136:855-9.

2. Mathijssen IM, van der Meulen JC. Guidelines for reconstruction of the eyelids and canthal regions. J Plast Reconstr Aesthet Surg 2010;63:1420-33.
3. Bozkurt M, Kulahci Y, Kapi E, et al. A new design for superficial temporal fascial flap for reconstruction of the eyebrow, upper and lower eyelids, and lacrimal system in one-stage procedure: medusa flap. Ann Plast Surg 2009;63:636-9.

Squamous cell carcinoma identified in a thick-walled epidermal cyst with a recurrent ulcer

Jae-Won Kim, Chan-Su Kang, Jin Ho Lee, Kyu Jin Chung

Department of Plastic and Reconstructive Surgery, Yeungnam University College of Medicine, Daegu, Korea

Correspondence: Kyu Jin Chung
Department of Plastic and Reconstructive Surgery, Yeungnam University College of Medicine, 170 Hyeonchung-ro, Nam-gu, Daegu 42415, Korea
Tel: +82-53-620-3484, Fax: +82-53-626-0705
E-mail: chungkj@ynu.ac.kr

This work was supported by Yeungnam University grants in 2017.

Received: 7 Sep 2018 • Revised: 10 Oct 2018 • Accepted: 18 Oct 2018
pISSN: 2234-6163 • eISSN: 2234-6171
https://doi.org/10.5999/aps.2018.01046
Arch Plast Surg 2019;46:94-95

Copyright © 2019 The Korean Society of Plastic and Reconstructive Surgeons
This is an Open Access article distributed under the terms of the Creative Commons Attribution Non-Commercial License (http://creativecommons.org/licenses/by-nc/4.0/) which permits unrestricted non-commercial use, distribution, and reproduction in any medium, provided the original work is properly cited.

Epidermal cysts are common skin tumors. In order to achieve cost-effectiveness, routine biopsy is not recommended in the setting of plastic surgery [1]. We report a case of squamous cell carcinoma (SCC) confirmed in a residual wound after resection of a cutaneous cyst. A 46-year-old male patient underwent local resection of a cystic lesion in the left nasal alar region 3 weeks before at a local medical center without biopsy. He developed tenderness, fever, and erythema over the wound, and visited our hospital (Fig. 1A). While the planned excision was performed, a 0.8 × 0.9-cm-thick white capsule was observed (Fig. 2). Therefore, a biopsy including skin tissue was performed. A SCC was then diagnosed (Fig. 3), and additional resection with a 5-mm safety margin was performed. During the 18-month follow-up period, no recurrence was observed (Fig. 1B). Owing to the rarity of SCC arising from epidermal cysts, the nature and mechanism of this phenomenon remains uncertain. Malignant change of an epidermal

Fig. 2.
A biopsy specimen. A 0.8 × 0.9-cm-thick white capsule was observed.

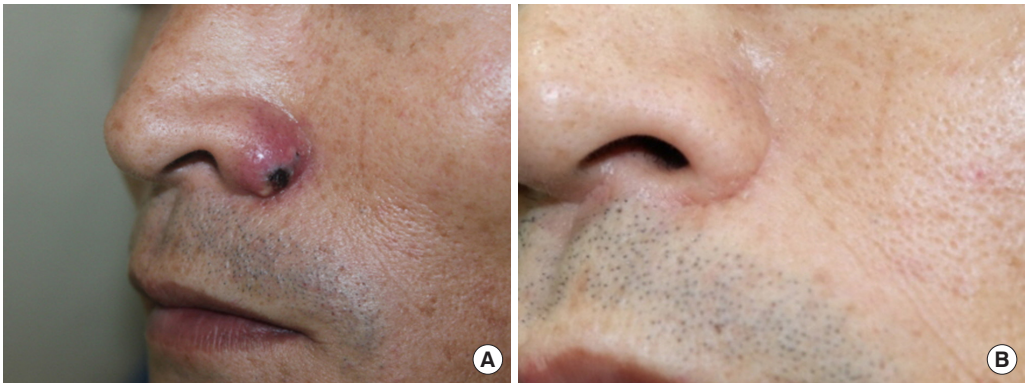

Fig. 1.
(A) The patient at his first visit to our hospital. He had developed tenderness, febrile sensation, and erythema on the wound in the left nasal alar region. (B) Six-month postoperative follow-up. The patient shows a well-healed state in the nasal alar region without recurrence.

Images