



Safety and efficacy of transcutaneous bone conduction implant surgery for hearing improvement in microtia patients with bilateral hearing impairment

Jeong Hyun Cheon¹, Hyung Chul Lee¹, Gi Jung Im², Jung Youl Park³, Chul Park³

Departments of ¹Plastic and Reconstructive Surgery, and ²Otolaryngology-Head and Neck Surgery, Korea University College of Medicine, Seoul; ³Seoul Center for Developmental Ear Anomalies, BIO Plastic Surgery Clinic, Seoul, Korea

Original Article

Background In microtia patients with bilateral hearing impairment, hearing improvement is crucial for language development and performance. External auditory canal reconstruction (EACR) has been performed to improve hearing, but often results in complications. We performed transcutaneous bone conduction implant (TBCI) surgery in these patients. This study aimed to evaluate the safety and efficacy of TBCI surgery.

Methods A retrospective review was performed of five patients who underwent auricular reconstruction and TBCI surgery and 12 patients who underwent EACR between March 2007 and August 2018. Hearing improvement was measured based on the air-bone gap values using pure-tone audiometry over a 6-week postoperative period. We reviewed other studies on hearing improvement using EACR and compared the findings with our results. The surgical techniques for TBCI were reviewed through case analyses.

Results Postoperative hearing outcomes showed a significant improvement, with a mean gain of 34.1 dB in the TBCI cohort and 14.1 dB in the EACR cohort. Both gains were statistically significant; however, the TBCI cohort showed much larger gains. Only three of the 12 patients who underwent EACR achieved hearing gains of more than 20 dB, which is consistent with previous studies. All patients who underwent TBCI surgery demonstrated hearing gains of more than 20 dB and experienced no device-related complications.

Conclusions TBCI is a safe and effective method of promoting hearing gains in microtia patients with bilateral hearing impairment. TBCI surgery provided better hearing outcomes than EACR and could be performed along with various auricular reconstruction techniques using virgin mastoid skin.

Keywords Congenital microtia / Ear canal / Hearing loss / Hearing aids / Bone conduction

Correspondence: Chul Park
Seoul Center for Development Ear Anomalies, BIO Plastic Surgery Clinic, 107 Dosan-daero, Gangnam-gu, Seoul 06035, Korea
Tel: +82-2-535-9000
Fax: +82-2-540-0966
E-mail: chulpark.md@gmail.com

Received: May 24, 2019 • Revised: August 19, 2019 • Accepted: September 19, 2019

pISSN: 2234-6163 • eISSN: 2234-6171 • <https://doi.org/10.5999/aps.2019.00661> • Arch Plast Surg 2019;46:525-534

INTRODUCTION

Microtia and congenital aural atresia are rare malformations of

the ear. However, since these two anomalies are associated with each other, they are frequently observed together. The incidence of microtia with aural atresia ranges from 0.83 to 17.4 cas-

es per 10,000 births [1]. The majority of these patients display unilateral microtia, and in such patients, hearing loss is compensated by the unaffected ear. However, for microtia patients with bilateral hearing impairment, hearing improvement is critical to brain development and language performance [2]. External auditory canal reconstruction (EACR) was first performed in 1883 on a patient with aural atresia in an attempt to improve hearing and restore the normal anatomical structure of the external auditory canal (EAC). Although many attempts have been made to improve the results of EACR, complications such as meatal stenosis, edema, reconstruction failure, and chronic discharge are still reported frequently [3]. Furthermore, when total auricular reconstruction is performed using EACR in microtia patients, the high risk for chronic seroma and infection is a major concern for the plastic surgeon, since these complications can result in reconstruction failure. The aesthetic results of EACR are another source of frustration for plastic surgeons.

Development of the bone conduction (BC) concept in hearing restoration resulted in a paradigm shift from the anatomical restoration of the EAC to the use of BC implants [4]. A percutaneous bone conduction implant (p-BAHA; Cochlear Americas, Centennial, CO, USA) was first invented in the late 1970s, and it demonstrated favorable hearing improvement with a shorter operating time than that of EACR [5]. However, skin penetration by the percutaneous device was shown to lead to complications, including infections and implant loss. A transcutaneous bone conduction implant (TBCI) (Bonebridge; MED-EL, Innsbruck, Austria) was recently introduced to address these drawbacks and was shown to be safe and to produce satisfactory results [6]. Although tremendous improvements have been made in the area of hearing-assistive devices and surgical procedures, there are few reports on multidisciplinary approaches to the treatment of microtia patients with aural atresia.

In this report, we reviewed cases of microtia patients with bilateral hearing impairment who underwent both microtia reconstruction and TBCI. The aim of this study was to evaluate the safety and efficacy of TBCI procedures in microtia patients

with bilateral hearing impairment.

METHODS

A retrospective chart review of medical records and photographic data was conducted for patients with microtia and bilateral hearing impairment who underwent microtia reconstruction and TBCI procedures at our clinic between March 2007 and August 2018. The demographic characteristics and medical histories of the patients who underwent auricular reconstruction surgery with TBCI are shown in Table 1. The patients with TBCI had either microtia or anotia with congenital aural atresia. Of the patients, three had bilateral and two had unilateral microtia. All of the patients had bilateral conductive hearing loss as evidenced by audiograms, had functioning cochlear as shown by evoked response audiometry, and had normal cochlear morphology with pneumatized mastoids as shown on computed tomography (CT) scans. All patients satisfied the conditions indicated for use of the TBCI device. Microtia reconstruction was performed before, after, or simultaneously with hearing improvement surgery, depending on the condition of the patient.

We also retrospectively reviewed 12 microtia patients who underwent EACR surgery to compare the functional results with those of the TBCI patients. Furthermore, we systematically reviewed other reported studies on hearing improvements resulting from EACR and compared them with our results. This study was approved by the Institutional Review Board of our institution (IRB No. 2019AN0008) and was performed in compliance with the Declaration of Helsinki. Informed consent was obtained from all patients.

Surgical techniques

Total auricular reconstruction was performed by a plastic surgeon (CP), and the TBCI procedure was performed by an otologic surgeon (GJI). Autogenous costal cartilage was used for framework construction. Two different coverage techniques were used for auricular reconstruction: the embedded and ele-

Table 1. Demographic data and medical history of patients

Patient	Age at surgery (yr)	Sex	Microtia	Implanted ear	Implant timing	No. of previous ear operations	Type of HL	Auricular reconstruction technique	Preoperative ABG (dB)	Postoperative ABG (dB)	Hearing gain
Case 1	13	F	B	L	Preauricular reconstruction	0	CHL	Temporoparietal	42.5	10	32.5
Case 2	17	M	B	L	Intra-auricular reconstruction	0	CHL	Embedded, elevation	62.5	35	27.5
Case 3	19	M	R	R	Intra-auricular reconstruction	1	CHL	Temporoparietal	56.3	22.5	33.8
Case 4	17	F	B	R	Postauricular reconstruction	1	CHL	Embedded, elevation	52.5	5	47.5
Case 5	40	F	L	L	Postauricular reconstruction	0	CHL	Temporoparietal	60	31.3	28.7

HL, hearing loss; ABG, air-bone gap; F, female; M, male; B, bilateral; R, right; L, left; CHL, conductive hearing loss.

vation technique and the temporoparietal fascia flap technique [7]. The timing of the TBCI implantation procedure varied by case. Prior to, during, or after the operation, the mastoid bone was approached along the postauricular incision, and a bone bridge implantation procedure was performed by an otologic surgeon. In all cases, the plastic surgeon advised on the incision design and performed the flap elevation.

Bonebridge device description

The Bonebridge implant is an active TBCI system consisting of both external and internal components [8]. The internal part of the active TBCI, which is composed of a magnet and a bone conduction-floating mass transducer (BC-FMT), is embedded beneath the skin [8]. The external audio processor (AP) contains microphones and is powered by a standard hearing aid battery. It is held in place on the patient's head with a magnet. The AP transmits processed sound and energy through an inductive link to the BC-FMT and releases-controlled vibrations to the skull. The device can be activated after wound healing is complete, and the active TBCI is considered magnetic resonance imaging-safe if the external AP is removed (Fig. 1) [8].

Evaluation of postoperative hearing results

The preoperative and postoperative data obtained using standard audiometric tests in patients who underwent EACR or TBCI surgery were collected retrospectively. Pure-tone air- and bone-conduction thresholds of 500, 1,000, and 2,000 Hz were used to calculate pure-tone averages (PTA). Air-bone gap (ABG) values were calculated from the same test results. Additionally, pure-tone air- and bone-conduction thresholds at 500, 1,000, 2,000, and 4,000 Hz were evaluated separately. The test-

ing took place in an audiometric sound-attenuated room using calibrated equipment and signals. The contralateral ear was acoustically blocked with an earplug or comparable plug. Data were collected up to 6 weeks postoperatively (representing the short-term follow-up period). Long-term results were analyzed if there were additional data available after a 3-month postoperative period. The mean short-term follow-up period was 3.8 ± 0.5 weeks, and the mean long-term follow-up period was 7.8 ± 1.2 months. The paired-samples t-test was used to evaluate differences between the preoperative and short-term postoperative mean audiometric threshold data. We also compared the audiometric results of patients who underwent TBCI surgery with the audiometric results of patients who underwent EACR at our hospital's otologic clinic.

Statistical analyses

Descriptive statistics were reported as mean (range) \pm standard deviation (SD) or as counts (percentages), as applicable. For continuous variables, independent groups were compared using the Student t-test, while paired comparisons were made using the paired t-test. A P-value of less than 0.05 was considered to indicate statistical significance. SPSS version 20 (IBM Corp., Armonk, NY, USA) was used for all statistical tests.

RESULTS

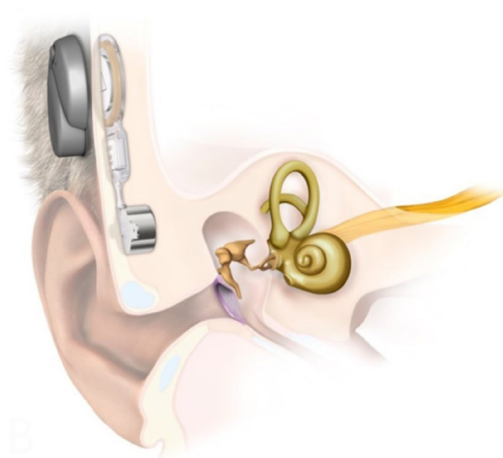
During the study period, we reviewed five patients, three male and two female, who underwent auricular reconstruction surgery and surgical placement of the TBCI system (Table 1). One of the five patients, who displayed unilateral anotia, had received EACR surgery at another clinic but failed to achieve hearing

Fig. 1. Schematic representation of Bonebridge

(A) The external Bonebridge audio processor and the internal magnet and bone conduction floating mass transducer. (B) An artistic rendering of Bonebridge implantation. Reprinted with permission from MED-EL Corp.



(A)



(B)

gain. The other patient with unilateral microtia or anotia had unilateral lobular type microtia. The remaining patients had bilateral microtia with the lobular type on one side and the conchal type on the other side. All of the patients displayed bilateral hearing impairment, and two of them wore air conduction (AC) hearing aids. Hearing loss was severe in all patients, and TBCI surgery was planned. The mean age (\pm SD) at implantation of the TBCI was 21.2 ± 4.8 years. The duration of follow-up ranged from 8 to 39 months, with a mean duration of 25.6 months. The right ear was the site of three TBCIs (60%). All operations were performed without any complications, such as device extrusions or infections.

We also retrospectively reviewed the cases of 12 microtia patients (seven male and five female) who underwent EACR surgery so that we could compare the functional results with those of the TBCI patients. All of the patients who underwent EACR surgery in our hospital did so for the treatment of cholesteatoma. The mean age (\pm SD) at the time of EACR surgery was 17.2 ± 7.3 years. The duration of follow-up ranged from 1 month to 48 months, with a mean duration of 13 months.

Infection is another issue in patients who undergo EACR surgery. We reviewed the cases of 11 patients who visited our center for microtia reconstruction after undergoing EACR surgery at another clinic. When a swab culture was first performed through the canal that had been created, various bacteria were isolated from the reconstructed canal. Table 2 shows the swab culture results. *Pseudomonas aeruginosa* and *Staphylococcus epidermidis* were the most common pathogens in patients who experienced discharge and delayed surgery. To eliminate the possibility of infection, when the swab culture results were positive, ear reconstructive surgery was delayed until the results of retesting were negative or until the otologic surgeon confirmed that the infection risk was reduced. The mean period from the first visit to surgery was 18.0 ± 5.3 months. Most cases were treated

empirically with antibiotics based on antibiotic sensitivity results and advice from the Department of Infectious Diseases. Patients were treated at outpatient clinics if possible, and the mean treatment period was 14 days for a single treatment. If discharge was observed from the reconstructed canal, a Silmazine packing dressing was applied. Although no cases displayed chronic infections in our study, preoperative swab culture results were positive in some cases, and multiple pediatric patients suffered from continuous discharge.

Audiometric results

Table 3 shows the PTA values for AC, the PTA values for BC, and the ABG values for the preoperative, short-term, and long-term follow-up periods for all patients who underwent TBCI or EACR surgery in this study. Both procedures were performed at a single institution. The mean AC improved from 69.8 dB preoperatively to 33.8 dB postoperatively in the TBCI cohort and from 72.3 dB preoperatively to 56.6 dB postoperatively in the EACR cohort. The AC values were significantly different between the cohorts. The mean BC improved from 15.0 dB preoperatively to 13.0 dB postoperatively in the TBCI cohort and

Table 2. Summary of bacteria identified in external auditory canal reconstruction patients

Bacteria	No. of patients
<i>Staphylococcus</i> spp.	
<i>S. aureus</i>	2
<i>S. capitis</i>	2
<i>S. caprae</i>	1
<i>S. epidermidis</i>	4
Coagulase-negative	2
<i>Corynebacterium</i> spp.	2
<i>Pseudomonas</i>	4
<i>Bacillus</i> species	1
<i>Enterobacter</i>	1

Table 3. Paired comparisons of changes between preoperative and short-term follow up results

	No.	Preoperative	Short-term	P-value	No.	Long-term
Pure-tone average (air conduction, dB)						
TBCI	5	69.8 \pm 4.5	33.8 \pm 4.7	<0.01	2	41.3 \pm 23.0
EACR	12	72.3 \pm 3.0	56.6 \pm 3.9	<0.01	10	60.9 \pm 6.8
Pure-tone average (bone conduction, dB)						
TBCI	5	15.0 \pm 2.3	13.0 \pm 2.4	0.37	2	13.8 \pm 5.3
EACR	12	12.1 \pm 1.2	11.0 \pm 1.0	0.98	10	15.0 \pm 6.5
Air-bone gap (dB)						
TBCI	5	54.8 \pm 3.5	20.8 \pm 5.8	<0.01	2	27.5 \pm 17.7
EACR	12	60.2 \pm 2.6	45.9 \pm 7.8	<0.01	10	45.9 \pm 7.8

Values are presented as mean \pm SD. Three patients were not followed-up long-term in each cohort, hence, no data was available and their data were not included in the long-term follow-up analysis.

TBCI, transcutaneous bone conduction implant; EACR, ear auditory canal reconstruction.

from 12.1 dB preoperatively to 11.0 dB postoperatively in the EACR cohort. No statistically significant differences were found between the BC values of the two groups. The mean ABG improved from 54.8 dB preoperatively to 20.8 dB postoperatively in the TBCI cohort and from 60.2 dB preoperatively to 45.9 dB postoperatively in the EACR cohort. In this analysis, “postoperative” refers to the short-term follow-up period only. Some hearing loss was demonstrated in the long-term follow-up cohort.

The PTA values for the AC threshold levels were assessed at 500, 1,000, 2,000, and 4,000 Hz. In the preoperative audiologic data obtained from the TBCI cohort, the pure-tone AC thresholds at 500, 1,000, 2,000, and 4,000 Hz were 75.0, 71.0, 62.0, and 65.0, respectively. The postoperative audiologic pure-tone BC thresholds at 500, 1,000, 2,000, and 4,000 Hz were 38.0, 32.0, 33.0, and 30.0, respectively. In the preoperative audiologic data obtained from the EACR cohort, the pure-tone AC thresholds at 500, 1,000, 2,000, and 4,000 Hz were 78.3, 73.5, 63.3, and 63.3, respectively. The postoperative audiologic pure-tone

BC thresholds at 500, 1,000, 2,000, and 4,000 Hz were 59.6, 55.4, 58.8, and 60.0, respectively. The AC values are presented in Table 4.

Table 5 shows the number of ears with hearing gains of greater than 20 dB reported in each study reviewed, along with the number of EACRs conducted in each study by either approach [9-17]. Other studies also displayed differences in results, ranging from 10% to 95%, depending on the severity of the atresia or the approach used. In our study, only three of 12 EACR patients achieved hearing gains of greater than 20 dB, a result that was within the range of those found in other studies. In contrast, all five patients who underwent TBCI surgery achieved hearing gains of greater than 20 dB (Table 1).

Clinical application

Case 1: Preauricular reconstruction

A 13-year-old girl presented with bilateral microtia. The right ear exhibited the lobular type of the condition, while the left ear

Table 4. Mean preoperative and short-term postoperative air conduction hearing threshold at each frequency for the two groups

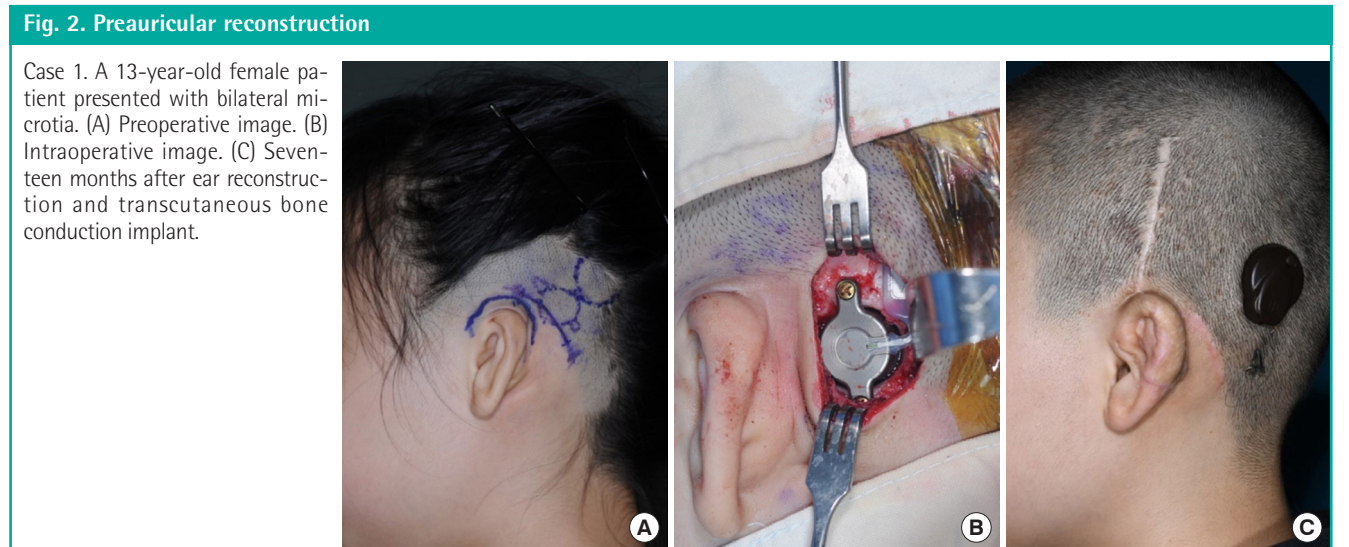
	No.	Frequency (Hz)			
		500	1,000	2,000	4,000
TBCI (dB)					
Preoperative AC	5	75.0 ± 3.2	71.0 ± 5.3	62.0 ± 4.6	65.0 ± 5.9
Postoperative AC	5	38.0 ± 4.6	32.0 ± 4.1	33.0 ± 7.0	30.0 ± 4.5
EACR (dB)					
Preoperative AC	12	78.3 ± 3.3	73.5 ± 3.0	63.3 ± 3.6	63.3 ± 1.8
Postoperative AC	12	59.6 ± 4.4	55.4 ± 4.8	55.8 ± 2.9	60.0 ± 6.1

Values are presented as mean ± SD.
TBCI, transcutaneous bone conduction implant; AC, air conduction; EACR, external auditory canal reconstruction.

Table 5. Ears with hearing gain >20 dB in the reviewed articles

Author	Ears with hearing gain > 20 dB/no.
Bauer et al. [9]	6/20
Murphy et al. [10]	15/19
Chang et al. [11]	73/100
De la Cruz and Teufert [12]	30/302
Lambert [13]	13/16
Lambert [13]	31/59
El-Hoshy et al. [14]	26/40
Nishizaki et al. [15]	12/38
Schuknecht [16]	30/56
Bouhabel et al. [17]	14/20

no., total patient number.



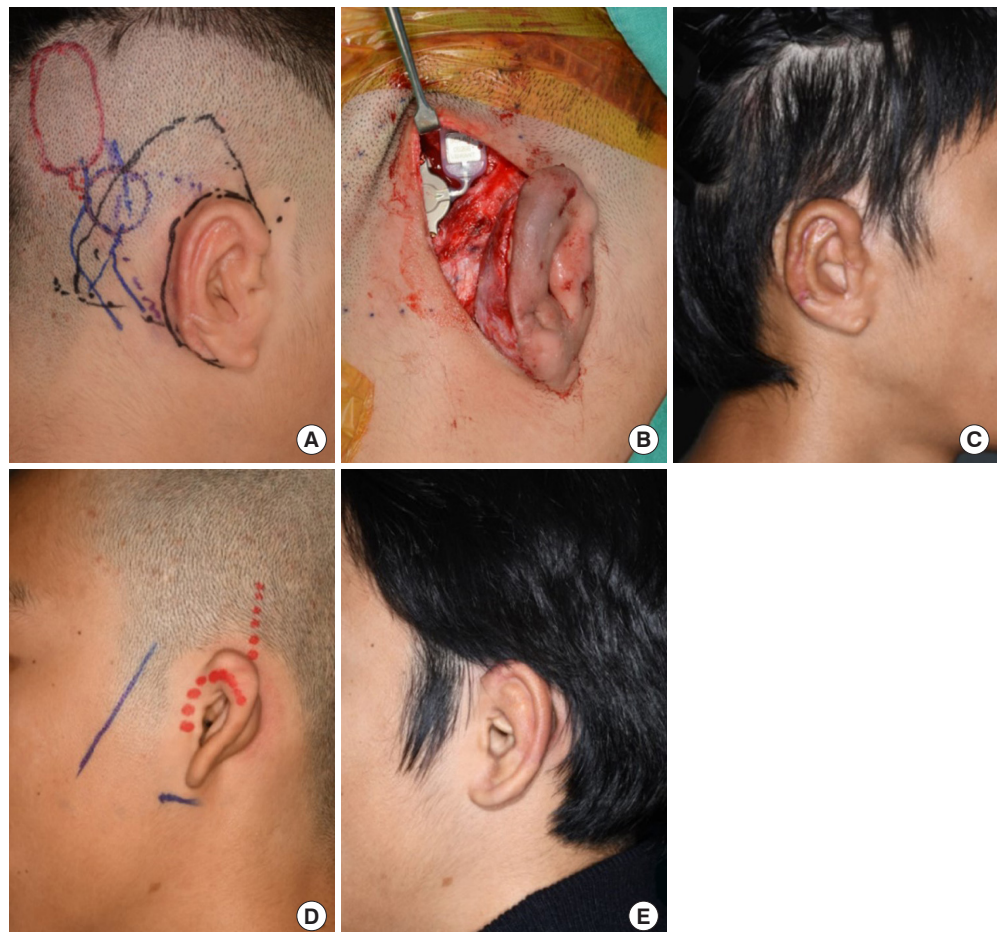exhibited the conchal type. Before implantation, the PTA of the AC values was 52.5 dB on the left side and 61.3 dB on the right side. The PTA of the BC values was 10 dB on the left side and 7.5 dB on the right side. The ABG values on the left and right sides were 42.5 dB and 53.8 dB, respectively. This patient was the first TBCI surgical case in this study. She underwent a TBCI procedure on the left side conducted by an otologic surgeon prior to auricular reconstruction surgery (Fig. 2B). A skin incision line was recommended to avoid compromising the later use of the vascularized temporoparietal flap for total auricular reconstruction (Fig. 2A). After implantation, the TBCI-aided air threshold of this patient was 20 dB, the bone threshold was 10 dB, and the ABG was 10 dB. The hearing gain on the left side was 43.8 dB. One year and 4 months later, the patient underwent total auricular reconstruction using the ipsilateral temporoparietal fascial flap technique. The reconstruction was successful, and the view obtained at a 1.5-year follow-up appointment showed promising results (Fig. 2C). The patient underwent right auricular reconstruction using the embedded and elevation technique 2 years after implantation.

Case 2: Intra-auricular reconstruction (elevation of embedded framework)

A 17-year-old boy presented with bilateral microtia. The right ear exhibited the lobular type of the condition, while the left ear exhibited the conchal type. Before implantation, the PTA of the AC values was 63.8 dB on the left side and 71.3 dB on the right side. The PTA of the BC values was 10 dB on the left side and 6.3 dB on the right side. The ABG values were 53.8 dB and 65 dB on the left and right sides, respectively. The patient wore AC hearing aids, and the aided air threshold of this patient was 40 dB. We planned to reconstruct both ears using the embedded and elevation technique. The TBCI procedure was performed during the elevation procedure of the embedded framework (the second stage of total auricular reconstruction) of the right ear (Fig. 3A and B). The skin incision line for ear elevation was made on the border of the helix. The skin of the mastoid and scalp was widely undermined. A fan-shaped mastoid fascia flap was elevated to cover the posterior surface of the elevated framework. The TBCI procedure was performed by an otologic surgeon (Fig. 3B). After 6 months, the contralateral ear was recon-

Fig. 3. Intra-auricular reconstruction (elevation of embedded framework)

Case 2. A 17-year-old male patient presented with bilateral microtia. (A) Design of the incisional line and implantation site. (B) Intraoperative image. (C) Seventeen months after ear reconstruction and transcutaneous bone conduction implant. (D) Preoperative lateral view before ear reconstruction surgery of the opposite side. (E) Lateral view of the opposite ear after ear reconstruction surgery.



structed using the embedded and elevation technique (Fig. 3D). Follow-up views of both reconstructed ears taken 1 year and 4 months later showed promising results (Fig. 3C and E). The TBCI-aided air threshold of this patient was 43.8 dB, the bone threshold was 8.8 dB, and the ABG was 35 dB. The ABG hearing gain was 30 dB on the right side. The results after TBCI were better than those displayed previously when AC hearing aids had been worn.

Case 3: Intra-auricular reconstruction (temporoparietal fascia flap technique)

A 19-year-old male patient presented with right anotia. He had a history of EACR surgery of the right ear at another hospital 3 years previously (Fig. 4A and B). The left ear displayed hearing impairment, even though the ear had a normal external appearance. Before TBCI surgery, the PTA of the AC values was 73.5 dB on the left side and 73.5 dB on the right side. The PTA of the BC values was 21.3 dB on the left side and 17.5 dB on the right side. The ABG values were 52.2 dB and 56 dB for the left and

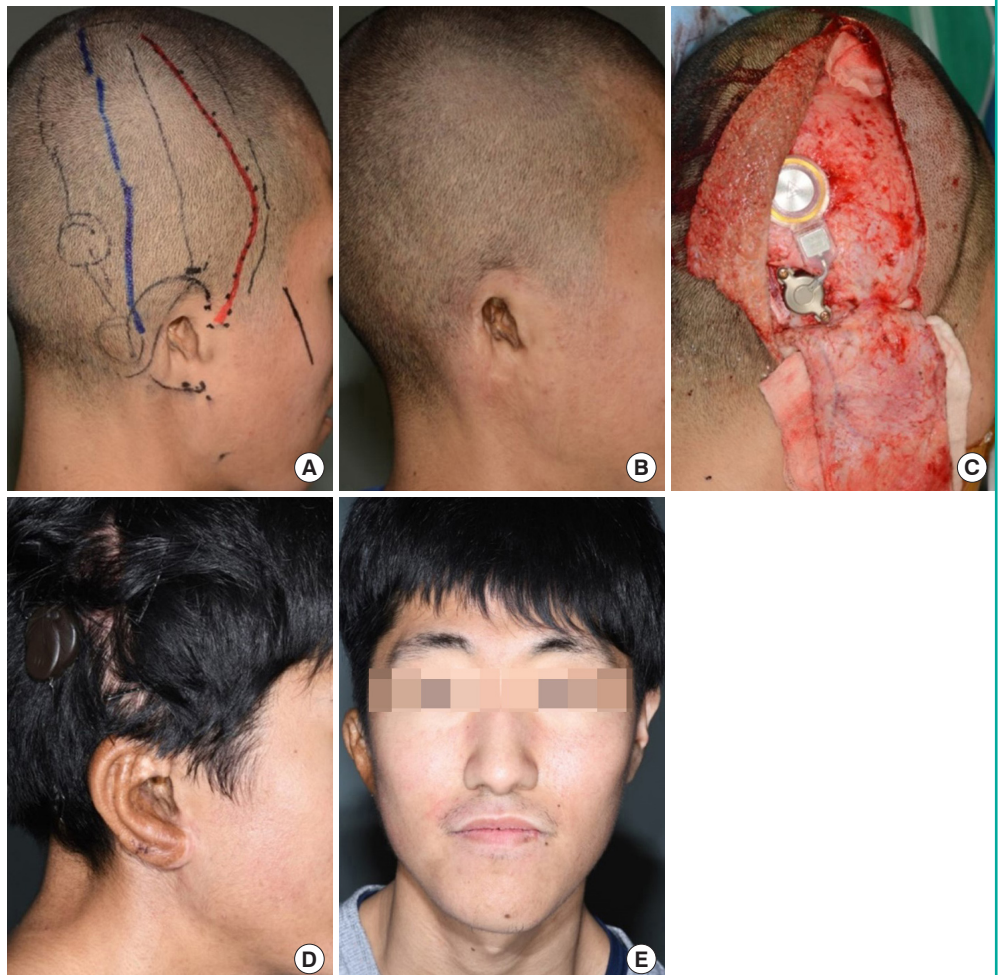right sides, respectively. Despite undergoing EACR surgery, the patient needed a complementary AC hearing aid. The aided air threshold of this patient was 51.3 dB.

Total auricular reconstruction using a temporoparietal flap was performed due to remnant scar tissue around the meatus (Fig. 4C). TBCI surgery was performed simultaneously with auricular reconstruction surgery, and the implant was inserted at the position of the elevated temporoparietal flap (Fig. 4C). Since the external opening of the reconstructed canal formed by the EACR was low-set, symmetry of the ears could not be achieved in the anteroposterior view (Fig. 4E). Moreover, a large newly-formed meatus detracted from the overall cosmetic outcome of the outer auricular reconstruction (Fig. 4D).

The TBCI-aided air threshold of this patient was 40 dB, the bone threshold was 22.5 dB, and the ABG was 17.5 dB. The ABG hearing gain was 38.5 dB on the right side. The results after TBCI were better than those displayed previously when the AC hearing aid had been worn.

Fig. 4. Intra-auricular reconstruction (temporoparietal fascia flap technique)

Case 3. A 19-year-old male patient presented with right anotia. (A) Design of the incisional line and implantation site. (B) Preoperative lateral view before implantation. (C) Intraoperative image. (D) Postoperative lateral view 14 months after ear reconstruction and transcutaneous bone conduction implant. (E) Frontal view after bilateral ear reconstruction surgery.



DISCUSSION

The surgical correction of atresia has been widely accepted since Kiesselbach performed the first reported operation to correct atresia in 1883 [18]. Techniques for EACR have improved considerably, but surgical correction of congenital aural atresia is still one of the most difficult and challenging procedures performed on the ear [12]. The lack of landmarks, altered anatomy of the facial nerve and middle ear, limited space for middle auricular reconstruction, and slow healing process make it more difficult to achieve the primary goal of surgery, which is the maintenance of a patent, reconstructed EAC that is free of infection [19]. Although surgical correction of atresia can produce a new EAC of sufficient width, it does not guarantee sufficient hearing improvement. Therefore, although it can improve hearing in some children, it is not always sufficient to achieve a satisfactory hearing level. Eight of Bauer's 10 patients and 15 of Murphy's 19 patients failed to achieve normal hearing and required the continued use of external hearing assistance devices, the most common complication of surgical management [9,10]. The majority of the authors considered a successful hearing result of surgery to be an improvement of 20–30 dB [16]. Using this definition, the percentage of cases with successful outcomes reported in the literature varied from 12% to 71% [20]. In this study, we reviewed the surgical and hearing results of 12 atretic ears that were operated on between 2006 and 2018 at the otologic clinic of our institution. Short-term follow-up showed that successful outcomes were achieved in 33% of the cases. Unfortunately, many papers have indicated that the results of EACR tended to be worse when observed in long-term follow-up. This finding matched our results (Table 3). Lambert [13] found that 70% of their cases displayed hearing levels of 30 dB or better in the early postoperative period, which diminished to about 50% by the time at which longer-term follow-up was conducted. El-Hoshy et al. [14] reported that 75% of their patients achieved successful hearing results by the end of the first postoperative year, but this result decreased to 65% by the end of the second year. In contrast, successful outcomes for TBCI were reported in 100% of the patients in short-term follow-up in this study; however, the long-term follow-up data have not yet been reported.

The most common complications of atresia surgery are canal restenosis, tympanic membrane lateralization, and chronic infection [21]. Nishizaki et al. [15] reported that stenosis of the newly-created auditory canal occurred in 29.3% of cases, and they attributed the cause to scar formation in the newly-formed external canal. El-Hoshy et al. [14] reported that the incidence of canal restenosis was 17.5%. Chronic infection of the newly-constructed EAC often occurs. El-Hoshy et al. [14] reported

that 17.5% of patients presented with this problem. Furthermore, since the position of the newly-formed canal depends on the bone and surrounding structures as shown on CT imagery, it is often asymmetrical with the unaffected opposite side. Moreover, the size of the canal can also be drilled as large as 1.3 times the normal size [18]. For these reasons, surgical correction of atresia makes it difficult to reconstruct the ear of a microtia patient and limits the choice of auricular reconstruction options.

Lichun et al. [22] reported a case where hearing was not improved after EACR and a case where the auricular reconstruction was not performed properly due to the construction of the canal in EACR. That study concluded that the incidence of complications after EACR was very high, that the level of hearing restoration was not sufficient, and that further investigations were needed to ensure better results. Chang et al. [11] proposed that, especially for severe cases of microtia and revision, BC devices were more stable and led to more reliable results. In the case of patients who underwent EACR and middle ear surgery first, a scar developed at the site of the incision, which was unavoidable and affected the skin flap needed for later auricular reconstruction [23].

When EACR was previously performed by an otologic surgeon, it resulted in asymmetrical auricular canals and inconsistent locations and sizes, resulting in scars in the surrounding tissue. In such cases, it is difficult to prepare a skin flap that is sufficiently large to cover the cartilage framework [3]. Therefore, we considered the temporoparietal fascial flap to be a better option, but this produces increased edema and inferior aesthetic results compared to the embedded and elevation technique. Additionally, in most cases where the temporoparietal fascial flap procedure was combined with EACR, mild edema of the reconstructed auricle was present for 3 to 4 weeks because of the longer operating time (5–6 hours) of the combined procedures [3].

In this report, we reviewed the combination of TBCI and auricular reconstruction techniques in several circumstances for patients with microtia/atresia. Depending on the circumstances, TBCI surgery was performed either with auricular reconstruction or separately (either before or after) from auricular reconstruction. The operation may be performed in various ways; therefore, to achieve the best results, it is important to select the best method and timing based on the individual patient's status. If the thickness and consistency of the bones are sufficient and the position of the sigmoid sinus and the dura mater are taken into consideration, the implant can be relatively freely placed in the optimal location within the mastoid bone [17]. These factors have contributed to the excellent aesthetic results obtained through auricular reconstruction. The absence of a meatus did

not affect the final aesthetic results, since the meatus is not visible in the lateral view in the case of normal anatomy. The Bonebridge is currently approved only for patients 18 years of age or older. However, Hassepas et al. [24] reported a straightforward surgical procedure and satisfactory functional gain after TBCI surgery in an adolescent patient ≥ 12 years old. Baumgartner et al. [6] also demonstrated the safety and efficacy of the Bonebridge implant in a 5-year-old child. The minimum age for which the Bonebridge is approved is expected to be lowered in the near future.

Recently, a new device, the Adhear (MED-EL), as well as the BAHA Softband (Cochlear Americas), which does not require any surgery prior to use, was introduced. The Adhear sticks to the skin just behind the ear. Although its efficacy has not yet been demonstrated, it may be a good alternative to assist with language development at an early age. However, Chang et al. [21] found that canal restenosis, which is the most common complication of atresia surgery, was correlated with the age of the patient. The younger the age at the time of the operation, the more likely the occurrence of postoperative meatal stenosis. Considering the complications and alternatives to these procedures, the hearing gain did not appear to justify performance of EACR at an early age. To date, the Jahrsdoerfer CT grading system is still widely used to determine candidates for EACR [25]. Patients with a Jahrsdoerfer score of 6 or higher are considered candidates for EACR [25]. However, a limitation of this system is that it only considers anatomical structures, and actual hearing outcomes are unpredictable. Therefore, we believe that the use of TBCI should be widened.

Currently, TBCI is used to treat conductive or mixed hearing loss. However, the scope of its application is expected to expand as various new products are developed and used. The most critical factor that limits the usage of TBCI is size. Since the implant is not compact, it is essential to check whether there is sufficient space for the implant through physical examination and CT scanning. Additionally, the use of TBCI should be limited in cases of retrocochlear and central auditory disorders, active middle ear infections, chronic or non-revisable vestibular or balance disorders, or abnormally progressive hearing loss.

There were several limitations of this study. First, the retrospective collection of data was solely dependent on the accuracy and completeness of the medical records from which the data were obtained. Other limitations included the lack of a comparison cohort, the lack of standardized surgical techniques, and differences in surgical timing. The assessment of patients and the surgical technique used were determined based on the judgment of the senior surgeon. However, despite these limitations, the data from this study will still provide additional information

for future research. Another limitation was the small sample size; thus, further studies with larger cohorts are required. Because we have only used TBCI for the management of microtia patients with bilateral hearing impairment since 2014, this study was limited by a median follow-up period of only 35 months. Since the device was first introduced in Europe in 2012, hearing results and complications reported in the literature were obtained in the early postoperative period. Longer-term follow-up studies are required to confirm these results.

Hearing restoration surgery using EACR may result in infections, poor aesthetic outcomes, and limited functional outcomes. Furthermore, in the patient group that underwent EACR, the surgical techniques for total ear reconstruction were limited, and many of these patients exhibited poor postoperative aesthetic results. In our study, the TBCI technique was shown to be safe and effective for hearing improvement in microtia patients with bilateral hearing impairment. Compared to EACR, when the TBCI technique was used in microtia patients with bilateral hearing impairment, it allowed for better aesthetic auricular reconstruction using virgin mastoid skin.

NOTES

Conflict of interest

No potential conflict of interest relevant to this article was reported.

Ethical approval

The study was approved by the Institutional Review Board of Korea University Anam Hospital (IRB No. 2019AN0008) and performed in accordance with the principles of the Declaration of Helsinki. Written informed consents were obtained.

Patient consent

The patients provided written informed consent for the publication and the use of their images.

Author contribution

Study concept and design: Park C, Im GJ. Data analysis and interpretation, drafting of the manuscript: Cheon JH, Park JY. Critical revision of the manuscript for important intellectual content: Lee HC. Technical, surgical support: Cheon JH, Park JY.

ORCID

Jeong Hyun Cheon <https://orcid.org/0000-0003-3979-7240>

Hyung Chul Lee <https://orcid.org/0000-0003-2482-8112>

Gi Jung Im <https://orcid.org/0000-0002-9457-4253>

Jung Youl Park <https://orcid.org/0000-0002-0157-0203>

Chul Park <https://orcid.org/0000-0002-3154-2289>

REFERENCES

- Klockars T, Rautio J. Embryology and epidemiology of microtia. *Facial Plast Surg* 2009;25:145-8.
- Genc S, Kahraman E, Ozel HE, et al. Microtia and congenital aural atresia. *J Craniofac Surg* 2012;23:1733-5.
- Cho BC, Lee SH. Surgical results of two-stage reconstruction of the auricle in congenital microtia using an autogenous costal cartilage alone or combined with canaloplasty. *Plast Reconstr Surg* 2006;117:936-47.
- Declau F, Cremers C, Van de Heyning P. Diagnosis and management strategies in congenital atresia of the external auditory canal. Study Group on Otological Malformations and Hearing Impairment. *Br J Audiol* 1999;33:313-27.
- Nadaraja GS, Gurgel RK, Kim J, et al. Hearing outcomes of atresia surgery versus osseointegrated bone conduction device in patients with congenital aural atresia: a systematic review. *Otol Neurotol* 2013;34:1394-9.
- Baumgartner WD, Hamzavi JS, Boheim K, et al. A new transcutaneous bone conduction hearing implant: short-term safety and efficacy in children. *Otol Neurotol* 2016;37:713-20.
- Park JY, Park C. Microtia reconstruction in hemifacial microsomia patients: three framework coverage techniques. *Plast Reconstr Surg* 2018;142:1558-70.
- Sprinzel G, Lenarz T, Ernst A, et al. First European multicenter results with a new transcutaneous bone conduction hearing implant system: short-term safety and efficacy. *Otol Neurotol* 2013;34:1076-83.
- Bauer GP, Wiet RJ, Zappia JJ. Congenital aural atresia. *Laryngoscope* 1994;104:1219-24.
- Murphy TP, Burstein F, Cohen S. Management of congenital atresia of the external auditory canal. *Otolaryngol Head Neck Surg* 1997;116(6 Pt 1):580-4.
- Chang SO, Choi BY, Hur DG. Analysis of the long-term hearing results after the surgical repair of aural atresia. *Laryngoscope* 2006;116:1835-41.
- De la Cruz A, Teufert KB. Congenital aural atresia surgery: long-term results. *Otolaryngol Head Neck Surg* 2003;129:121-7.
- Lambert PR. Congenital aural atresia: stability of surgical results. *Laryngoscope* 1998;108:1801-5.
- El-Hoshy Z, Abdel-Aziz M, Shabana M. Congenital aural atresia: transmastoid approach; an old technique with good results. *Int J Pediatr Otorhinolaryngol* 2008;72:1047-52.
- Nishizaki K, Masuda Y, Karita K. Surgical management and its post-operative complications in congenital aural atresia. *Acta Otolaryngol Suppl* 1999;540:42-4.
- Schuknecht HF. Congenital aural atresia. *Laryngoscope* 1989;99:908-17.
- Bouhabel S, Arcand P, Saliba I. Congenital aural atresia: bone-anchored hearing aid vs. external auditory canal reconstruction. *Int J Pediatr Otorhinolaryngol* 2012;76:272-7.
- Jahrsdoerfer RA. Congenital atresia of the ear. *Laryngoscope* 1978;88(9 Pt 3 Suppl 13):1-48.
- House HP. Management of congenital ear canal atresia. *Laryngoscope* 1953;63:916-46.
- Trigg DJ, Applebaum EL. Indications for the surgical repair of unilateral aural atresia in children. *Am J Otol* 1998;19:679-84.
- Lichun Z, Ying C, Tianyu Z. Three-stage surgery of combining auricle reconstruction, meatoplasty and tympanoplasty for patients with congenital microtia-atresia. *Zhonghua Er Bi Yan Hou Tou Jing Wai Ke Za Zhi* 2015;50:197-202.
- Chang SO, Jeon SJ, Jeong HS, et al. Prevention of postoperative meatal stenosis with anteriorly and inferiorly based periosteal flaps in congenital aural atresia surgery. *Otol Neurotol* 2002;23:25-8.
- Zou YH, Zhuang HX, Wang SJ, et al. Satisfactory surgical option for congenital microtia with defects of external auditory meatus (EAM) and middle ear. *Acta Otolaryngol* 2007;127:705-10.
- Hassepass F, Bulla S, Aschendorff A, et al. The bonebridge as a transcutaneous bone conduction hearing system: preliminary surgical and audiological results in children and adolescents. *Eur Arch Otorhinolaryngol* 2015;272:2235-41.
- Yeakley JW, Jahrsdoerfer RA. CT evaluation of congenital aural atresia: what the radiologist and surgeon need to know. *J Comput Assist Tomogr* 1996;20:724-31.